

V.M. Dudnyk, I.I. Andrikevych, N.I. Sinchuk, V.Yu. Pasik, O.V. Bereznitskiy

Features of sexual development in newborns: variants of the norm and deviation

National Pirogov Memorial Medical University, Vinnytsia, Ukraine

Modern Pediatrics. Ukraine. (2025). 1(145): 94-100; doi 10.15574/SP.2025.1(145).94100

For citation: Dudnyk VM, Andrikevych II, Sinchuk NI, Pasik VYu, Bereznitskiy OV. (2025). Features of sexual development in newborns: variants of the norm and deviation. Modern Pediatrics. Ukraine. 1(145): 94-100. doi: 10.15574/SP.2025.1(145).94100.

The identification of the person's biological sex based on various anatomical, physiological, and genetic markers that distinguish men from women, includes genetic, gonadal, and phenotypic sex types.

Aim: to analyze modern data on the definition, diagnosis, and management of patients with disorders of sexual differentiation (DSD) and to present a clinical case of a child at the stage of diagnostic verification.

This categorization process, known as sexual differentiation, is driven by genetic and hormonal factors during prenatal development. Disruptions in this intricate process can lead to DSD, complex conditions characterized by discrepancies between an individual's genetic, gonadal, and phenotypic features. Children with these disorders often face significant challenges in identifying their sex due to atypical and ambiguous external genital features. Such atypical presentations underscore the need for a comprehensive approach to diagnosis and management. Determining the appropriate legal sex of a child affected by these disorders necessitates thorough examinations, including genetic testing. Recent scientific advances have highlighted the pivotal role of histological and karyotypic analyses in classifying and managing DSD, further emphasizing the need for early and accurate diagnosis to facilitate the successful integration of affected individuals into society. An interdisciplinary approach is an integral part of supporting a child with a DSD, where the joint efforts of doctors, psychologists, teachers, and other specialists contribute to creating inclusive and safe conditions for the development of each individual.

No conflict of interests was declared by the authors.

Keywords: newborn, disorders of sexual differentiation, sex, sexual development, karyotype.

Особливості статевого розвитку новонароджених: варіанти норми та відхилень

В.М. Дудник, І.І. Андрікевич, Н.І. Сінчук, В.Ю. Пасік, О.В. Березницький

Вінницький національний медичний університет імені М.І. Пирогова, Україна

Визначення біологічної статі людини на основі різних анатомічних, фізіологічних і генетичних маркерів, які відрізняють чоловіків від жінок, охоплює генетичний, гонадний і фенотиповий типи статі.

Мета: проаналізувати сучасні дані щодо визначення, діагностики та ведення хворих на порушення статевої диференціації (ПСД) та представити клінічний випадок дитини на етапі діагностичної верифікації.

Процес класифікації, відомий як статеві диференціація, обумовлений генетичними та гормональними факторами під час внутрішньоутробного розвитку. Порушення цього складного процесу можуть призводити до ПСД – складних станів, що характеризуються невідповідністю між генетичними, гонадними та фенотиповими ознаками індивіда. Діти з такими розладами часто стикаються зі значними труднощами в ідентифікації статі через атипові та неоднозначні ознаки зовнішніх статевих органів. Такі нетипові прояви підкреслюють необхідність комплексного підходу до діагностики та ведення пацієнтів. Визначення відповідної юридичної статі дитини, яка має такі розлади, потребує ретельного обстеження, включно з генетичним тестуванням. В останніх наукових досягненнях було акцентовано увагу на ключовій ролі гістологічного аналізу та визначенні каріотипу у класифікації та веденні пацієнтів із ПСД, підкреслюючи необхідність ранньої та точної діагностики для успішної соціальної інтеграції таких осіб. Міждисциплінарний підхід є невід'ємною складовою підтримки дитини з ПСД, де спільні зусилля лікарів, психологів, педагогів та інших спеціалістів сприяють створенню інклюзивних і безпечних умов для розвитку кожної особи.

Автори не заявляють про конфлікт інтересів.

Ключові слова: новонароджений, порушення статевої диференціації, стать, статевий розвиток, каріотип.

The formation of typical male or female external genitalia is a complex process involving a cascade of genetic and physiological events that begin with sex determination and progress through the differentiation of internal and external reproductive structures. When this process is disrupted and does not occur typically, it is referred to as a difference or disorders of sexual differentiation (DSD).

The aim of the study: to analyze modern data on the definition, diagnosis, and management of patients with DSD and to present a clinical case of a child at the stage of diagnostic verification.

The development and differentiation of human sex involve a complex interplay of anatomical, physiological, and genetic factors that distinguish males from females. These factors operate individually and collectively, providing a multifaceted framework for identifying and distinguishing between the sexes. Human biological sex is not only a biological construct but also encompasses sociocultural and personal dimensions, including the concepts of gender roles and identity [5]. Sex differentiation begins with genetic sex, which is determined by the chromosomal constitution of the sperm, carrying either an X or Y chromosome, and is established at conception. Gonadal de-

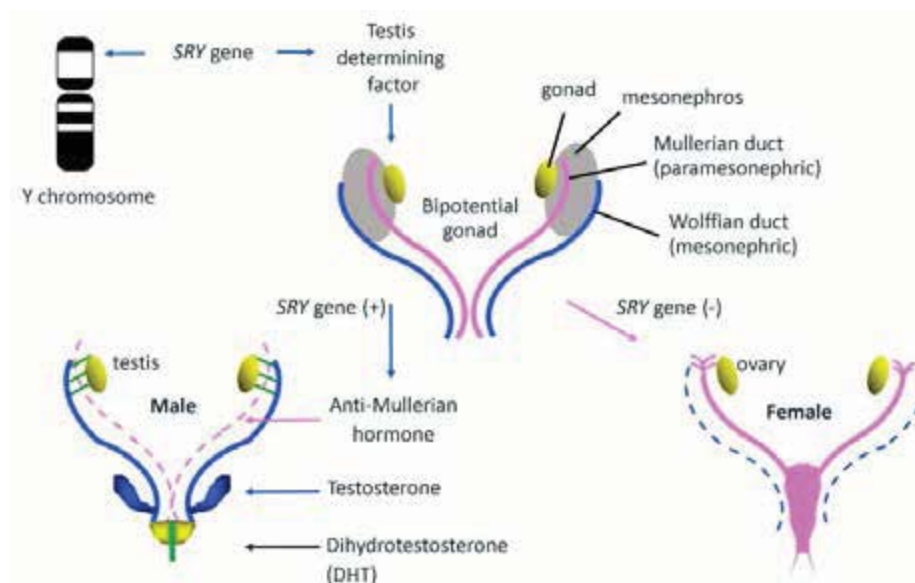


Fig. 1. Typical male and female sex determination and differentiation occur during fetal life [6]

velopment begins around the seventh week of intrauterine life in males and slightly later in females, and is influenced by specific genetic and hormonal factors [11]. Hormonal sex is dictated by the type of gonads and the range of hormones they produce. Phenotypic sex, observable by the twentieth week of gestation, is influenced by sex hormones and becomes evident through the structure of the external genitalia and secondary sexual characteristics at puberty.

Psychological sex, shaped by the hormonal environment during fetal development, is generally established by two to three years of age, affecting both higher and subcortical centers of the central nervous system [2]. Civil sex is assigned at birth, based on the appearance of external genitalia, which can be complex in cases of DSD. Social sex, defining gender-role behavior, evolves through various social interactions, particularly during puberty.

Typical male and female development commences with the presence of the typical 46, XY, or 46, XX chromosomes, which play a pivotal role in determining the indifferent gonads. Around the 6th week of gestation, these gonads follow pathways to develop into male-typical or female-typical gonads. This gonadal determination is intricately regulated by a complex interplay of multiple genes, which guide the male gonads to become testes and the female gonads to become ovaries. Subsequently, the gonads initiate the production of various hormones, including anti-Müllerian hormone (AMH) and testosterone. These hormones are responsible for driving the differentiation of the embryologic Wolffian and Müllerian

structures into sex-typical internal reproductive organs (Figure 1).

In Ukraine, a classification recognized by the world medical community is used to verify DSD (Table 1). DSD encompass a wide variety of conditions, each associated with distinct genetic, hormonal, or anatomical discrepancies. Among these, Congenital Adrenal Hyperplasia (CAH) is the most common, representing approximately 95% of all cases of DSD due to enzyme deficiencies affecting steroid hormone synthesis. CAH primarily results from 21-hydroxylase deficiency and affects about 1 in 13,000 to 15,000 newborns globally [9].

Other less common forms of DSD include Androgen Insensitivity Syndrome (AIS), which occurs in approximately 1 in 20,000 to 1 in 99,000 live births, depending on the severity of the condition. Ovotesticular DSD, where individuals have both ovarian and testicular tissue, is much rarer, with an estimated occurrence of about 1 in 20,000 to 1 in 83,000 births [12].

Klinefelter syndrome, involving the presence of one or more extra X chromosomes in males, typically occurs in about 1 in 500 to 1 in 1,000 newborn males. This condition contrasts with Turner syndrome, which affects approximately 1 in 2,500 live female births and often involves a single X chromosome [4].

The registry of children with DSD was initiated in Ukraine in 2000. Criteria for inclusion in the registry include improper or undefined structure of external genital organs and/or a mismatch between gonadal and chromosomal sex. Children with DSD underwent detailed cytogenetic examination. The database con-

Table 1

DSD Classification according to the Chicago consensus [6]

Sex Chromosome DSD	46,XY DSD	46,XX DSD
45,X0 (Turner syndrome and variants)	Disorders of gonadal (testicular) development: Complete gonadal dysgenesis (Swyer syndrome) or partial gonadal dysgenesis (e.g., <i>SRY</i> , <i>SOX9</i> , <i>NR5A1</i> , <i>WT1</i> , <i>DHH</i> gene mutations etc) Testicular regression (e.g., <i>DHX37</i> gene mutation) Ovotesticular DSD	Disorder of gonadal (ovarian) development: Ovotesticular DSD Testicular DSD (<i>SRY</i> (+)) Gonadal dysgenesis
47,XXY (Klinefelter syndrome and variants)	Disorders of testicular hormone production or action: Impaired testosterone production LH receptor mutations CAH (3 β HSD2 deficiency, 17OHD, POR, StAR, CYP11A1 deficiency) HSD17B3 deficiency Impaired testosterone action 5 α -reductase deficiency Androgen insensitivity syndrome (Complete/partial) Impaired AMH production or action Persistent Mullerian Duct Syndrome (<i>AMH</i> and <i>AMHR2</i> gene mutations)	Androgen excess Fetal CAH (21-hydroxylase, 11 β -hydroxylase, 3 β HSD2 deficiency) Glucocorticoid resistance Feto-placental Aromatase deficiency POR deficiency Maternal Luteoma, hilar cell tumors, arrhenoblastoma, lipoid cell tumors, Krukenberg tumors, androgen producing adrenal tumors, External androgen exposure
45,X0/46,XY (Mixed gonadal dysgenesis, ovotesticular DSD)	Other Syndromic Smith–Lemli–Opitz, Cloacal anomaly, Aarskog, Robinow, Meckel, Joubert, Hand–Foot–Genital, popliteal pterygium, CHARGE, VATER/VACTERL, IMAGe etc. Drugs Flutamide, ketoconazole, progestogens Endocrine disruptors Phthalate, BPA, paraben Cryptorchidism <i>INSL3</i> , <i>GREAT</i> gene mutations etc. Isolated hypospadias <i>MAMLD1</i> , <i>HOXA4</i> gene mutations etc.	Other Syndromic Cloacal anomaly etc. Mullerian anomalies Mayer–Rokitanski–Küster–Hauser, MURCS, McKusick–Kaufmann syndrome and variants, MODY5
46,XX/46,XY (chimeric, ovotesticular DSD)	-	-

Notes: StAR – Steroidogenic Acute Regulatory Protein defect; CYP11A1 – P450 side-chain cleavage deficiency; 3 β HSD2 – 3 β -hydroxy steroid dehydrogenase type 2 deficiency; CYP17A1 – 17 α -hydroxylase/17,20-lyase deficiency (17OHD); POR – P450 oxidoreductase deficiency; HSD17B3 – 17 β -hydroxysteroid dehydrogenase or 17-ketosteroid reductase deficiency; SFI/NR5A1 – Steroidogenic Factor 1 deficiency.

tains information on 682 patients, including those with chromosomal DSD – 357 (52.3%) children, among them 303 patients with Turner syndrome with 46 XY DSD – 119 (17.5%), with 46 XX – 206 (30.2%), among them 185 children with DSD due to congenital adrenal hyperplasia. Each of these conditions has a wide spectrum of presentation from subtle hormone imbalances to more pronounced phenotypic discrepancies presenting unique management challenges. This diversity underscores the necessity for tailored diagnostic and therapeutic strategies to optimize health outcomes for affected individuals.

DSD represents one of the most intricate phenomena within human development, attributed to a variety of genetic, biological, and environmental factors that disrupt the normal development of sexual organs and gender identity. One of the researches indicates that between 0.05% and 1.7% of the population exhibit features characteristic of DSD, necessitating a nuanced understanding and specialized care strategies [8].

Optimal care for infants and adolescents with DSD requires an experienced multidisciplinary team (MDT)

that is accessible through regional centers or clinical networks that link between one or more specialist centers. It is clear that many centers that deliver care in DSD do not have access to the whole range of expertise that may be required. As a minimum standard, the clinical team for children should include specialists in pediatric endocrinology, pediatric urology, pediatric clinical psychology, pediatric radiology, pediatric nursing, and, in the case of newborn infants, neonatology and, in the case of the older child, an adolescent gynecologist. All patients should also have a named keyworker which could be the nurse specialist in the team, but the family and young person should also be able to directly contact the lead clinician. In addition, the core MDT should have links to a wider MDT which includes specialists from clinical genetics, clinical biochemistry, adult endocrinology, adult urology, assisted conception, plastic surgery, gynecology, adult clinical psychology, psychiatry, social services, sex therapy and if possible a clinical ethics forum.

The clinical members of the MDT and their potential roles in providing care to the patient and the parents (Tables 2–4).

Table 2

The clinical members of the MDT and their potential roles [1]

The clinical members of the MDT	Role
Neonatologist or General Pediatrician	<ul style="list-style-type: none"> - Initial explanation (Table 3, 4) - Management of the unwell child - Initiation of first-line investigations - Seek advice from a pediatric subspecialist (endocrine or surgical) with an interest in DSD
Pediatric Endocrinologist	<ul style="list-style-type: none"> - Detailed explanation over multiple visits - Management of the unwell child - Interpreting first-line investigations and planning second-line investigations - Organize timely and appropriate involvement of other members of MDT - Act as the link between the parents and MDT - Initiate and monitor long-term medical therapy such as steroid or sex steroid therapy
Pediatric Radiologist	<ul style="list-style-type: none"> - Interpret and often perform ultrasound scans in the newborn - Judge the reliability of ultrasound scans in the newborn when the results may influence sex assignment
Pediatric Urologist	<ul style="list-style-type: none"> - Assessment of external anatomy - Explanation of the anatomy and results of imaging - Explanation of pros and cons of surgery - Develop a plan for complex imaging (other than pelvic ultrasound) and further assessment of the anatomy - Perform procedures such as laparoscopy, biopsy, reconstructive surgery and gonadectomy - Organize timely and appropriate involvement of other members of MDT
Pediatric Nurse Specialist	<ul style="list-style-type: none"> - Provide general support to the patient and parents in addition to that provided by other members of the MDT - Arrange specialist investigations - Liaise with the rest of the DSD team, including the clinical psychologist
Clinical Psychologist	<ul style="list-style-type: none"> - Provide specialist support to parents soon after birth - Provide support to the child growing up and the parents - Develop an individualized plan for each family - Guide the MDT on timing and tempo of explanation of the condition to the older child and adolescent
Clinical Endocrine Biochemist	<ul style="list-style-type: none"> - Facilitate timely analysis of samples - Provide specialist support and interpretation of results - Guide subsequent biochemical tests - Facilitate storage of samples for analysis at a later stage
Clinical Geneticist	<ul style="list-style-type: none"> - Facilitate timely analysis of chromosome analysis - Closer involvement in the child with dysmorphic features - Oversee the process of genetic analysis - Facilitate storage of samples for analysis at a later stage - Genetic counseling
Gynecologist	<ul style="list-style-type: none"> - Availability at an early stage to discuss future outcome and map long-term care pathway in the affected girl - Discuss issues related to sexual function, reproductive function, and surgery - Assess the understanding, review the diagnosis - Assess the need for psychological support in the adolescent girl - Initiate and monitor long-term sex steroid therapy - Perform examination, investigative, and therapeutic procedures in the adolescent girl - Oversee vaginal dilator training with a nurse specialist
Adult Endocrinologist	<ul style="list-style-type: none"> - Investigate and manage the adolescent presenting for the first time after the age of 16 - Liaise with other members of the MDT - Act as the link between the patient and MDT - Initiate and monitor long-term medical therapy such as steroid or sex steroid therapy - Act as the transition link for adolescents under pediatric care
Service Coordinator	<ul style="list-style-type: none"> - Oversee the coordination of a complex clinical service - Responsible for data management - Oversee activities related to audit and benchmarking of services - Oversee the public and professional engagement of the service

An important criterion for assessing the condition of a patient with DSD is the determination of bone age. Based on the development of the skeleton, it is possible not only to establish somatic age but also to predict the

onset of puberty. If the bone age lags behind the calendar, then puberty is delayed, if it is ahead of the calendar, then puberty comes earlier. The appearance of the sesamoid bone of the thumb coincides with the onset

Table 3

Tanner Stage (girls) [3]

Tanner Stage	Breasts	Pubic Hair	Growth	Other
1	Elevation of papilla only	Vellus hair only	2–2.4 inches per year	Adrenarche and ovarian growth
2	Breast bud under the areola, areola enlargement	Sparse hair along the labia	2.8-3.2 inches per year	Clitoral enlargement, labia pigmentation, growth of uterus
3	Breast tissue grows but has no contour or separation	Coarser hair curled pigmented covers the pubes	3.2 inches per year	Axillary hair, acne
4	Projection of areola and papilla, secondary mound formation	Adult hair, does not spread to the thigh	2.8 inches per year	Menarche and development of menses
5	Adult-type contour, projection of papilla only	Adult hair, spreads to the medial thigh	Cessation of linear growth	Adult genitalia

Table 4

Tanner Stage (boys) [3]

Tanner Stage	Genitalia	Pubic Hair	Growth	Other
1	Testes <2.5 cm	Vellus hair only	2.0-2.4 inches per year	Adrenarche
2	Testes 2.5-3.2 cm Thinning and reddening of the scrotum	Sparse hair at penis base	2.0-2.4 inches per year	Decreases in body fat
3	Testes 3.3-4.0 cm increase of penis length	Thicker curly hair spreads to the pubis	2.8 3.2 inches per year	Gynecomastia, voice break, muscle mass
4	Testes 4.1 4.5 cm, penis growth darkening of scrotum	Adult hair does not spread to thighs	4.0 inches per year	Axillary hair, voice change, acne
5	Testes >4.5cm, adult genitalia	Adult hair spreads to medial thigh	Deceleration, cessation	Facial hair, muscle mass increases

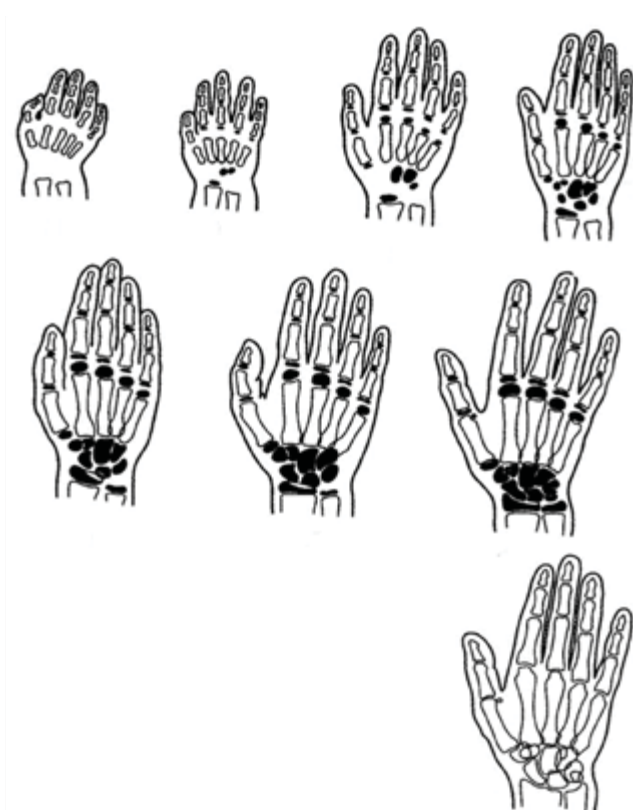


Fig. 2. Determination of bone age in children. Scheme of the development of the skeleton of the hand from birth to puberty

of puberty. Given the general trend of acceleration, it is now observed at an earlier age than before: in girls at about 10.5 years, and in boys at 13 years (Figure 2).

Clinical case

A child was born from the second pregnancy at 41 weeks with 3700 g body weight, body length of 54 cm, and Apgar score of 7–8 points. The first trimester of pregnancy had an acute respiratory viral infection, anemia, and asymptomatic bacteriuria. Childbirth – without special features, naturally.

Phenotypically, no stigmas of dysembryogenesis were detected on the face and trunk. When examining the reproductive system, the newborn was found to have an abnormal structure of the external genitalia: a hypertrophied clitoris resembling an underdeveloped penis (Figure 3). The degree of virilization 2–3.

Therefore, it was not possible to determine the gender of the child at the stage of the maternity hospital. To clarify the diagnosis, the child was transferred to the neonatal pathology department, where a multidisciplinary team worked with the child: geneticist, endocrinologist, and urologist.

An ultrasound examination of the pelvic organs and external genitalia visualized a penis with two

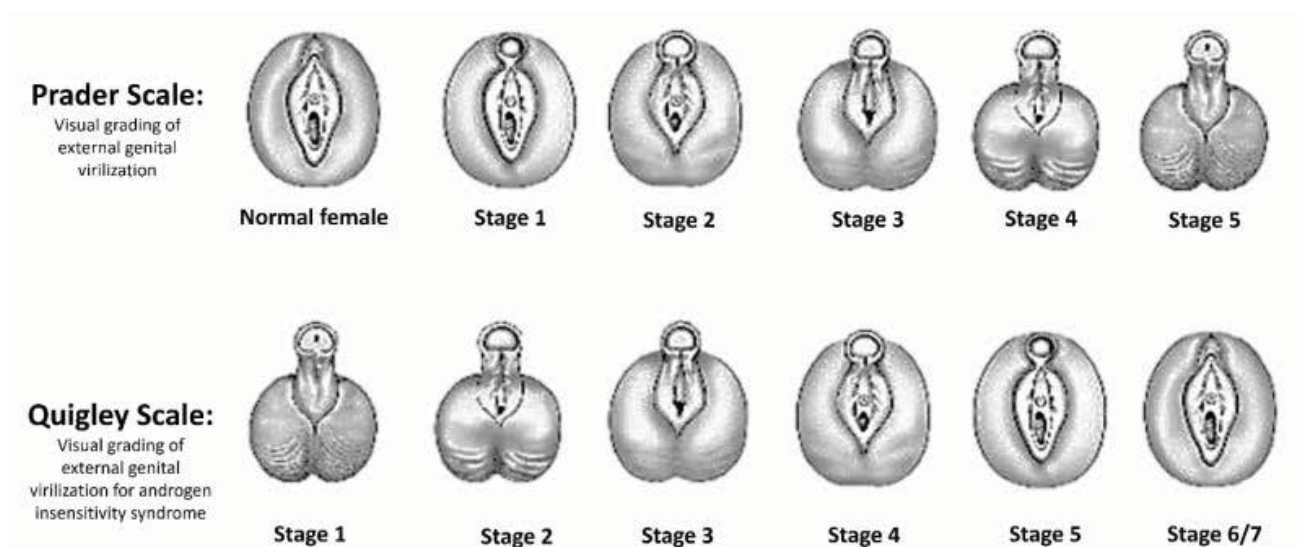


Fig. 3. Prader and Quigley Scales for visual grading of external genital virilization [6]

cavernous bodies; the uterus was not visualized, and testicles were not identified in the groin areas.

Karyotype 47,XXY[10]/46,XX [10]. The child was referred for further examination and determination of their sex.

Complete blood count: leukocytes – $9.7 \times 10^9/L$, erythrocytes – $3.9 \times 10^{12}/L$, hemoglobin – 110 g/L, platelets – $483 \times 10^9/L$, eosinophils – 8%, band neutrophils – 1%, segmented neutrophils – 10%, lymphocytes – 75%, monocytes – 6%, ESR – 12 mm/hr.

Complete urine analysis: specific gravity – 1015, sugar – none, protein – traces, leukocytes – 2–5 in field of view.

Biochemical blood test: total protein – 65 g/L, bilirubin – 11.2 $\mu\text{mol}/L$, alanine aminotransferase – 23 IU/L, aspartate aminotransferase – 34 IU/L, cholesterol – 5.6 mmol/L, low-density lipoproteins – 3.51 mmol/L, high-density lipoproteins – 1.33 mmol/L, triglycerides – 1.41 mmol/L.

Creatinine – 24 $\mu\text{mol}/L$, urea – 2.3 mmol/L. Potassium – 6.1 mmol/L, sodium – 138 mmol/L, ionized calcium – 1.34 mmol/L, total calcium – 2.77 mmol/L, phosphorus – 2.29 mmol/L.

Luteinizing hormone – 7.69 mIU/mL (normal – 0.02–7.0). Such pituitary hormones are typical for mini-puberty – at 2–3 months of life, thus it's normal.

Follicle-stimulating hormone – 6.19 mIU/mL (normal – 0.19–11.3).

Testosterone – 0.721 ng/mL (normal: boys – 0.01–1.77, girls – 0.01–0.05).

Estradiol – <5 pg/mL.

Dehydroepiandrosterone sulfate – 1.76 $\mu\text{mol}/L$ (normal – 0.09–3.35).

17-hydroxyprogesterone – 8.88 ng/mL (normal – 1.88–9.7).

Anti-Müllerian hormone – 30 ng/mL (normal <60 days – 0.01–3.39).

Inhibin B – 102 pg/mL (normal – 2.6–73.0).

A three-day test with chorionic gonadotropin:

after the test, testosterone – 2.59 ng/mL, estradiol – <5 pg/mL.

Thyroid-stimulating hormone – 4.91 mIU/mL (normal – 0.7–11.0).

Free thyroxine – 1.52 ng/dL (normal – 0.8–2.2).

No conflict of interest. Joint author participation.

Antibodies to thyroid peroxidase – 22.72 mIU/mL (normal – <47).

Pelvic ultrasound: the uterine body is deviated to the right, body length – 15 mm, cervix length – 14 mm, width – 9 mm, anteroposterior size – 7 mm, M echo+/- . In the projection of the vagina, fluid (content – 3.5 mm). Right gonad in the inguinal canal measuring 8×4×7 mm, left gonad – not visualized reliably in the inguinal canal and abdominal cavity.

Repeated karyotyping was conducted at the age of 3 months using the differential chromosome staining method (GTG-banding), fluorescent in situ hybridization (FISH): mos47,XXY[14]/46,XX[16]. ishX(DXZ1x2),Y(SRY,DXZ1)x1[14]/X(DXZ1x2)[49].

Conclusion: mosaic karyotype, represented by two cell lines: in 14 of 30 analyzed cells (46%) karyotype XXY, in the rest of the analyzed cells – normal female karyotype. The ratio of cell lines was confirmed by the FISH method.

Based on the research results, the clinical diagnosis was established: Disorders of Sexual Differentia-

tion, karyotype mos47,XXY[14]/46,XX[16]. ishX(DXZ1x2),Y(SRY,DXZ1)x1[14]/X(DXZ1x2) [49].

Ovotesticular disorder of sex.

15–30% of individuals with ovotesticular DSD possess the SRY gene; however, the majority (~70%) have a 46,XX karyotype and develop seminiferous tubules despite the absence of SRY, indicating the activation of this gene. Various forms of mosaicism are also common (15–20%) [7]. Overall, the following DSD karyotypes are observed: 46,XX / 46,XY, 46,XX / 47,XXY, or XX-XY with SRY mutations, mixed chromosomal abnormalities, or hormonal disturbances, as well as 47,XXY and different degrees of mosaicism. The three primary karyotypes of ovotesticular DSD include: XX with genetic abnormalities (55–70% of cases), XX/XY mosaicism (20–30% of cases), XY karyotype (5–15% of cases) [10].

Conclusions

During the initial examination of the newborn, sexual development should be assessed with the identification of male or female sex. When a DSD is de-

tected, the diagnosis must be verified according to the established algorithm for children with an indeterminate gender. DSD in children represent significant clinical, psychological, and social problems, therefore, the determination of the sex of the child should be carried out as soon as possible. The presented clinical case demonstrates the complexity of verifying the diagnosis of DSD and highlights the necessity of following a clear diagnostic algorithm. This algorithm involved the work of a multidisciplinary team: at the neonatologist's initiative, the patient was examined by a geneticist and an endocrinologist, followed by karyotyping, hormonal, and functional studies. After obtaining the results, psychologists, legal experts, and social workers joined the team of specialists. Further gender socialization and registration of the child had no preference regarding the determination of a specific sex, therefore the matter regarding the registration of the child in a certain sex was left to the discretion of the parents with recommendations for further regular examination and medicinal and surgical correction according to the chosen sex.

No conflict of interests was declared by the authors.

REFERENCES/ЛІТЕРАТУРА

- Ahmed SF, Achermann J. etc. Society for Endocrinology UK Guidance on the initial evaluation of a suspected difference or disorder of sex development. 2021 Dec;95(6):818-840
- Bakker J. (2019). The Sexual Differentiation of the Human Brain: Role of Sex Hormones Versus Sex Chromosomes. Current topics in behavioral neurosciences. 43: 45-67. https://doi.org/10.1007/7854_2018_70.
- Breehl L, Caban O. (2025, Jan). Physiology, Puberty. [Updated 2023 Mar 27]. In: StatPearls [Internet]. Treasure Island (FL): StatPearls Publishing. URL: <https://www.ncbi.nlm.nih.gov/books/NBK534827/>.
- Butler G, Srirangalingam U, Faithfull J, Sangster P, Senniappan S, Mitchell R. (2023). Klinefelter syndrome: going beyond the diagnosis. Archives of disease in childhood. 108(3): 166-171. <https://doi.org/10.1136/archdischild-2020-320831>.
- Cools M, Nordenström A, Robeva R, Hall J, Westerveld P, Flück C et al. (2018). Caring for individuals with a difference of sex development (DSD): a Consensus Statement. Nature reviews. Endocrinology. 14(7): 415-429. <https://doi.org/10.1038/s41574-018-0010-8>.
- Flück CE, Güran T. (2000). Ambiguous Genitalia in the Newborn. Updated 2023 Nov 13. In: Feingold KR, Anawalt B, Blackman MR et al., editors. Endotext [Internet]. South Dartmouth (MA): MDText.com, Inc. URL: <https://www.ncbi.nlm.nih.gov/books/NBK279168/>.
- Kaduskar P, Suryanarayana KM, Babu P, Mysorekar V. 46 XX, SRY Negative Ovotesticular DSD. J Assoc Physicians India. 2018 Dec;66(12):84-85. PMID: 31315334.
- Marinus MA, Cense M. (2024). A Life Course Perspective on the Sexual Development of Young Intersex People. Healthcare (Basel, Switzerland). 12(2): 239. <https://doi.org/10.3390/healthcare12020239>.
- Merke DP, Auchus RJ. (2020). Congenital Adrenal Hyperplasia Due to 21-Hydroxylase Deficiency. The New England journal of medicine. 383(13): 1248-1261. <https://doi.org/10.1056/NEJMr1909786>.
- Ren Š, Harmaš V, Stará M, Laštůvková J, Čejnová V. Description of diagnosis of 45,X/46,XY ovotesticular DSD. Ceska Gynekol. 2020 Winter;85(4):259-262. English. PMID: 33562981.
- Schnebly RA. (2021, Jul 16). Sex Determination in Humans. Embryo Project Encyclopedia. ISSN: 1940-5030. URL: <https://hdl.handle.net/10776/13286>.
- Syryn H, Van De Vijver K, Cools M. (2023). Ovotesticular Difference of Sex Development: Genetic Background, Histological Features, and Clinical Management. Hormone research in paediatrics. 96(2): 180-189. <https://doi.org/10.1159/000519323>.

Відомості про авторів:

Дудник Вероніка Михайлівна – д.мед.н., проф., зав. каф. педіатрії №2 ВНМУ ім. М.І. Пирогова. Адреса: м. Вінниця, вул. Пирогова, 56. <https://orcid.org/0000-0003-2164-8204>.
Андрієвич Ірина Іванівна – к.мед.н., доц. каф. педіатрії №2 ВНМУ ім. М.І. Пирогова. Адреса: м. Вінниця, вул. Пирогова, 56. <https://orcid.org/0000-0002-4954-6800>.
Сінчук Наталія Іванівна – к.мед.н., доц. каф. педіатрії №2 ВНМУ ім. М.І. Пирогова. Адреса: м. Вінниця, вул. Пирогова, 56. <https://orcid.org/0000-0003-3062-0392>.
Пасік Валентина Юріївна – PhD, асистент каф. педіатрії №2 ВНМУ ім. М.І. Пирогова. Адреса: м. Вінниця, вул. Пирогова, 56. <https://orcid.org/0000-0003-4325-0715>.
Березницький Олександр Володимирович – асистент каф. педіатрії №2 ВНМУ ім. М.І. Пирогова. Адреса: м. Вінниця, вул. Пирогова, 56. <https://orcid.org/0009-0007-9474-3225>.
 Стаття надійшла до редакції 25.10.2024 р., прийнята до друку 11.02.2025 р.