




REPORTS OF MORPHOLOGY

*Official Journal of the Scientific Society of Anatomists,
Histologists, Embryologists and Topographic Anatomists
of Ukraine*

journal homepage: <https://morphology-journal.com>



Determination of cephalometric parameters according to the COGS method, which characterize the position of individual teeth relative to cranial structures depending on the types of faces in Ukrainian young men and young women with an orthognathic bite

Nesterenko Ye. A., Shinkaruk-Dykovytska M. M., Chugu T. V., Dudik O. P., Gunas V. I.

National Pirogov Memorial Medical University, Vinnytsya, Ukraine

ARTICLE INFO

Received: 26 May 2022

Accepted: 30 June 2022

UDC: 616.714.1-071.3(477)

CORRESPONDING AUTHOR

e-mail: tikhonova_123@ukr.net

Nesterenko Ye. A.

CONFLICT OF INTEREST

The authors have no conflicts of interest to declare.

FUNDING

Not applicable.

An aesthetically pleasing face is one of the main goals of orthodontic treatment. However, in the case of severe pathology, in order to achieve the harmony of the complex of soft and hard tissues of the face, it is necessary to carry out not only orthodontic but also surgical intervention, i.e. orthognathic surgery. A cephalometric analysis for orthognathic surgery (COGS) is an effective element necessary for planning such treatment. The purpose of the study is to establish the peculiarities of cephalometric parameters that characterize the position of individual teeth relative to cranial structures according to the COGS method in Ukrainian young men and young women with an orthognathic bite, depending on the type of face. 46 young men (aged 17 to 21) and 72 young women (aged 16 to 20) who belonged in three generations to residents of Ukraine of the Caucasian race and had an orthognathic bite, underwent cephalometry according to the COGS method. OnyxCeph³™ software, version 3DPro, Image Instruments GmbH, Germany, was used for cephalometric analysis of indicators characterizing the position of individual teeth relative to cranial structures. According to the value of Garson's morphological index, the type of face was determined. Statistical processing of the obtained results was carried out in the license package "Statistica 6.0" using non-parametric estimation methods. Between young women with different types of face, the following reliable or trends of differences in linear and angular indicators, which characterize the position of individual teeth relative to cranial structures according to the COGS method, were established: in young women with a very wide face type, smaller values of the distances 1u-NF, 1l-MP, 6u-NF and the OP-HP angle (compared to medium and narrow face types), as well as the 6l-MP distance (compared only to the medium face type); young women with an average face type have larger values of the 6l-MP distance (compared to narrow face types), as well as the OP-HP angle (compared to wide and narrow face types). Between young men with different types of faces, there are practically no reliable or trends of differences in linear and angular indicators that characterize the position of individual teeth relative to cranial structures according to the COGS method. Manifestations of sexual dimorphism of linear and angular indicators, which characterize the position of individual teeth relative to cranial structures according to the COGS method, have been established: in young men, the values of most linear dimensions are higher in representatives with very wide, wide and narrow face types; young women with different types of faces have larger values of the OP-HP angle. The obtained results will allow dentists to provide the necessary assistance to the patient at a modern level, taking into account not only the age, sex and ethnic characteristics of a person, but also the type of his face.

Keywords: cone-beam computed tomography, telerradiography, COGS cephalometry, cephalometry, teeth, young men, young women, orthognathic occlusion, facial types, sex differences.

Introduction

When it comes to maxillofacial pathology, which disrupts the functioning of not only the speech and chewing

apparatus, but also the aesthetic appearance of the face, it is important to carry out correct and consistent treatment.

First of all, in this case, an adequate solution is the use of all possible modern and proven means that can eliminate this pathology.

One of the topical issues that scientists are currently discussing in various publications is the grounds for using orthodontic treatment and orthognathic surgery - which of these methods should be used in which situations? Is it necessary to combine them? Should orthodontic treatment precede orthognathic surgery?

S. Eslami and others [8] tried to identify the most sensitive parameters that can be used as a criterion for choosing which method to use in class III bite pathology - orthognathic surgery or orthodontic treatment. The Holdaway H angle and the assessment of jaw disharmony according to Wits, as it turned out, are critical diagnostic parameters for determining the treatment method for this pathology.

In general, the most generalized assessment of the researchers at the moment allows us to identify both of these methods as powerful tools that strengthen each other when they are combined, especially considering the development of modern digital radiological research methods, which allow to increase the accuracy of treatment prediction and reduce the risk of complications [6, 16]. Performing orthognathic intervention before orthodontic treatment is one of the most modern views on the concept of treatment of dental and jaw pathologies [15].

If we take into account the economic efficiency of orthognathic surgery and orthodontic treatment, no significant difference was found between them ($p=0.979$) in terms of the time spent on treatment ($p=0.003$), the duration of the doctor's work ($p=0.015$), the cost ($p=0.924$) or quality of life index ($p=0.41$) [10].

Inadequate and inappropriate planning of orthodontic intervention, in turn, leads to adverse consequences, in particular, discrepancies in expectations and actual results of the treatment [14]. Errors of this kind are divided into 4 categories: complications associated with inadequate decompensation of teeth, complications associated with treatment planning, complications of postoperative orthodontic care, and complications associated with appliances [12]. Some conditions, such as temporomandibular joint pathology, are more common complications than others [25].

Significant improvements in the patient's quality of life and psycho-emotional state can be achieved in the shortest possible time after a successful orthognathic intervention. The data of Emadian Razvadi E. S. with co-authors [7] indicate that the quality of life of patients significantly increased in the period before the start of treatment and 4 months after its start ($p<0.013$).

However, it should not be forgotten that not all psychological aspects of life can be improved only through orthognathic treatment. Operative intervention first of all eliminates the disturbance of social activity, which was disturbed due to dental and jaw pathology [20].

Thus, the orthognathic method of treatment of maxillofacial pathology occupies a key place in the treatment process of the patient, and affects a number of aspects of his life. One of the elements of this method that requires attention from scientists is the study of cephalometry for orthognathic surgery (COGS). This powerful anthropometric mechanism, created to increase the effectiveness of treatment planning, is quite sensitive to such variables as sex, age, nationality, face type, etc. In turn, this requires conducting clinical studies on the local population, taking into account as many of these variables as possible.

The purpose of the study is to establish the peculiarities of cephalometric parameters that characterize the position of individual teeth relative to cranial structures according to the COGS method in Ukrainian young men and young women with an orthognathic bite, depending on the type of face.

Materials and methods

A cephalometric study of lateral teleroentgenograms obtained with the dental cone-beam tomograph Veraviewepocs 3D Morita was carried out in 46 young men (YM) (aged 17 to 21 years) and 72 young women (YW) (aged 16 to 20 years) taken from the database of the research center and Department of Pediatric Dentistry, National Pirogov Memorial Medical University, Vinnytsya. All young men and young women applied to the private dental clinic "Vinintermed" for a diagnostic examination, belonged in three generations to residents of Ukraine of the Caucasian race and had a physiological bite that was as close as possible to an orthognathic bite (hereinafter referred to as an orthognathic bite). Committee on Bioethics of National Pirogov Memorial Medical University, Vinnytsya (protocol № 8 From 30.09.2021) found that the studies do not contradict the basic bioethical standards of the Declaration of Helsinki, the Council of Europe Convention on Human Rights and Biomedicine (1977), the relevant WHO regulations and laws of Ukraine.

According to the COGS method [1], the OnyxCeph^{3TM} software, version 3DPro, of Image Instruments GmbH, Germany, was used for cephalometric analysis (software license №URSQ-1799 registered to Dmitriev M. O.).

According to the value of Garson's morphological index [19], the face type of YM and YW with an orthognathic bite was determined.

For the convenience of clinical use of a large array of metric characteristics used in the COGS method, we used the distribution of teleradiographic indicators proposed by Dmitriev M. O. [3, 4, 5], according to which the third group includes indicators that actually characterize the position of individual teeth relative to each other and cranial structures. It is this group of indicators that is most often corrected in the process of orthodontic treatment of dento-jaw anomalies.

The main cephalometric points and measurements

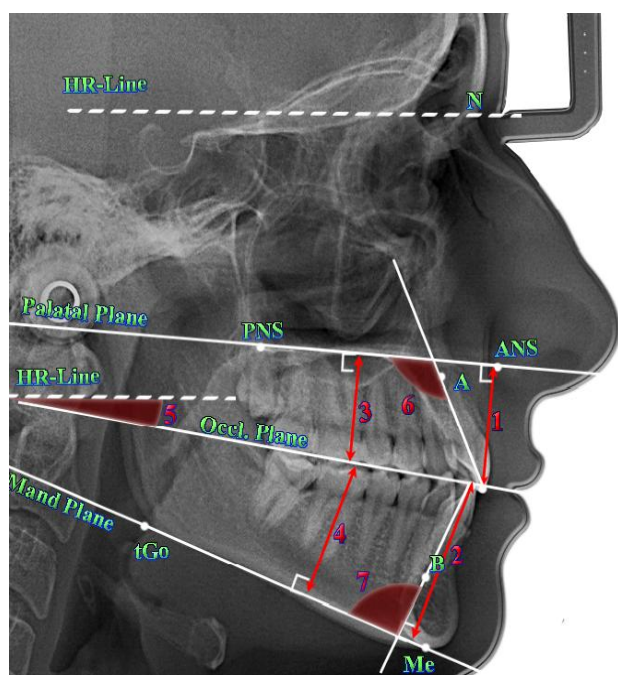


Fig. 1. The main cephalometric points and COGS measurements included in the third group of indicators: 1 - distance **1u-NF**; 2 - distance **1l-MP**; 3 - distance **6u-NF**; 4 - distance **6l-MP**; 5 - angle **OP-HP**; 6 - angle **Max1-NF**; 7 - angle **Mand1-MP**.

characterizing the position of individual teeth relative to cranial structures (included in the third group of indicators) are presented in Figure 1:

distance **1u-NF** (distance of incisal edge of 1u to palatal plane) - characterizes the position of the upper middle incisor relative to the palatal plane; determined by the length of the perpendicular to the line **ANS-PNS**, drawn from the point **Is1u** (mm);

distance **1l-MP** (distance of incisal edge of 1l to mand. plane) - characterizes the position of the lower middle incisor relative to the mandibular plane; determined by the length of the perpendicular to the line **tGo-Me**, omitted from the point **Is1L** (mm);

distance **6u-NF** (distance of mesial cusp of 6u to palatal plane) - characterizes the position of the first molar relative to the palatal plane; determined by the length of the perpendicular to the line **ANS-PNS**, drawn from the point **6u** (mm);

distance **6l-MP** (distance of mesial cusp of 6l to mand. plane) - characterizes the position of the lower first molar relative to the mandibular plane; determined by the length of the perpendicular to the line **tGo-Me**, omitted from the point **6L** (mm);

angle **OP-HP** (angle of occl. to horizontal plane) - the angle formed by the lines **apOcP-ppOcP** та **HR-Line** (°);

angle **Max1-NF** (angle of axis of 1u to palatal plane) - the angle formed by the lines **Ap1u-Is1u** та **ANS-PNS** (°);

angle **Mand1-MP** (angle of axis of 1l to mand. plane) - the angle formed by the lines **Is1L-Ap1L** та **tGo-Gn** (°).

The obtained results were statistically processed in the license package "Statistica 6.0" using non-parametric estimation methods. Mean values and standard deviation were determined for each characteristic. The significance of the difference in values between independent quantitative values was determined using the Mann-Whitney U-test.

Results

Tables 1 and 2 present the results of the value of linear and angular indicators, which characterize the position of individual teeth relative to cranial structures according to the COGS method in YM or YW with an orthognathic bite, depending on the type of face.

We have established significantly greater or trends to greater values of the following indicators in YM or YW:

in YM - distance values of 1l-MP (with a very wide, $p < 0.05$, wide $p < 0.01$ and narrow face, $p = 0.064$), 6u-NF (with a wide face, $p < 0.01$), 6l-MP (with a very wide, $p < 0.01$, wide $p < 0.05$ and narrow face, $p < 0.05$), as well as the angle Mand1-MP (with a very wide face, $p = 0.071$);

in YW - the value of the angle OP-HP (with a very wide, $p = 0.075$, wide $p = 0.059$, medium, $p < 0.05$ and narrow face, $p = 0.064$).

Table 1. The value of linear and angular indicators that characterize the position of individual teeth relative to cranial structures according to the COGS method in YM with different types of faces ($M \pm \sigma$).

Indicator	Face type				P_{1-2}	P_{1-2}	P_{1-4}	P_{2-3}	P_{2-4}	P_{3-4}
	Very wide (1)	Wide (2)	Average (3)	Narrow (4)						
Distance 1u-NF	25.24 \pm 3.54	27.09 \pm 2.63	26.90 \pm 2.46	26.50 \pm 2.63	>0.05	>0.05	>0.05	>0.05	>0.05	>0.05
Distance 1l-MP	38.52 \pm 2.64	39.73 \pm 2.17	40.33 \pm 3.19	40.09 \pm 2.42	>0.05	>0.05	>0.05	>0.05	>0.05	>0.05
Distance 6u-NF	22.54 \pm 3.22	23.03 \pm 1.87	22.66 \pm 1.66	22.10 \pm 2.48	>0.05	>0.05	>0.05	>0.05	>0.05	>0.05
Distance 6l-MP	32.54 \pm 1.67	32.20 \pm 2.19	32.90 \pm 3.22	33.44 \pm 2.39	>0.05	>0.05	>0.05	>0.05	>0.05	>0.05
Angle OP-HP	0.760 \pm 5.819	5.259 \pm 5.445	7.409 \pm 3.856	4.825 \pm 4.720	>0.05	=0.062	>0.05	>0.05	>0.05	>0.05
Angle Max1-NF	113.4 \pm 8.0	112.2 \pm 6.3	109.3 \pm 5.0	109.1 \pm 2.6	>0.05	>0.05	>0.05	>0.05	>0.05	>0.05
Angle Mand1-MP	103.0 \pm 8.0	97.65 \pm 7.52	94.68 \pm 7.52	95.96 \pm 4.84	>0.05	=0.079	>0.05	>0.05	>0.05	>0.05

Notes: here and in the following table, $M \pm \sigma$ - average sample \pm standard deviation; $P_{(1-2, 1-3, 1-4, 2-3, 2-4, 3-4)}$ - validity of differences in linear or angular scores between YM or between YW with corresponding face types.

Table 2. The value of linear and angular indicators that characterize the position of individual teeth relative to cranial structures according to the COGS method in YW with different types of faces ($M \pm \sigma$).

Indicator	Face type				P_{1-2}	P_{1-2}	P_{1-4}	P_{2-3}	P_{2-4}	P_{3-4}
	Very wide (1)	Wide (2)	Average (3)	Narrow (4)						
Distance 1u-NF	24.62 \pm 2.21	26.48 \pm 2.16	27.63 \pm 2.56	25.99 \pm 1.76	>0.05	<0.05	=0.054	>0.05	>0.05	>0.05
Distance 1I-MP	35.65 \pm 1.75	37.60 \pm 2.37	38.86 \pm 3.20	37.98 \pm 1.78	>0.05	<0.01	<0.01	>0.05	>0.05	>0.05
Distance 6u-NF	20.25 \pm 1.44	21.48 \pm 1.78	21.89 \pm 1.84	21.48 \pm 1.36	>0.05	<0.05	<0.05	>0.05	>0.05	>0.05
Distance 6I-MP	28.94 \pm 1.96	30.49 \pm 2.24	31.67 \pm 2.39	30.15 \pm 1.98	>0.05	<0.01	>0.05	>0.05	>0.05	=0.070
Angle OP-HP	5.856 \pm 4.133	7.976 \pm 3.976	11.64 \pm 3.37	9.017 \pm 2.728	>0.05	<0.001	<0.05	<0.05	>0.05	=0.070
Angle Max1-NF	112.9 \pm 5.9	110.2 \pm 5.5	109.6 \pm 4.8	110.9 \pm 7.3	>0.05	>0.05	>0.05	>0.05	>0.05	>0.05
Angle Mand1-MP	95.60 \pm 8.51	96.77 \pm 5.38	93.67 \pm 5.70	93.46 \pm 6.04	>0.05	>0.05	>0.05	>0.05	>0.05	>0.05

Discussion

COGS analysis in a complex application with three-dimensional computer modeling is the most optimal way to obtain satisfactory functional and aesthetic results for both the doctor and the patient in the most complex types of bite pathology [2].

Comparison of cephalometric parameters according to COGS before and after anterior segmental osteotomy using statistical analysis revealed changes in the parameters of both soft and hard tissues in patients. The biggest changes were found in the protrusion of the upper lip and upper incisor [9].

Evaluation of changes in COGS indicators in soft tissues after single-jaw and double-jaw surgery in patients with Class III skeletal pathology found more significant changes in the upper lip in double-jaw surgery. At the same time, during interventions on one jaw, there is a positive correlation between hard and soft tissues of the lower jaw [17].

COGS analysis was used to analyze the effect of chin protrusion on normal facial profile. For this study, 60 people without previous orthodontic treatment were selected. Men and women with class II and class III facial profiles had statistically significant differences in B-Pg values [21].

According to the COGS analysis, cases with cleft palate and cleft lip are at high risk of Le Fort 1 fracture recurrence. Patient follow-up revealed mean linear horizontal advancement achieved along the nose (N) to the anterior nasal spine (ANS) relative to the true vertical plane at 15 months at the level of 5.17 mm, and at 12 months 3.91 mm [13].

As for the ethnic differences in the COGS analysis, the best example to show the diversity of results within even one country is India. Joshi S. with co-authors [11] studied the cephalograms of 100 people, ethnic residents of the state of Maharashtra. Compared to Caucasians norms, men from this state have a straighter profile, less vertical height and less mandibular divergence. At the same time, women have a convex profile, reduced vertical height and less divergence of the lower jaw.

At the same time, the population living in the more southern state of India, Kerala, according to the data analysis of the obtained indicators, compared to

Caucasians, have a longer length of the front and back of the skull base, protrusion of the lower jaw, lower front face height, front and back height teeth, inclined upper and lower incisors and a less noticeable chin [18].

The state of Karnataka is located in the middle between the states described in the studies above. G. M. Shashikumar and others [22], after examining the cephalograms of 100 ethnic residents of this state, found that compared to Caucasians, they have larger bulges (men), larger values of the throat angle, lower lip protrusion, and mentolabial furrow; at the same time, smaller values of the nasolabial angle were found.

The population of Northern India (all the previous states were southwestern) has significantly lower values of the proclination of the teeth of the upper and lower jaws, the angle of the occlusal plane, and higher values of the chin protrusion compared to Caucasians. In addition, the authors found pronounced manifestations of sexual dimorphism of most indicators [23, 24].

Between Ukrainian YM or YW with an orthognathic bite with different facial types, when comparing the linear and angular indicators that characterize the position of individual teeth relative to the cranial structures by the COGS method, almost all reliable or trends of discrepancies are established between the YW, namely:

YW with very wide face type have significantly smaller, or trends toward smaller values of 1u-NF, 1I-MP, 6u-NF distances and OP-HP angle (compared to medium and narrow face types), as well as 6I-MP distances (compared to only the average face type);

YW with a medium face type, significantly higher or trends towards greater values of the 6I-MP distance (compared to the narrow face type) and the OP-HP angle (compared to the wide and narrow face types).

Among YM with different face types, only the trends of differences in angle indicators between representatives with very wide and medium face types were established, namely: in young men with a medium face type, larger values of the OP-HP angle and smaller values of the Mand1-MP angle were established.

We also established the manifestations of sexual

dimorphism of linear and angular indicators that characterize the position of individual teeth relative to cranial structures according to the COGS method, namely, reliably greater or trends to greater values:

in YM with very wide, wide and narrow face types - distance values of 1l-MP and 6l-MP; in young men with a wide face type - 6u-NF distance values and in young men with a very wide face type - Mand1-MP angle values;

in YW with very wide, wide, medium and narrow types of face - the magnitude of the angle OP-HP.

The results obtained by us in Ukrainian YM and YW with an orthognathic bite on the characteristics of the magnitude of linear and angular indicators, which characterize the position of individual teeth relative to cranial structures according to the COGS method, will allow dentists to provide the necessary assistance to the patient at a modern level, taking into account the age, sex, ethnic characteristics of the person and the type of her face.

References

- [1] Burstone, C. J., James, R. B., Legan, H., Murphy, G. A., & Norton, L. A. (1979). Cephalometrics for orthognathic surgery. *J. Oral Surg.* 36, 269-277. PMID: 273073
- [2] Conley, R. S., & Edwards, S. P. (2019). Three-dimensional treatment planning for maxillary and mandibular segmental surgery for an adult Class III: Where old meets new. *The Angle Orthodontist*, 89(1), 138-148. doi: 10.2319/120117-823.1
- [3] Dmitriev, M. O. (2016). Кореляції основних краніальних показників з характеристиками верхньої та нижньої щелеп у мешканців України юнацького віку [Correlations of main cranial index with characteristics of upper and lower jaws among residents in Ukraine of adolescent age]. *Світ медицини та біології - World of Medicine and Biology*, 4(58), 24-29.
- [4] Dmitriev, M. O. (2017). Зв'язки кутових міжщелепних показників з характеристиками положення зубів та профілем м'яких тканин лица у мешканців України юнацького віку [Links of angular inter-jaws indices with the characteristics of the closure plane, the position of the teeth and the soft-tissue profile of the face in the youth of Ukraine]. *Світ медицини та біології - World of Medicine and Biology*, 2(60), 51-59.
- [5] Dmitriev, M. O. (2017). Зв'язки основних краніальних показників з характеристиками положення зубів верхньої і нижньої щелеп та профілем м'яких тканин лица у юнаків і дівчат [Relations of key cranial indicators with the characteristics of the teeth of the upper and lower jaws and profile face soft tissue in boys and girls]. *Вісник морфології - Reports of Morphology*, 23(1), 125-131.
- [6] Elnagar, M. H., Aronovich, S., & Kusnoto, B. (2020). Digital workflow for combined orthodontics and orthognathic surgery. *Oral and Maxillofacial Surgery Clinics*, 32(1), 1-14. doi: 10.1016/j.coms.2019.08.004
- [7] Emadian Razvadi, E. S., Soheilifar, S., Esmaeelinejad, M., & Naghdi, N. (2017). Evaluation of the changes in the quality of life in patients undergoing orthognathic surgery: a multicenter study. *Journal of Craniofacial Surgery*, 28(8), e739-e743. doi:10.1097/SCS.0000000000003887
- [8] Eslami, S., Faber, J., Fateh, A., Sheikholamemeh, F., Grassia, V., & Jamilian, A. (2018). Treatment decision in adult patients with class III malocclusion: surgery versus orthodontics. *Progress in orthodontics*, 19(1), 1-6. doi: 10.1186/s40510-018-0218-0
- [9] Harshitha, K. R., Srinath, N., Christopher, S., & Kumar, H. N. (2014). Evaluation of soft and hard tissue changes after anterior segmental osteotomy. *Journal of clinical and diagnostic research: JCDR*, 8(9), ZC07-ZC10. doi: 10.7860/JCDR/2014/9409.4791
- [10] Hu, J., Jiang, Y., Wang, D., Guo, S., Li, S., Jiang, H., & Cheng, J. (2021). Comparison of cost-effectiveness and benefits of surgery-first versus orthodontics-first orthognathic correction of skeletal class III malocclusion. *International Journal of Oral and Maxillofacial Surgery*, 50(3), 367-372. doi: 10.1016/j.ijom.2020.06.007
- [11] Joshi, S., Punamiya, S., Naik, C., Mhatre, B., Garad, A., & Chabalani, D. (2022). A study to evaluate cephalometric hard tissue profile of maharashtrian population for orthognathic surgery. *Indian Journal of Dental Sciences*, 14(2), 68-73. doi: 10.4103/IJDS.IJDS_60_21
- [12] Klein, K. P., Kaban, L. B., & Masoud, M. I. (2020). Orthognathic surgery and orthodontics: inadequate planning leading to complications or unfavorable results. *Oral and Maxillofacial Surgery Clinics*, 32(1), 71-82. doi: 10.1016/j.coms.2019.08.008
- [13] Kumari, P., Roy, S. K., Roy, I. D., Kumar, P., Datana, S., & Rahman, S. (2013). Stability of cleft maxilla in Le Fort I maxillary advancement. *Annals of Maxillofacial Surgery*, 3(2), 139-143. doi: 10.4103/2231-0746.119223
- [14] Moon, W., & Kim, J. (2016, March). Psychological considerations in orthognathic surgery and orthodontics. In *Seminars in Orthodontics* (Vol. 22, No. 1, pp. 12-17). WB Saunders. doi: 10.1053/j.sodo.2015.10.003
- [15] Naran, S., Steinbacher, D. M., & Taylor, J. A. (2018). Current concepts in orthognathic surgery. *Plastic and Reconstructive Surgery*, 141(6), 925e-936e. doi: 10.1097/PRS.0000000000004438
- [16] Ngan, P., & Moon, W. (2015). Evolution of Class III treatment in orthodontics. *American Journal of Orthodontics and Dentofacial Orthopedics*, 148(1), 22-36. doi: 10.1016/j.ajodo.2015.04.012
- [17] Parappallil, C. J., Parameswaran, R., Vijayalakshmi, D., & Mavelil, B. G. T. (2018). A comparative evaluation of changes in soft

Conclusion

1. Virtually all reliable or trends in the discrepancies of linear and angular indicators that characterize the position of individual teeth relative to cranial structures by the COGS method are established only between YW with orthognathic occlusion (between YW with very wide face type and medium and narrow face types, as well as between YW with medium face type and with wide and narrow face types).

2. Between YM and YW with an orthognathic bite and the corresponding facial types, manifestations of sexual dimorphism of indicators characterizing the position of individual teeth relative to cranial structures according to the COGS method were established: in YM, in most cases, larger values of linear dimensions were found in representatives with very wide, wide and narrow face types; in YW with different types of face - larger values of the angle OP-HP.

- tissues after single-jaw surgery and bimaxillary surgery in skeletal class III Patients. *Journal of Maxillofacial and Oral Surgery*, 17(4), 538-546. doi: 10.1007/s12663-017-1079-7
- [18] Patla, M., Achalli, S., Saidath, K., Soans, C. R., & Nayak, U. K. (2017). Cephalometric Norms for Orthognathic Surgery in Kerala Population. *Journal of Health and Allied Sciences NU*, 7(1), 45-51. doi: 10.1055/s-0040-1708695
- [19] Proffit, U. R., Fildz, G. U., & Saver, D. M. (2006). *Современная ортодонтия (перевод с английского Д. С. Персина) [Modern orthodontics (translation from English by D. S. Persina)]*. М.: МЕДпресс-информ - М.: MEDpress-inform.
- [20] Saghati, H., Benington, P., & Ayoub, A. (2020). Impact of orthognathic surgery on quality of life: a comparison between orthodontics-first and surgery-first approaches. *British Journal of Oral and Maxillofacial Surgery*, 58(3), 341-347. doi: 10.1016/j.bjoms.2020.01.005
- [21] Sainath, M. C., & Preeti, R. (2019). Quantitative Evaluation of Influence of Hard Tissue Chin Prominence on Perceived Normal Soft Tissue Facial Profile. *University Journal of Surgery and Surgical Specialities*, 5(9), 7-9.
- [22] Shashikumar, G. M., Naik, D. P., Savakkanavar, M. B., Sreedhara, S., & Reddy, S. R. K. (2015). Hard tissue cephalometric norms for orthognathic surgery in Karnataka population. *Journal of International Oral Health*, 7(11), 28-32.
- [23] Singh, G., Agrawal, A., Chaturvedi, T. P., & Naveen, K. P. (2019). A Computer Assisted Comparison of Cephalometric Norms between Caucasians and North Indian Population: An Analytical Study. *Sch Bull*, 5(4), 138-147. doi: 10.21276/sb.2019.5.4.2
- [24] Singh, S. P., Utreja, A. K., & Jena, A. K. (2013). Cephalometric norms for orthognathic surgery for North Indian population. *Contemporary clinical dentistry*, 4(4), 460-466. doi: 10.4103/0976-237X.123041
- [25] Wolford, L. M. (2020). Comprehensive post orthognathic surgery orthodontics: complications, misconceptions, and management. *Oral and Maxillofacial Surgery Clinics*, 32(1), 135-151. doi: 10.1016/j.coms.2019.09.003

ВИЗНАЧЕННЯ ЦЕФАЛОМЕТРИЧНИХ ПАРАМЕТРІВ ЗА МЕТОДОМ COGS, ЯКІ ХАРАКТЕРИЗУЮТЬ ПОЛОЖЕННЯ ОКРЕМИХ ЗУБІВ ВІДНОСНО ЧЕРЕПНИХ СТРУКТУР У ЗАЛЕЖНОСТІ ВІД ТИПІВ ОБЛИЧЧЯ В УКРАЇНСЬКИХ ЮНАКІВ І ДІВЧАТ ІЗ ОРТОГНАТИЧНИМ ПРИКУСОМ

Нестеренко Є. А., Шінкарук-Диковицька М. М., Чугу Т. В., Дудік О. П., Гунас В. І.

Естетично приємний вигляд обличчя є однією з головних цілей ортодонтичного лікування. Проте, у випадку тяжкої патології, для досягнення гармонійності комплексу м'яких та твердих тканин обличчя необхідно проводити не тільки ортодонтичне але і хірургічне втручання, тобто ортогнатичну хірургію. Ефективним елементом, необхідним для планування такого лікування є цефалометричний аналіз для ортогнатичної хірургії (COGS). Мета дослідження - встановити особливості цефалометричних параметрів, які характеризують положення окремих зубів відносно черепних структур за методом COGS, в українських юнаків і дівчат із ортогнатичним прикусом у залежності від типу обличчя. 46 юнакам (віком від 17 до 21 років) і 72 дівчатам (віком від 16 до 20 років), які належали у трьох колінах до мешканців України європейської раси та мали ортогнатичний прикус, проведено цефалометрію згідно COGS-методу. Для проведення цефалометричного аналізу показників, які характеризують положення окремих зубів відносно черепних структур, використовувалось програмне забезпечення *ОпукСерп³™*, версії 3DPro, компанії Image Instruments GmbH, Німеччина. Відповідно значенням морфологічного індексу Гарсона проводилося визначення типу обличчя. Статистичну обробку отриманих результатів проводили в ліцензійному пакеті "Statistica 6.0" з використанням непараметричних методів оцінки. Між дівчатами з різними типами обличчя встановлені наступні достовірні або тенденції відмінностей лінійних і кутових показників, які характеризують положення окремих зубів відносно черепних структур за методом COGS: у представниць із дуже широким типом обличчя - менші значення величини відстаней 1u-NF, 1l-MP, 6u-NF і кута OP-HP (порівняно з середнім і вузьким типами обличчя), а також відстані 6l-MP (порівняно лише з середнім типом обличчя); у представниць із середнім типом обличчя - більші значення величини відстані 6l-MP (порівняно з вузьким типом обличчя), а також кута OP-HP (порівняно з широким і вузьким типами обличчя). Між юнаками з різними типами обличчя практично не встановлені достовірні або тенденції відмінностей лінійних і кутових показників, які характеризують положення окремих зубів відносно черепних структур за методом COGS. Встановлені прояви статевого диморфізму лінійних і кутових показників, які характеризують положення окремих зубів відносно черепних структур за методом COGS: в юнаків - більші значення більшості лінійних розмірів у представників із дуже широким, широким і вузьким типами обличчя; у дівчат із різними типами обличчя - більші значення величини кута OP-HP. Отримані результати дозволять лікарям-стоматологам надавати необхідну пацієнту допомогу на сучасному рівні з урахуванням не тільки вікових, статевих та етнічних особливостей людини, але й типу її обличчя.

Ключові слова: конусно-променева комп'ютерна томографія, телерентенографія, цефалометрія за COGS-методом, кефалометрія, зуби, юнаки, дівчата, ортогнатичний прикус, типи обличчя, статеві розбіжності.