

V.I. Shevchuk , Y.O. Bezsmertnyi , Y. Jiang , H.V. Bezsmertna ,
Y.S. Sehedá , D.V. Bondarenko 

Scientific and Research Institute of Rehabilitation of National Pirogov Memorial Medical University, Vinnytsia, Ukraine

Influence of post-amputation pain syndrome on blood circulation in the bone residual limb

For citation: *Pain, joints, spine.* 2023;13(2):85-92. doi: 10.22141/pjs.13.2.2023.370

Abstract. Background. The percentage of unsatisfactory amputation results is still high. The healing of the bone remnant, the main supporting element of the residual limb, is of particular importance. **The purpose** was to study the effect of post-amputation pain syndrome on the nature of blood circulation in the bone residual limb. **Materials and methods.** Three series of experiments with amputation of the thigh were conducted on 54 rabbits. In the series 1 and 2, a perineural catheter was brought to the stump of the sciatic nerve. In series 1, for 20 days, every day for 20 minutes, mechanical irritation of the nerve was done, causing a pain syndrome using the perineural catheter. In series 2, 0.3 ml of 1% lidocaine was injected twice daily for 20 days; series 3 was a control. The follow-up periods were 1, 3, and 6 months. The study method was histological with the infusion of vessels with an ink-gelatin mixture. **Results.** Animals of the first series developed avascularity of the end of the stump and bone marrow, poor vascularity and absence of cellular composition in the Haversian canals, dystrophic changes in adipose bone marrow, rarefaction, spongiosis, resorption, and bone fractures. In series 2, the avascularity passed quickly and by three months, the angioarchitectonics was stabilized. Revascularization of the bone stump occurs due to the preserved sources of blood circulation (intramedullary vascular network, periosteum and surrounding soft tissues) anastomosing vessels and extravascular pathways of microcirculation (increased vascular permeability, formation of sinusoidal capillaries and tissue cysts). In most observations of series 3, the processes of revascularization were similar to the results of the 1st series. **Conclusions.** Postamputation pain syndrome causes abrupt macro- and microcirculatory disturbances. Pain syndrome suppression allows to considerably level the arising circulatory disorders in the bone residual limb.

Keywords: amputation; pain syndrome; bone stump; blood circulation; regeneration

Introduction

The formation of a residual limb that allows for adequate prosthetics is a complex problem. It is caused by difficulties in creating favorable conditions for the healing of all residual limb tissues. The very idea of the conditions necessary for the full course of reparative processes and the specific parameters of the suitability of the residual limb after its completion is beyond the competence of surgeons. Especially it concerns the backbone of a residual limb — its bone base. Despite a large number of studies on amputations and post-amputation pain syndrome, diseases, and defects of stumps [1–8], there are only a few reports [9, 10] that highlight reparative regeneration processes at the end of the bone remnant of the future working organ. The blood circulation of the bone residual limb in concomitant post-amputation pain syndrome remains unexplored, which is observed in 44.6–90 % of cases [11]. The development of post-amputation pain syndrome is based on the damage of peripheral structures of the nervous system involved in nociceptive signal conduction [12] with the development of

degenerative changes in the nerve. Subsequent regeneration of nerve fibers leads to the formation of neuroma [12], which can become a peripheral source of irritation. Due to the presence of a stable connection with the central cortical and thalamic levels, in some cases, the peripheral factor may gradually lose its importance and as time passes, the pain becomes “central”, affecting various aspects of the individual’s life activity, including blood circulation in the stump [6, 13, 14].

Neuropathic pain is characterized by disorders such as endothelial dysfunction, decreased local tissue perfusion, and local osteoporosis. According to Lavrishcheva G.I., Onoprienko G.A. [15], due to the absence of inducing function and the presence of pain syndrome, reparative osteogenesis in the bone residual limb is characterized by limited manifestation and short-term course. Starting from 4–6 weeks the capillary bed reacts, and the reparative phenomena subside, being replaced by a progressive process of bone tissue resorption and atrophy. Studying the local pain syndrome after amputation [16] we could clearly see the rapid

 © 2023. The Authors. This is an open access article under the terms of the Creative Commons Attribution 4.0 International License, CC BY, which allows others to freely distribute the published article, with the obligatory reference to the authors of original works and original publication in this journal.

Для кореспонденції: Шевчук Віктор Іванович, доктор медичних наук, професор, директор Науково-дослідного інституту реабілітації осіб з інвалідністю Вінницького національного медичного університету імені М.І. Пирогова, 21029, Хмельницьке шосе, 104, м. Вінниця, Україна; e-mail: shevchukndiri@gmail.com

For correspondence: Viktor I. Shevchuk, MD, DMSc, Professor, Director of the Institute, Orthopedics and Traumatology Department, Scientific Department, Scientific and Research Institute of Rehabilitation of National Pirogov Memorial Medical University, 21029, Khmelnytsky highway, 104, Vinnytsia, Ukraine; e-mail: shevchukndiri@gmail.com

Full list of authors’ information is available at the end of the article.

development of osteomyodystrophic process in the bone residual limb which sometimes starts in the preoperative period and rapidly develops in the early postoperative period. It was expressed in rarefaction, pronounced dystrophic and necrotic processes of the compact bone, violation of reparative osteogenesis, inflammatory and dystrophic changes of nerves against the background of circulatory disorders.

The currently available works mainly consider the treatment of pain syndrome, which is neuropathic [12, 17–21]. In order to prevent trophic disturbances, the emphasis is mainly on early treatment, including both resection of the neuroma and various methods aimed at suppressing the pathological activity of the peripheral link and activation of the antinociceptive system. These include drugs (ketamine, morphine, tramadol [22], NSAIDs, anticonvulsants [23, 24], antidepressants [23], and novocaine blocks [24]). The use of neurostimulation [17] and vibrotherapy [19] is considered promising. However, despite such a wide arsenal of influence on pain syndrome, its effectiveness is insufficient [25]. Earlier measures, preventing the occurrence and reducing the negative impact of the pain syndrome on blood circulation are needed.

From the point of view of some researchers [20, 26] to prevent the development of pain syndrome and associated disorders of tropism and bone tissue regeneration of the end stump, it is advisable to perform epidural or intravenous analgesia for 48 hours before and 48 hours after surgery at the stage of preoperative preparation and surgery. In our opinion, this approach is rational; however, the timing of anesthesia is clearly insufficient to prevent circulatory disturbances in the residual limb. Taking into account the data [25] on the early and rapid development of circulatory disorders after limb amputation, we considered it reasonable to study the effect of a month-long local analgesia on the blood circulation pattern in the bone residual limb.

The purpose of the research was to study the effect of post-amputation pain syndrome on the nature of blood circulation in the bone residual limb.

Materials and methods

Study design

The study was conducted on 54 mature adults (age 6–8 months) male rabbits of the Chinchilla breed (average animal weight 3.01 ± 0.30 kg) kept in the vivarium under the natural light regime, the usual temperature and a regular diet.

Three experimental series were formed: in the first one — during amputation, a perineural catheter was brought to the sciatic nerve stump, by which mechanical irritation of the sciatic nerve was performed daily for 20 days for 20 minutes ($n = 15$); in the second — in addition to irritation of the nerve, 0.3 ml of 1% lidocaine was injected through the catheter into the nerve environment daily for 20 days twice a day ($n = 24$); in the third — nerve irritation and analgesia were not performed ($n = 15$). The periods of observation in series 1 and 3 were 1, 3, 6 months, 5 animals each, in the second series, 7, 14, 21 days, 3 animals each, 1, 3, 6 months, 5 animals each.

Ethics committee approval. Ethics committee approval for this study was obtained (approval No. 3/2023).

Surgical interventions

Surgical interventions were performed in the vivarium operating room under general anesthesia (intra-abdominal injection of a mixture of xylazine (sedazin, Poland, 15 mg/kg) and ketamine (calypsol, Gedeon Richter Plc., Hungary, 70 mg/kg)). The animal was positioned with its abdomen up, fixed, shaved in the right thigh, and treated with povidone iodine solution (betadine, EGIS, Hungary). A flap incision of the skin with subcutaneous tissue and fascia was made in the middle third of the thigh. The muscles were transected. Vessels were tied with catgut. Nerves were crossed after perineural injection of 1% lidocaine. We made a circular crossing of the periosteum. It was moved distally with a raspator and then the bone was resawed. A perineural catheter was brought to the sciatic nerve stump and intimately fixed to the tissues. The second end of the catheter was led through the contraperitoneum to the posterior surface of the thigh, fixing it with sutures to the skin. The antagonist muscles were sutured over the blade. The wound was sutured in layers. To prevent infectious complications, bicillin-5 solution (Kievmedpreparat, Ukraine) was injected subcutaneously in the posterior cervical area at a dose of 1 million units per 1 kg of live weight (3 million).

Histological analysis

In all the experiments we used ink filling of the vessels. Before withdrawal from the experiment, the animal was intra-arterially injected with 3,000 units of heparin in the physiological solution. After 15 minutes, a lethal dose (0.5 ml) of hexenal was rapidly injected intravenously and the abdominal aorta was ligated. Below the ligature, a cannula was inserted fixing it in the vessel's lumen, and 10% ink-gelatin mixture was infused according to Onoprienko G.A. (1968). One day later, the femur was isolated in the hip joint. The interrelations between soft tissues and bone were visually assessed, after which the femoral stump was freed from soft tissues, leaving them only on the end surface. The specimen was fixed in 12% formalin solution and decalcified with 15% nitric acid solution. The articular end was cut off from the obtained preparation of a whole bone stump of the femur. The remaining section was taken for the study. A sagittal section was made through the middle of the bone, which was block cast in celloidin. Sections 15–30 μm thick were stained with hematoxylin and eosin and van Gieson. Also, enlightened sections were made — longitudinal and transverse 100–150 microns thick and 20–30 microns thick for histological preparations. The enlightened sections and histotopographic preparations were studied under an MBS-2 microscope with simultaneous histological examination of adjacent sections. We evaluated the condition of the microcirculatory network of bone filled with an ink-gelatin mixture, taking into account (without special measurements) the density of the vessels' location and their diameter. When studying bone stumps, attention was paid to changes in the cortical diaphyseal plate, the shape of the end section and the nature of its constituent bone structures, the presence of closed bone medullary cavity, the formation of the closure bone plate, the state of tissues inside the medullary canal. The character of soft tissue coverage of the end surface of the bone stump was also studied.

Histologic sections of nerve fibers were stained with hematoxylin and eosin and impregnated by the Bolshovsky-

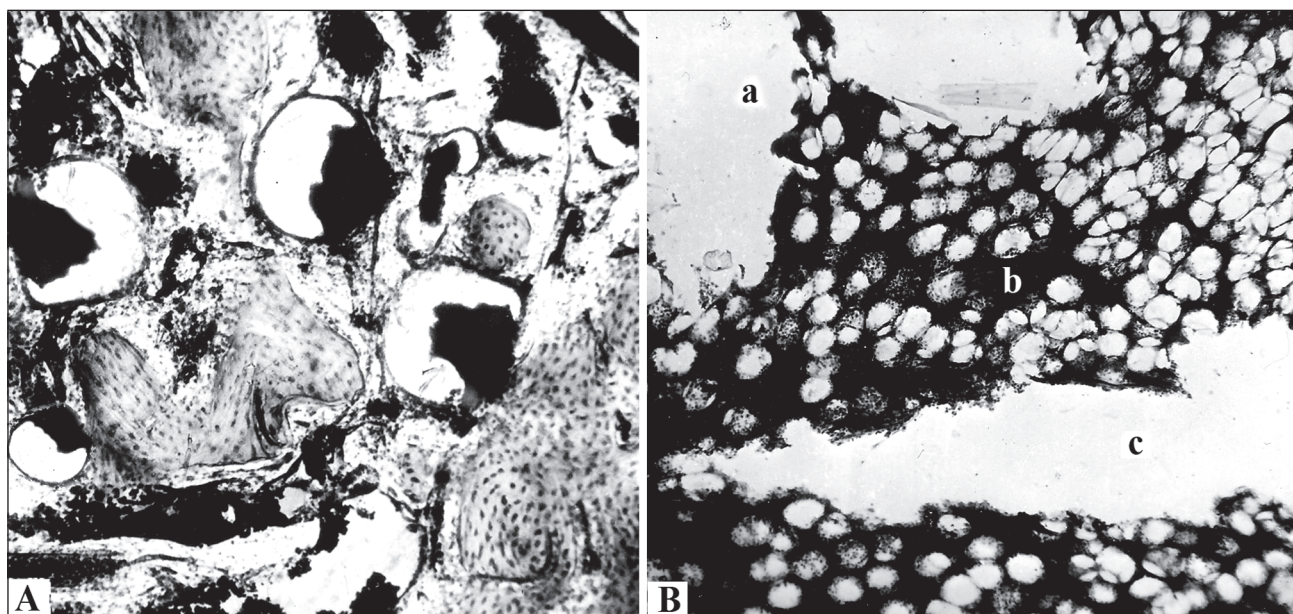


Figure 1. Microphotographs. A — sinusoidal type vessels with wide lumens in loose fibrous tissue of interbody spaces. B — multiple tissue cysts (a) and sinusoids (b) in the fatty bone marrow of the end of the medullary canal; venous sinus (c). Hematoxylin and eosin staining, 78×

Gross method in the modification of Lavrentiev [27]. Nerve sections were fixed in a 15% solution of neutral formalin, changing the fixative solution 3 times. Sections 20–60 μm thick were prepared on a freezing microtome. The sections were embedded in a 20% solution of silver nitrate, a 20% solution of acidic formalin, silver ammoniumate, and ammonia water. Sections were washed in distilled water until the ammonia smell disappeared and transferred to a solution of gold chloride, and then to a 5% aqueous solution of sodium thiosulfate, washed with distilled water, dehydrated in alcohols, and placed in balsam.

The experiments were performed in accordance with the principles of humane treatment of animals set forth in the European Community directives (86(609) EEC) and the Helsinki Declaration on Humane Treatment of Animals.

Results

The first experimental series, n = 15

Term 1 month, n = 5. The beams of endosteal regenerate at the end of the residual limb are immature. Nicks are determined in them. In the inter-bar spaces, loose fibrous and fibroreticular tissue, multiple wide vessels and cysts were impregnated with ink (Fig. 1A, B). Focal bone marrow avascularity is noted. In the proximal part of the medullary cavity there are large dilated branches of the feeding artery filled with carcasses (Fig. 2). Bone marrow with sharply dilated sinusoids and multiple cysts. Avascularity of the end of the cortical diaphyseal layer over 1–2 cm is observed (Fig. 3). Above this zone, there is enlargement of a part of Haversian and Volkmann's canals. The absence of cellular elements is noted in many of them. Impoverishment and irregularity of vascular network. The capillaries are located near the wall in connection with perivascular edema (Fig. 4).

Term 3 months, n = 5. The avascularity of the end of the bone stump was preserved. The beginning of the ingrowth of

sinusoidal capillaries from the vascular network of the medullary canal and cortical diaphyseal layer into this zone is noted. Proximal to this zone the vascular canals of the cortical diaphyseal layer are dilated to a considerable extent. There is a scarcity of the vascular bed and an absence of cellular

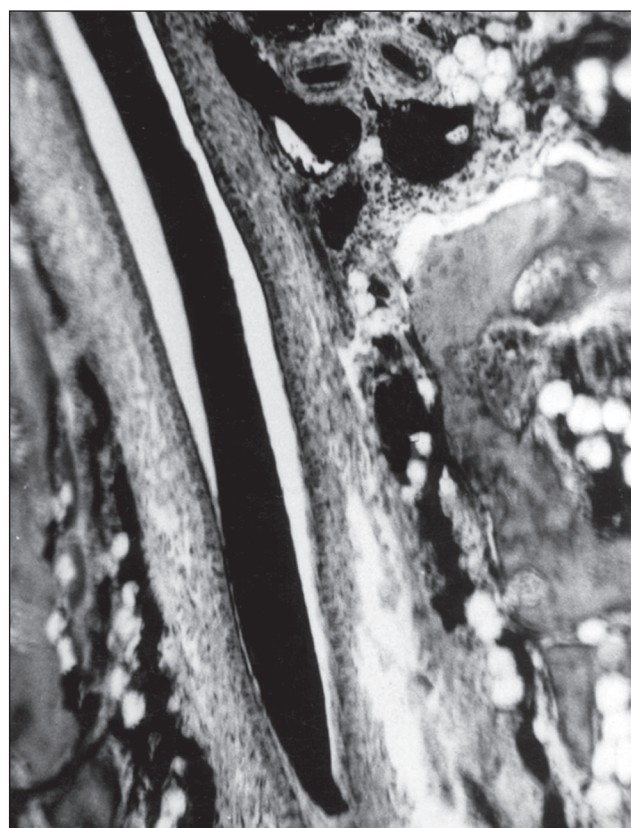


Figure 2. Microphotograph. Feeding artery in the medullary canal with sharply dilated, ink-filled sinusoids. Staining with hematoxylin and eosin, 90×

composition in the Haversian canals. Some of them contain altered sinusoidal microvessels with the phenomenon of carcass diffusion into the perivascular space (Fig. 5). In the center of the medullary canal, there was edematous loose fibrous tissue, and large tissue cysts with enlarged microvessels in the walls. Periosteal edema of medullary contents. In the proximal part of the medullary canal, edematous adipose bone marrow with foci of avascularity and wide areas of carcass-soaked loose fibrous tissue, numerous cysts, and sinusoidal vessels are determined to a considerable extent. There is also a sharply dilated nutrient artery and its branches.

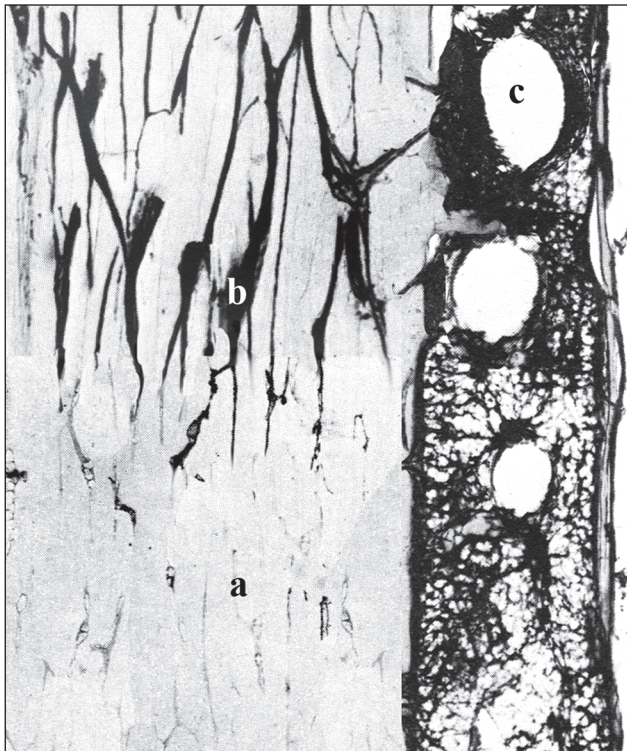

Figure 3. Microphotograph. Avascularity of the cortical diaphyseal layer at the end of the stump (a), significant dilation of the cortical diaphyseal layer vessels in the proximal portion (b), microcysts along the endosteal surface (c). Enlightened slice, 18x

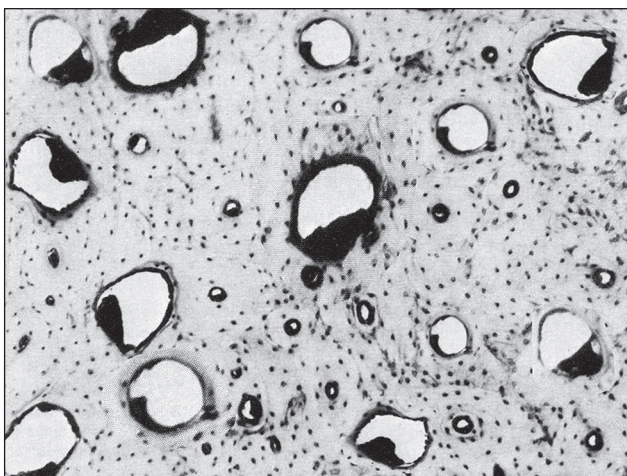


Figure 4. Microphotograph. Perivascular edema of enlarged Haversian canals with walled arrangement of wide capillaries. Hematoxylin and eosin staining, 90x

Vessels of periosteum and surrounding soft tissues are dilated. There is edema in the inter-bar spaces, microvessels in the form of sinuses. Between the beams of endosteal bone formation there are lumens of carcass-filled dilated branches of the feeding artery (Fig. 6), passing from the medullary canal through the endosteal regenerate into the fibrous tissue fringe. In it, foci of loose fibrous tissue are revealed among the dense fibrous tissue around the feeding artery and its branches.

Term 6 months, n = 5. Dilation of the majority of canals of the cortical diaphyseal layer is preserved. Vessels and tissue elements are absent in some of them. Longitudinal and transverse anastomosing vessels connecting the network of cortical diaphyseal layer and medullary cavity are visible. Some vessels and interbody spaces of the endosteal bone formation contain a finely looped network of narrow capillaries and the rest contain wide varicose sinusoids. In the preserved avascular microsections of the cortical diaphyseal plate, broad sinusoidal capillaries sprout from the vessels of the medullary canal and cortical diaphyseal layer. The microvascular network is far from uniform. There are many vessels with de-

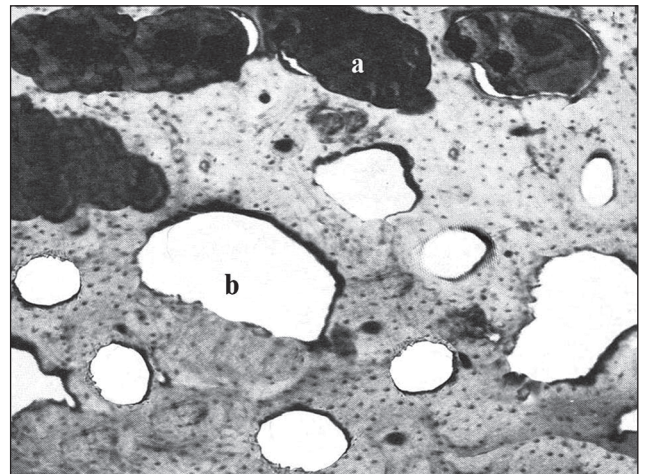


Figure 5. Histotopogram. Dilated vascular canals with perivascular accumulation of carcasses (a), vascular canals with absence of tissue elements and vessels (b). Hematoxylin and eosin staining, 60x

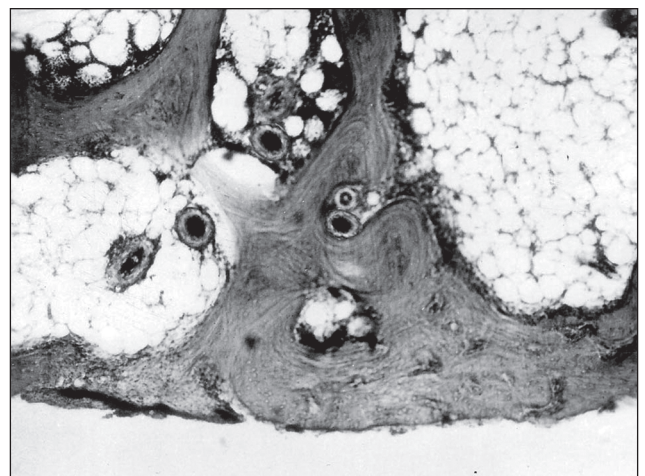


Figure 6. Microphotograph. Ink-filled lumen of branches of feeding artery among not quite mature bone tissue of closing bone structures. Hematoxylin and eosin staining, 90x

creased contrast. Their contours are uneven. Phenomena of perivascular edema remained. There are dilated branches of the feeding artery, veins, sinusoidal vessels, and tissue cysts in the medullary canal throughout. The capillary network is impoverished. Focal avascularity and wall edema of medullary contents lead to dystrophic changes, necrosis of fatty bone marrow, and its replacement by fibrous connective tissue.

Examination of the nerve and surrounding tissues revealed a picture of neuritis. We observed pronounced edema, degeneration of nerve fibers, infiltration of nerve trunk with lymphocytes, arteritis, and arterial obliteration. Consequent exudation caused thinning and fragmentation of nerve fibers, and pronounced edema of the epineurium, perineurium, and endoneurium. Hypertrophy of lemmocytes with vacuolization of their cytoplasm was noted.

The second experimental series, n = 24

Term 7 days, n = 3. Enlightened preparations reveal avascular areas of the cortical diaphyseal layer of the end of the residual limb for 1.5–2 cm. Proximally, the Haversian and Volkmann's canals are sharply enlarged. They contain proliferating vessels with phenomena of carcass exiting into the perivascular space. In the proximal parts of the medullary canal cellular-fibrous tissue of osteoblastic type. It contains a large number of small cysts and a small number of microvessels. Most of the large vessels are in a state of sharp dilation with phenomena of perivascular carcass diffusion. Significantly dilated microvessels with irregular carcass filling are detected in the intercalary spaces.

Term 14 days, n = 3. Avascularity of the cortical diaphyseal layer is preserved. Vascular anastomoses between

the intramedullary network, haversacks and periosteum are formed. On the side of the vascular network of the medullary canal, cortical diaphyseal layer and surrounding tissues, wide newly formed sinusoidal capillaries ingrown into the avascular areas. The absolute majority of functioning vascular canals are irregularly and sharply dilated. They contain tissue elements, enlarged proliferating microvessels with carcass diffusion phenomena. In the interbody spaces of periosteal and endosteal bone formation small and large dilated vessels with porosity of walls. Full blood vessels of medullary cavity. Diffusion of carcass into perivascular space is noted. Here also a large number of tissue cysts connected with microvascular network. Far from the file in the medullary canal the adipose bone marrow with dilated vessels, irregular microvascular network and a small number of tissue cysts.

Term 21 days, n = 3. Active revascularization of the cortical diaphyseal layer takes place. It is close to completion (Fig. 7). A powerful anastomosis network was formed due to the periosteum, intramedullary network and Haversian system. Part of the Volkmann's canals connect and form canals perforating the cortical layer. Avascular areas are practically absent. Most of the functioning vascular canals remain dilated. The vascular network of the cortical bone tissue is represented mainly by capillaries of the interbody spaces, and the endosteal bone elements by dilated sinusoidal vessels. No diffusion phenomena of the carcass were detected. Vessels of the medullary cavity were moderately dilated.

Term 1 month, n = 5. The end of bone filing after amputation of a limb is closed by a bone closure plate of osteon-beam and osteon structure. Numerous transversely and obliquely directed dilated anastomosing vessels running from the periosteum into the medullary cavity are observed. There is a rearrangement of the vascular network of the cortical diaphyseal layer with the phenomena of increased vascular permeability. There is a part of moderately dilated vessels of the Haversian canals, a parietal arrangement of the vessels. Vascular network of medullary cavity is also close to normalization. Individual sinusoidal capillaries were found. No diffusion phenomena of carcasses were detected. In the interstitial spaces the fatty marrow with the presence of tissue cysts and minor edema. The branches of the feeding artery narrowed and reduced closer to the end of the stump. The phenomena of endosteal regenerate perforation by the branches of the feeding artery were not observed in any of the cases.

Term 3 months, n = 5. The medullary canal is closed by a bone lamina of compact and osteon-beam structure. The vascular network of the cortical diaphyseal layer approached that of normal bone, although a small number of Haversian canals remained moderately dilated. In the proximal part of the medullary canal, the fatty bone marrow with a normal and abundant vascular network. In the intercostal spaces fatty bone marrow with the presence of single tissue cysts. The branches of the main vessels at the end of the stump in the endosteal regenerate are not detected.

Term 6 months, n = 5. The shape of the end of the residual limb was cylindrical. The end of bone filing after amputation of a limb is closed with a compact bone lamina. The state of the vascular network of the cortical diaphyseal layer cor-

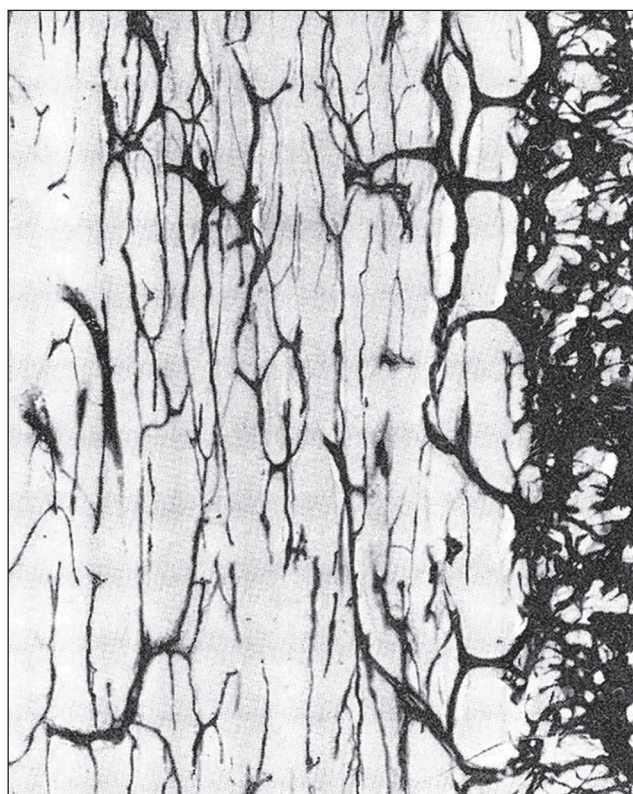


Figure 7. Microphotograph. Revascularization of the cortical diaphyseal layer. Enlightened slice, 18x

responds to the previous period. In the proximal part of the medullary canal the fatty bone marrow with a characteristic vascular network is determined. Carcass-filled branches of feeding artery of normal width and dilated venous sinus, single tissue cysts are revealed. At the end of the stump the vessels are defined as small branches among the fatty marrow. Larger branches are absent here, apparently due to obliteration.

The truncated sciatic nerve has a thickening at the end. Dystrophic changes, chaotic arrangement of fibers, forming a tangle with growth flasks and spirals were noted in all terms. No inflammatory phenomena were observed.

The third (control) group, n = 15

Term 1 month, n = 5. In all cases there was avascularity of the cortical diaphyseal layer of the stump end over 1–2 cm, proximally there was dilation of Haversian and Volkmann's canals. In them there can be seen the vessels located near the wall. Some of them are filled with plasma. The medullary canal has loose fibrous tissue, edema, tissue cysts, sinusoidal vessels. The branches of the feeding artery are dilated with carcass diffusion into the perivascular space.

Term 3 months, n = 5. Avascularity of the cortical diaphyseal layer was preserved in three observations and absent in two. Above the area of avascularity there were dilated Haversian canals with a parietal arrangement of vessels, cysts of various sizes. In the proximal part of the medullary canal, ink-soaked edematous fatty bone marrow and loose fibrous tissue with a large number of sinusoidal vessels and cysts. Vessels of medullary cavity are significantly dilated with the phenomenon of carcass exiting into perivascular space. In the interdural spaces and endosteum there were dilated sinusoidal vessels with carcass exiting beyond the vascular wall and branches of the feeding artery passing into the soft tissue fringe of the stump.

Term 6 months, n = 5. Avascularity of the cortical diaphyseal layer was absent. The vascular bed of the bone tissue is sparse, there is a lack of cellular composition in part of the Haversian canals. In three observations the process of bone tissue resorption along the vascular canals from the medullary cavity and periosteal surface was increasing. Slit-like spaces with sharply dilated sinusoidal microvessels are revealed in the cortical layer. There is a carcass exiting into the perivascular space. Between the beams of endosteal bone formation there are lumen of large branches of feeding artery filled with carcass, passing from medullary cavity to fibrous tissue border.

The nerve trunk with thickening at the end. Heterogeneous maturation of connective tissue was traced. There were non-vascular zones formed by clusters of thick bundles of collagenous fibers. In two observations there was infiltration of nerve trunk with lymphocytes, edema of epineurium, perineurium and endoneurium. In the remaining observations there was no inflammatory process of the nerve.

Discussion

After amputation, compensation of circulatory disorders in all three series of experiments is carried out by including reserve sources of blood circulation — medullary network, periosteal network and surrounding soft tissues. Revascularization is facilitated by maximal development of anastomosing vessels and the existing bone microcirculatory channel with the inclu-

sion of collateral circulation. The restoration of stump microcirculation proceeds by means of the same type of changes: regional hypervascularization, increased capacity of the terminal vascular bed with sinusoidal change of capillaries and increased vascular permeability, formation of multiple tissue microcysts associated with the microvascular network. These changes are aimed at eliminating circulatory disorders and providing metabolic needs of the regenerating tissues by maximizing the use of extravascular microcirculatory pathways.

The presence of pain syndrome in the first experimental and most observations of the control series causes certain changes in the microcirculation, the structure of the cortical diaphyseal layer and the content of the medullary canal. The leading ones are preservation of long-term, up to 3–6 months, avascularity of the stump end, lumen dilation of the main vessels, progressive impoverishment of the microcirculatory network, increased vascular permeability with development of persistent perivascular edema, appearance of hemorrhages, formation of extensive cystic cavities, disappearance of cellular elements of vascular channels of the cortical layer, bone tissue resorption along the vascular channels and endosteal surface on the background of absence of proliferative processes both in the bone tissue and the endosteal surface.

Already at 3 months there is an increase in the processes of bone tissue and microcirculatory channel reorganization with the predominance of resorption at a very slow rate of bone formation. Small focal spongization becomes continuous. A large number of intraosseous cavities are formed in the cortical layer and filled with cellular-fibrous tissue. The latter is punctured by a fine-lobed capillary network with the phenomena of increased permeability, as well as tissue microcysts. The moderately dilated bone canals have wide tortuous capillaries. Diffusion supply is not reduced. Microcracks with proceeding processes of bone tissue regeneration are revealed. The process of microcirculatory channel and cortical diaphyseal structure restoration becomes protracted and often irreversible.

At the 6-month period, these changes worsened. The processes of microcirculation and reparative regeneration were incomplete in such stumps, and the bone tissue underwent intensive remodeling for months. Closure of the medullary canal was performed by bone regenerate with soft tissue inclusions. In a number of cases these were the main bone vessels exiting the medullary canal into the surrounding soft tissues.

A distinctive feature of the results of the second series of experiments, where the pain syndrome was stopped, was a more rapid and active onset of the processes aimed at residual limb tissue revascularization. This was expressed in irregular, sharper dilation of Haversian and Volkmann's canals, medullary cavity and periosteal vessels, formation of anastomoses, more pronounced vascular permeability, increase in perivascular edema, significantly faster, within 3 weeks, vascularization of avascular areas, formation of the bone closure plate of compact structure with completion of the reparative process in 3–6 months.

There is vascular proliferation of thickened periosteum with the formation of sinusoidal capillaries, which are initially connected to the vascular network of the surrounding soft tissues, and later to the vessels of the Haversian system. In the superficial layers of the cortical layer a longitudinally ori-

ented network of wide vessels is formed, which are a regional collector of blood circulation pathways. They have a direct connection to the vascular network of medullary cavity.

Irregularity of the microcirculatory channel of the cortical diaphyseal layer and medullary cavity with increased vascular permeability and perivascular edema in contrast to the experiments of series 1 and 3 causes moderate bone tissue resorption along the vascular channels and partial temporary replacement of the fatty bone marrow with loose fibrous tissue against the background of reduced proliferative processes. These changes persist up to 3 months and then tend to decrease and recover. The proportion of diffusion nutrition by 3 months significantly decreases.

The obtained results slightly differ from Lavrishcheva G.I., Onoprienko G.A. [15]. However, it should be noted that the author studied the vascular network of the bone after amputation without performing muscle plasty and taking into account the effect of pain syndrome on microcirculation. Our data coincide with the results of Bezsmertnyi Y., Shevchuk V., Jiang Y. [25], who studied the influence of pain syndrome and main intraosseous vessels on the formation of the bone residual limb and deepen them.

When pain syndrome is relieved, microcirculatory disorders, which inevitably accompany amputation, are intense at first, then they are minimal and short-lived. By six months there is a clear tendency towards normalization of the microcirculation and microstructure of the cortical diaphyseal layer. In most of the latter there is a typical pattern of Haversian and Volkmann's systems with a normal microcirculatory network. The vascular network of the medullary cavity is also close to normal.

Conclusions

Post-amputation pain syndrome causes abrupt macro- and microcirculatory disturbances and degenerative-dystrophic changes in residual limb tissues. Revascularization of the bone residual limb occurs due to the preserved sources of blood circulation (intramedullary vascular network, periosteum and surrounding soft tissue) anastomosing vessels and extravascular pathways of microcirculation (increased vascular permeability, formation of sinusoidal capillaries and tissue cysts).

Cure of pain syndrome within 20 days after amputation allows significantly level the resulting circulatory disturbances in the limb stump, reduce the terms of revascularization and reparative regeneration of bone tissue.

References

- Ahmed A, Bhatnagar S, Mishra S, Khurana D, Joshi S, Ahmad SM. Prevalence of Phantom Limb Pain, Stump Pain, and Phantom Limb Sensation among the Amputated Cancer Patients in India: A Prospective, Observational Study. *Indian J Palliat Care*. 2017 Jan-Mar;23(1):24-35. doi:10.4103/0973-1075.197944.
- Ahuja V, Thapa D, Ghai B. Strategies for prevention of lower limb post-amputation pain: A clinical narrative review. *J Anaesthesiol Clin Pharmacol*. 2018 Oct-Dec;34(4):439-449. doi:10.4103/joacp.JOACP_126_17.
- Allami M, Faraji E, Mohammadzadeh F, Soroush MR. Chronic musculoskeletal pain, phantom sensation, phantom and stump pain in veterans with unilateral below-knee amputation. *Scand J Pain*. 2019 Jul 4;19(4):779-787. doi:10.1515/sjpain-2019-0045.
- Shevchuk VI, Bezsmertnyi YuO, Bezsmertna GV, Dovgalyuk TV, Jiang Y. Peculiar features of regeneration at the end of bone filing after amputation of a limb. *World of medicine and biology*. 2021;(75):229-234. doi:10.26724/2079-8334-2021-1-75-229-234.
- Shevchuk VI, Bezsmertnyi YuO, Bezsmertna HV, Dovgalyuk TV, Jiang Y. Reparative regeneration at the end of bone filing after osteoplastic amputation. *Wiad Lek*. 2021;74(3 cz 1):413-417. doi:10.36740/WLek202103106.
- Bosanquet DC, Glasbey JC, Stimpson A, Williams IM, Twine CP. Systematic review and meta-analysis of the efficacy of perineural local anaesthetic catheters after major lower limb amputation. *Eur J Vasc Endovasc Surg*. 2015 Aug;50(2):241-249. doi:10.1016/j.ejvs.2015.04.030.
- Buch NS, Qerama E, Brix Finnerup N, Nikolajsen L. Neuromas and postamputation pain. *Pain*. 2020 Jan;161(1):147-155. doi:10.1097/j.pain.0000000000001705.
- Buntragulpoontawee M, Pattamapasong N, Tongprasert S. Multiple Neuromas Cause Painful "Jumping Stump" in a Transfemoral Amputee: A Case Report. *Int J Low Extrem Wounds*. 2016 Sep;15(3):271-273. doi:10.1177/1534734616657964.
- Buchheit T, Hsia HJ, Cooter M, et al. The Impact of Surgical Amputation and Valproic Acid on Pain and Functional Trajectory: Results from the Veterans Integrated Pain Evaluation Research (VIPER) Randomized, Double-Blinded Placebo-Controlled Trial. *Pain Med*. 2019 Oct 1;20(10):2004-2017. doi:10.1093/pm/pnz067.
- Dumanian GA, Potter BK, Mioton LM, et al. Targeted Muscle Reinnervation Treats Neuroma and Phantom Pain in Major Limb Amputees: A Randomized Clinical Trial. *Ann Surg*. 2019 Aug;270(2):238-246. doi:10.1097/SLA.0000000000003088.
- Ayyaswamy B, Saeed B, Anand A, Chan L, Shetty V. Quality of life after amputation in patients with advanced complex regional pain syndrome: a systematic review. *EFORT Open Rev*. 2019 Sep 3;4(9):533-540. doi:10.1302/2058-5241.4.190008.
- Harrison C, Epton S, Bojanic S, Green AL, FitzGerald JJ. The Efficacy and Safety of Dorsal Root Ganglion Stimulation as a Treatment for Neuropathic Pain: A Literature Review. *Neuromodulation*. 2018 Apr;21(3):225-233. doi:10.1111/ner.12685.
- Culp CJ, Abdi S. Current Understanding of Phantom Pain and its Treatment. *Pain Physician*. 2022 Oct;25(7):E941-E957.
- Canavero S, Bonicalzi V. *Central pain syndrome*. 3rd ed. Cham: Springer; 2018. 543 p. doi:10.1007/978-3-319-56765-5.
- Lavrishcheva GI, Onoprienko GA. *Morfologicheskie i klinicheskie aspekty reparativnoi regeneratsii opornykh organov i tkanei [Morphological and clinical aspects of reparative regeneration of supporting organs and tissues]*. Moscow: Meditsina; 1996. 208 p. (in Russian).
- Bezsmertnyi YuO. Morphological changes during amputation of tissues of the lower end of the joint with muscle pain syndrome. *Reports of Morphology*. 2004;(2):228-231. (in Ukrainian).

17. Knotkova H, Cruciani RA, Tronnier VM, Rasche D. Current and future options for the management of phantom-limb pain. *J Pain Res.* 2012;5:39-49. doi:10.2147/JPR.S16733.
18. Privitera R, Birch R, Sinisi M, Mihaylov IR, Leech R, Anand P. Capsaicin 8% patch treatment for amputation stump and phantom limb pain: a clinical and functional MRI study. *J Pain Res.* 2017 Jul 13;10:1623-1634. doi:10.2147/JPR.S140925.
19. Ramachandran V, Chunharas C, Marcus Z, Furnish T, Lin A. Relief from intractable phantom pain by combining psilocybin and mirror visual-feedback (MVF). *Neurocase.* 2018 Apr;24(2):105-110. doi:10.1080/13554794.2018.1468469.
20. Hanyu-Deutmeyer AA, Cascella M, Varacallo M. *Phantom Limb Pain.* In: StatPearls. Treasure Island, FL: StatPearls Publishing; 2023 Jan.
21. Dommerholt J, Mayoral O, Thorp JN. A critical overview of the current myofascial pain literature - January 2021. *J Bodyw Mov Ther.* 2021 Jan;25:261-271. doi:10.1016/j.jbmt.2020.12.044.
22. Fang J, Lian YH, Xie KJ, Cai SN. Pharmacological interventions for phantom limb pain. *Chin Med J (Engl).* 2013 Feb;126(3):542-549.
23. Brzeziński K, Rękas-Dudziak AR, Maruszewska A. Pulsed radiofrequency as alternative method for phantom pain treatment. *Clin Case Rep.* 2020 Jul 20;8(10):2060-2062. doi:10.1002/ccr3.3110.
24. Nardone R, Versace V, Sebastianelli L, et al. Transcranial magnetic stimulation in subjects with phantom pain and non-painful phantom sensations: A systematic review. *Brain Res Bull.* 2019 May;148:1-9. doi:10.1016/j.brainresbull.2019.03.001.
25. Bezsmertnyi YuO, Shevchuk VI, Jiang Y. The influence of post-amputation pain syndrome and intraosseous main vessels on the formation of limb bone stump. *Orthopaedics, traumatology and prosthetics.* 2023;(1-2):20-25. doi:10.15674/0030-598720221-220-25. (in Ukrainian).
26. Karanikolas M, Aretha D, Tsolakis I, et al. Optimized perioperative analgesia reduces chronic phantom limb pain intensity, prevalence, and frequency: a prospective, randomized, clinical trial. *Anesthesiology.* 2011 May;114(5):1144-1154. doi:10.1097/ALN.0b013e31820fc7d2.
27. Horalsky LP, Khomych VT, Kononskyi OI. *Histological techniques and methods of morphological studies in normal and pathological conditions.* 3rd ed. Zhytomyr: Polissja; 2015. 286 p. (in Ukrainian).

Received 02.05.2023

Revised 30.05.23

Accepted 04.06.23 ■

Information about authors

Viktor I. Shevchuk, MD, DMSc, Professor, Director of the Institute, Orthopedics and Traumatology Department, Scientific Department, Scientific and Research Institute of Rehabilitation of National Pirogov Memorial Medical University, Vinnytsia, Ukraine; <https://orcid.org/0000-0003-1105-4795>

Yurii O. Bezsmertnyi, MD, DMSc, Professor, Head of the Orthopedics and Traumatology Department, Head of the Scientific Department, Scientific and Research Institute of Rehabilitation of National Pirogov Memorial Medical University, Vinnytsia, Ukraine; <https://orcid.org/0000-0002-1388-7910>

Yankai Jiang, MD, Doctor, Orthopedics and Traumatology Department, Researcher, Scientific Department, Scientific and Research Institute of Rehabilitation of National Pirogov Memorial Medical University, Vinnytsia, Ukraine; <https://orcid.org/0000-0001-8100-3438>

Halyna V. Bezsmertna, MD, PhD, Doctor, Orthopedics and Traumatology Department, Researcher, Scientific Department, Scientific and Research Institute of Rehabilitation of National Pirogov Memorial Medical University, Vinnytsia, Ukraine; ORCID ID: 0000-0003-1505-4872

Yuliia S. Sehedra, MD, PhD, Doctor, Orthopedics and Traumatology Department, Researcher, Scientific Department, Scientific and Research Institute of Rehabilitation of National Pirogov Memorial Medical University, Vinnytsia, Ukraine; <https://orcid.org/0000-0001-8282-7703>

Dmytro V. Bondarenko, MD, Doctor, Orthopedics and Traumatology Department, Researcher, Scientific Department, Scientific and Research Institute of Rehabilitation of National Pirogov Memorial Medical University, Vinnytsia, Ukraine; <https://orcid.org/0000-0001-8305-5899>

Conflicts of interests. Authors declare the absence of any conflicts of interests and own financial interest that might be construed to influence the results or interpretation of the manuscript.

Information about funding. The study was conducted within the framework of the research work "Stress bone injuries due to limb combat injuries" (registration number 0123U100170), funded by the Ministry of Health of Ukraine with the state budget.

Authors' contribution. V.I. Shevchuk — concept and design of study, text writing; Y.O. Bezsmertnyi — analysis of the data, text writing; Y. Jiang, Y.S. Sehedra — collection and processing of the material; H.V. Bezsmertna, D.V. Bondarenko — literature selection and analysis, article editing.

Шевчук В.І., Безсмертний Ю.О., Джіанг Я., Безсмертна Г.В., Сегеда Ю.С., Бондаренко Д.В.

Науково-дослідний інститут реабілітації осіб з інвалідністю Вінницького національного медичного університету імені М.І. Пирогова, м. Вінниця, Україна

Вплив післяампутаційного больового синдрому на кровообіг у куксі кистки

Резюме. *Актуальність.* Відсоток незадовільних результатів ампутацій досі високий. При цьому особливе місце займає загоєння кісткового залишку — основного опорного елемента кукси. *Мета:* вивчити вплив післяампутаційного больового синдрому на характер кровообігу в куксі кистки. *Матеріали та методи.* На 54 кроликах проведено три серії дослідів з ампутацією стегна. У 1-й та 2-й серіях до кукси сідничного нерва підводили периневральний катетер. За його допомогою в 1-й серії протягом 20 діб щодня по 20 хвилин механічно подразнювали нерв, викликаючи больовий синдром. У 2-й серії через катетер в оточення нерва 20 днів щодня двічі на добу вводили 0,3 мл 1% лідокаїну. Тварини 3-ї серії слугували контролем. Строки спостереження становили 1, 3, 6 місяців. Метод дослідження — гістологічний, з інфузією туш-желатиновою сумішшю. *Результати.* У тварин 1-ї серії зафіксовано аваскулярність кінця кукси та кісткового мозку, бідність судинного русла та відсутність клітинного складу в гаверсових ка-

налах, дистрофічні зміни жирового кісткового мозку, рарефікація, спонгізація, розсмоктування, надломи кісткової тканини. У досліді 2-ї серії аваскулярність швидко минала, у період до трьох місяців наставала стабілізація ангиоархитектоники. Реваскуляризація кукси кистки відбувалась за рахунок збережених джерел кровообігу (інтрамедулярна судинна мережа, окістя та прилеглі м'які тканини), анастомозуючих судин і позасудинних шляхів мікроциркуляції (підвищення судинної проникності, формування капілярів синусоїдного типу та тканинних кист). У більшості спостережень 3-ї серії процеси реваскуляризації були схожі з результатами 1-ї серії. *Висновки.* Післяампутаційний больовий синдром викликає різкі порушення макро- та мікроциркуляції. Його купірування протягом 20 днів після ампутації дозволяє значно нівелювати порушення кровообігу в куксі кистки.

Ключові слова: ампутація; больовий синдром; кукса кистки; кровообіг; регенерація