

UDC 616.132-007.2-02:616.24-008.4:616.329]-053.2

**O.O. Zborovska¹, A.A. Malska², R. Tammo³,
O. Teterin³, H.Ye. Morkovkina³**

Congenital vascular rings as a cause of respiratory and esophageal problems in children

¹National Pirogov Memorial Medical University, Vinnytsya, Ukraine

²Danylo Halytsky Lviv National Medical University, Ukraine

³SI «Scientific and Practical Medical Centre for Paediatric Cardiology and Cardiac Surgery of the Ministry of Health of Ukraine», Kyiv

Modern Pediatrics. Ukraine. (2023). 2(130): 104-108. doi 10.15574/SP.2023.130.104

For citation: Zborovska OO, Malska AA, Tammo R, Teterin O, Morkovkina HYe. (2023). Congenital vascular rings as a cause of respiratory and esophageal problems in children. Modern Pediatrics. Ukraine. 2(130): 104-108. doi 10.15574/SP.2023.130.104.

Congenital anomalies of the aortic arch include a wide range of anatomic pathologies, which may be completely asymptomatic or accompanied by severe respiratory and/or esophageal symptoms, especially in the case of complete vascular rings (VR).

Purpose — to draw the attention of pediatricians and family physicians to possible clinical presentations of aortic arch anomalies, namely VR, to increase their awareness of this pathology, that will contribute to differential diagnosis.

VR, are anomalies of the aortic arch that result from abnormal development of the embryonic aortic arches. The prevalence of VR is approximately 1%, of which 55% are double aortic arch. This congenital heart defect can be either isolated or combined with other congenital heart defects. Associated cardiac pathology occurs in 12.6%, and includes ventricular septal defect and Tetralogy of Fallot. Sometimes this defect is associated with DiGeorge's and Turner's syndrome.

The timing of appearance of clinical symptoms varies from the early neonatal period to adulthood. However, most patients develop clinical symptoms in the first months after birth, and they indicate the need of cardiac surgery during the first year of life. Given the serious consequences of this anomaly, VR should be included in the list of differential diagnoses of wheezing, stridor, difficulty swallowing and bronchial obstruction syndrome in children, especially when these symptoms appear since birth, are persistent and respond poorly to standard therapeutical approaches.

Therefore, it is important for pediatricians to be alert for a congenital heart defect such as VR as one of the possible causes of congenital stridor, wheezing, and swallowing disorders in infants.

Contrast-enhanced computed tomography and magnetic resonance imaging of the heart are the diagnostic modalities of choice for VR diagnosis. These diagnostic methods provide accurate location, nature of branching and dominance of the aortic arch as well as the degree of compression of the airway and esophagus. Three-dimensional reconstruction helps to plan future surgical intervention.

No conflict of interests was declared by the authors.

Keywords: aortic arch, vascular ring, wheezing, stridor, children.

Вроджені судинні кільця як причина дихальних та езофагеальних розладів у дітей

О.О. Зборовська¹, А.А. Мальська², Р. Таммо³, О.В. Тетерін³, Г.Є. Морковкіна³

¹Вінницький національний медичний університет імені М.І. Пирогова, Україна

²Львівський національний медичний університет імені Данила Галицького, Україна

³ДУ «Науково-практичний медичний центр дитячої кардіології та кардіохірургії МОЗ України», м. Київ

Вроджені аномалії дуги аорти включають широкий спектр анатомічних проблем, які можуть бути абсолютно безсимптомними або супроводжуватися тяжкими респіраторними і/або езофагеальними ознаками, особливо в разі повних судинних кілець (СК).

Мета — привернути увагу педіатрів і сімейних лікарів до можливих клінічних проявів аномалій дуги аорти, зокрема СК; підвищити їх поінформованість про цю патологію, що сприятиме диференційній діагностиці.

Судинні кільця — це аномалії дуги аорти, які виникають унаслідок порушення розвитку ембріональних дуг. Поширеність СК становить приблизно 1%, з яких 55% — подвійна дуга аорти. Ця вроджена вада серця може бути як ізольованою, так і поєднуватися з іншими вродженими вадами серця. Супутня серцева патологія зустрічається у 12,6% та включає дефект міжшлункової перегородки і тетраду Фалло. Іноді ця вада асоціюється із синдромом Діджорджі та Тернера.

Терміни виникнення клінічних симптомів варіюють від раннього неонатального періоду до дорослого віку. Однак у більшості пацієнтів клінічні симптоми виникають у перші місяці після народження і обумовлюють показання до кардіохірургічного лікування на першому році життя. Враховуючи серйозні наслідки цієї аномалії, СК слід внести до переліку діагнозів для проведення диференційної діагностики візінгу, стридору, при утрудненні ковтання та синдрому бронхіальної обструкції в дітей, особливо, коли ці симптоми з'являються від народження, є стійкими і погано відповідають на стандартні підходи до терапії.

Відтак педіатрам важливо бути настороженими щодо такої вродженої вади серця, як СК, однієї з причин вродженого стридору, візінгу та порушення ковтання в немовлят.

Комп'ютерна томографія з контрастним підсиленням і магнітно-резонансна томографія серця є діагностичними методами вибору для дослідження СК. Саме ці діагностичні методи дають змогу визначити розташування, характер розгалуження та домінування дуги аорти, а також визначити ступінь стиснення дихальних шляхів і стравоходу. Тривимірна реконструкція допомагає спланувати хірургічне втручання.

Автори заявляють про відсутність конфлікту інтересів.

Ключові слова: дуга аорти, судинне кільце, візінг, стридор, діти.

Introduction

During embryogenesis of aortic arch, a broad spectrum of congenital anomalies may develop.

Vascular rings (VR) — is a group of anomalies of aortic arch caused by impairment of the development of aortic arches. VR may be composed by not only aorta but by its branches and pulmonary artery [3,9,28]. This anomaly may be isolated or associated with other cardiac lesions, most frequently with Tetralogy of Fallot, patent ductus arteriosus, ventricular septal defect and different genetic syndromes like DiGeorge's and Turner's syndrome and occurs with the frequency of 1% of all congenital heart defects [13].

Vascular rings may partly or completely obstruct trachea and esophagus and lead to its compression.

Children with this pathology may be asymptomatic or may present with respiratory and esophageal problems, which happens more frequently and depends on the level of compression.

In most of the cases symptoms occur during the first month after birth and determine the indications of surgical correction during the first year of life [14].

In this article we present different clinical symptoms of VR based on our own clinical experience and literature overview with intention to guide pediatricians and family practitioners through this rare pathology.

Purpose of the study — to draw the attention of pediatricians and family physicians to possible

clinical presentations of aortic arch anomalies, namely VR, to increase their awareness of this pathology, that will contribute to differential diagnosis.

From anatomical point of view VR are classified into complete and incomplete, the following classification helps to understand the terminology better [6,17,22,27]:

Complete VR:

1. Double aortic arch (with dominant right or left arch or balanced form);
2. Right sided aortic arch with aberrant left subclavian artery, left-sided patent ductus arteriosus.

Incomplete VR:

1. Innominate artery compression syndrome;
2. Aberrant (retrotracheal) left (pulmonary artery sling);
3. Left-sided aortic arch with aberrant (retroesophageal) right subclavian artery.

Double aortic arch with equal functioning of the left and right arch — complete VR is shown on a CT scan Fig. 1 in this case vascular ring may compress trachea and esophagus.

The right-sided aortic arch with aberrant left subclavian artery and left arterial ligament are shown in Fig. 2, in this anatomical situation the VR will tightly compress trachea and esophagus.

The right-side aortic arch may be associated with aberrant left subclavian artery, in some cases this artery originates from an aneurismal dilation of the aorta called Kommerell's diverticulum.

Kommerell's diverticulum is a rare vascular anomaly that is described as an outpouch at the onset of an aberrant subclavian artery. In the

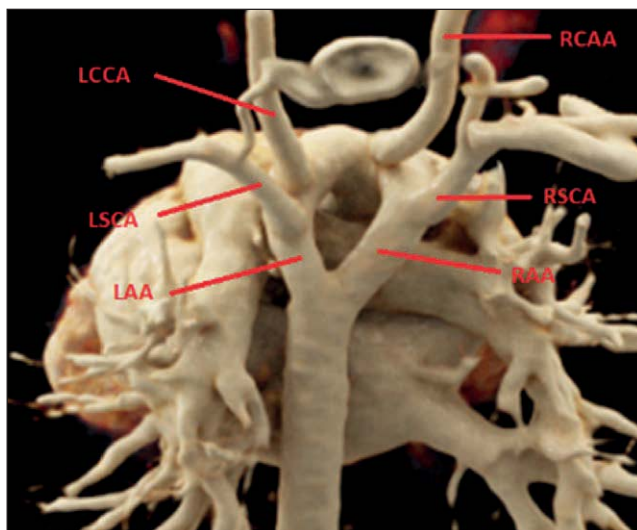


Fig. 1. Double aortic arch with equal functioning of the left and right arch — complete vascular ring (CT scan — courtesy of Pediatric Cardiac Surgery Center, Kyiv, Ukraine, Department of Radiology): RAA — right aortic arch; LAA — left aortic arch; RSCA — right subclavian artery; LSCA — left subclavian artery; LCCA — left common carotid; RCCA — right common carotid artery

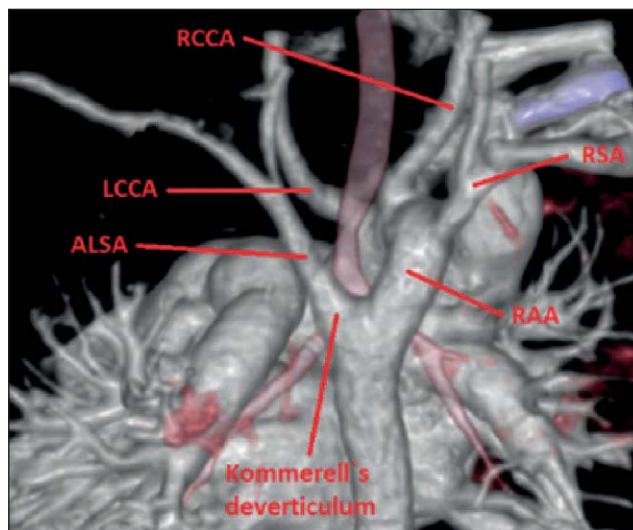


Fig. 2. Right-sided aortic arch with aberrant left subclavian artery and left arterial ligament: RAA — right aortic arch; RSA — right subclavian artery; LCCA — left common carotid; RCCA — right common carotid artery; Kommerell's diverticulum — bulblike widening of aorta in the place of arising of aberrant subclavian artery

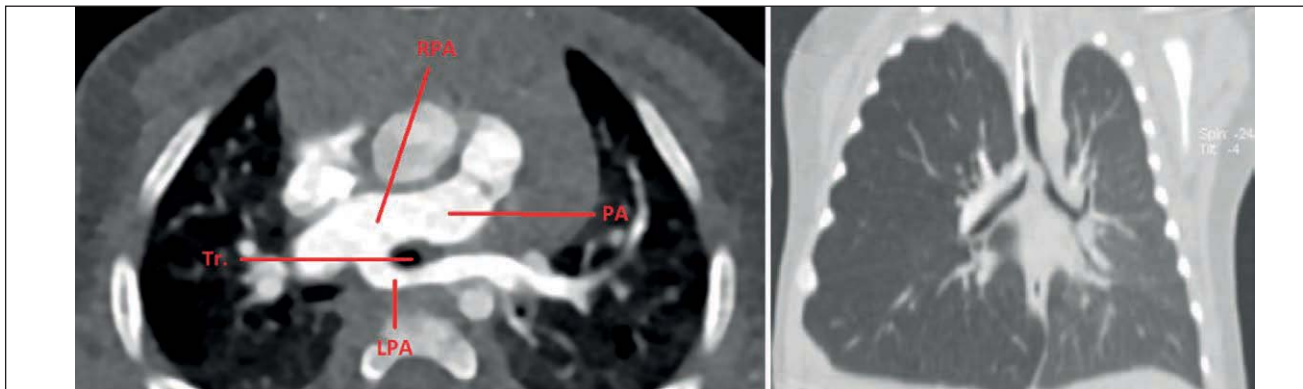

Fig. 3. Pulmonary artery sling: RPA — right pulmonary artery; PA — pulmonary artery; LPA — aberrant left pulmonary artery; Tr. — trachea

combination of an aberrant left subclavian artery, a Kommerell's diverticulum and persisting ductus arteriosus or ductal ligament enclose the lateral side and form a VR which may lead to symptomatic esophageal or tracheal compression. Kommerell's diverticulum is dangerous because of the possibility of its spontaneous rupture [5,21,23].

Fig. 3 shows pulmonary artery sling, that is formed as a result of left pulmonary artery arising from proximal part right pulmonary artery [10,19]. Lower part of the trachea will be surrounded by vascular structures that would lead to its compression.

Clinical presentation of VR differs in patients and is caused by compression effect of respiratory tract and/or esophagus and depends on the anatomical type, and tightness of compression.

Typically, clinical manifestation in a child with VR may begin with loud breathing and barking cough. In English literature barking cough is often compared with sounds made by a seal — «seal-bark cough», it's a typical cough which is similar to the sound that is produced by these two animals. Other frequent symptoms include stridor, wheezing, dyspnea during physical exercise and dysphagia, and frequent respiratory infections [15].

Y. Aladham et al. in their paper «Double aortic arch: a rare cause of stridor in infants» describe a clinical case of a 1-month-old infant, who presented with progressive stridor by 2 months of age. On examination child was afebrile with oxygen saturation levels of 94% on room air. On auscultation vesicular breath sounds with bilaterally reduced, yet equal, air entry with transmitted stridor were noticed. Chest X-ray did not reveal any pathology, as well as no foreign body on bronchoscopy, but there was the evidence of pulsatile circumferential constriction of the lower trachea noted, with tendency of the tracheal wall to collapse upon withdrawal of the bronchoscope. A contrast-enhanced computed tomography (CT) of the neck and chest was obtained and a VR,

consisting of a double aortic arch, compressing and narrowing the trachea was found. The patient underwent surgical repair with resection of the right arch. Further follow-up after 6 months showed resolution of the symptoms, and active observation was continued [1].

Authors conclude that a pediatric otolaryngologist must have a high index of suspicion in order to diagnose VR anomalies in infants and young children presenting with otherwise-unexplained stridor. Double aortic arch should be included in the clinical differential diagnosis of laryngo-tracheomalacia and neglected foreign body aspiration [1].

Neonates may present with postural neck enlargement, and occasionally they may reflectively withhold breathing during feeds. Sometimes a typical sign may be noticed when neonates reflectively elongate their neck in order to lessen the compression of the trachea [11,16].

It is worth mentioning that children which are breastfed or artificially fed may not experience any swallowing difficulties, despite the level of tightness of the VR until they will start complimentary feeding [11,16].

However, some neonates may experience life-threatening symptoms of respiratory distress and stop of breathing; in children with severe VR compression and tracheomalacia severe respiratory distress may develop, which will require intubation and artificial breathing support following urgent surgical correction [11,27].

It is surely worth mentioning, that there are a lot of diagnostic mistakes associated with the diagnosis of the VR, as its clinical symptoms are typical for many other diseases with much higher frequency: asthma, respiratory tract development anomalies and gastroesophageal reflux.

There is a number of published clinical cases with wrongful diagnosis of resistant to treatment bronchial asthma, which was treated for couple of

years with bronchodilators, corticosteroids and antileukotriene medications with a late diagnosis of VR.

The clinical case of VR masquerading as bronchial asthma is depicted by Q. Zhang and his colleagues in their clinical paper «Recurrent Wheezing and Cough Caused by Double Aortic Arch, Not Asthma». Authors described a clinical case of 4-year-old boy with a history of recurrent wheezing, who was admitted to the hospital due to the history of bronchial asthma, persistent cough, wheezing and airway hyperresponsiveness. After CT angiogram was performed, which confirmed double aortic arch. Following surgical correction led to significant relief of respiratory symptoms. Authors conclude that timely diagnosis and surgical correction of VR prevent chronic, irreversible respiratory complications [16].

Detailed assessment of history of life allows physicians to reveal such complaints as stridor that reminded croup back in early childhood, frequent episodes of bronchial obstruction and the use of inhalators with bronchodilators, and other respiratory complaints, which were never qualified as a certain respiratory disease [11,16,28].

Additionally, parents of older children with VR often complain that it takes too long for their children to chew their food and are always the last ones to leave the dining table during pediatrician's appointments.

Therefore, the diagnosis of VR should be taken into consideration in differential diagnosis with asthma or gastroesophageal reflux, which do not respond to treatment.

Although VR are a congenital pathology, some children with VR may become symptomatic even in adulthood. There is a number of clinical cases depicted in the literature.

M. Fernandez—Valls et al. described clinical case of VR in a 62-year-old woman, who presented with dysphagia due to the double aortic arch [8]. In the same time N. Ochi et al. presented clinical case of the double aortic arch and aberrant right subclavian artery in a 56-year-old man, who suffered from epigastric pain and lost more than 10% of his weight during the period of 6 month. Diagnosis was completed after CT scan [14].

Many researchers describe association between anatomic types of VR and most typical symptoms. Some of them point out that children with double aortic arch most frequently present with respiratory symptoms [25], whereas patients with aberrant subclavian artery to the contrary present more fre-

quently with the problems of the digestive system, as a result of its compression from its back side [12].

However, we agree more with M. Kir et al., who states that there is really no connection between the type of VR and the development of specific symptoms. All of the above mentioned symptoms only determine the suspicion of the VR and necessity of further evaluation [9].

Computed tomography serves as the most effective diagnostic modality of VR [26].

Most of the patients demand surgical correction, children with double aortic arch usually require it much sooner, around 1.4 months after the presentation and 4.9 months after symptoms begin to occur. The site of the surgical correction depends on the non-dominant arch, which is generally left-sided in nearly 71% of the patients. Therefore, lateral thoracotomy via the left side is usually performed [2].

Afterwards the small arch is ligated and divided with further ligation and division of the ductus arteriosus or ligament arteriosus, followed by complete mobilization of the trachea and esophagus [24]. In children with a Kommerell diverticulum resection of the diverticulum and reimplantation of the left subclavian artery, end to side, with the left common carotid artery will be performed [3].

Prognosis of VR repair is excellent with about 26 of 300 patients needing reoperation [4]. Most of the surgeons report no early or late mortality in their papers, only several reported only one death [7,18,20].

Conclusions

Congenital VR are a rare finding in the practice of a pediatrician and a family physician, therefore the level of suspicion of the diagnosis is relatively low.

Nevertheless, taking the severe complications of this pathology into account, VR should be included in the list of differential diagnosis, when evaluating children who present with wheezing, stridor, difficulty swallowing and bronchial obstruction in children, especially if the symptoms are present and persist since birth and are not responsive to treatment.

It is important for family physicians, who refer their patient to pediatric cardiologist or ultrasound technician to specify their concern in terms of VR, and the need to specifically scan aortic arch and its vessels as not all ultrasound technicians include this into their Echo protocol.

Computed tomography scan and 3D reconstruction is an important diagnostic tool in case of suspicion of VR, and will provide full visualization of the vessels, trachea, esophagus and

lungs and will help to determine further surgical correction.

No conflict of interests was declared by the authors.

REFERENCES/ЛІТЕРАТУРА

- Aladham Y, Bonduelle Q, Yaro J, Ahmed O. (2021, Dec 24). Double aortic arch: a rare cause of stridor in infants. *J Surg Case Rep.* 12: rjab567. doi: 10.1093/jscr/rjab567. PMID: 34987759; PMCID: PMC8711860.
- Alsenaidi K, Gurofsky R, Karamlou T, Williams WG, McCrindle BW. (2006, Nov). Management and outcomes of double aortic arch in 81 patients. *Pediatrics.* 118 (5): e1336–1341.
- Backer CL, Mongé MC, Popescu AR, Eltayeb OM, Rastatter JC, Rigsby CK. (2016, Jun). Vascular rings. *Semin Pediatr Surg.* 25 (3): 165–175. Epub 2016 Feb 22. doi: 10.1053/j.sempedsurg.2016.02.009. PMID: 27301603.
- Backer CL, Mongé MC, Russell HM, Popescu AR, Rastatter JC, Costello JM. (2014). Reoperation after vascular ring repair. *Semin Thorac Cardiovasc Surg Pediatr Card Surg Annu.* 17 (1): 48–55.
- Bhatt TC, Muralidharan CG, Singh G, Jain NK. (2016, Dec). Kommerell's diverticulum: A rare aortic arch anomaly. *Med J Armed Forces India.* 72 (1): S80–S83. Epub 2016 Oct 27. doi: 10.1016/j.mjafi.2016.09.003. PMID: 28050078; PMCID: PMC5192231.
- Das S, Nair VV, Airan B. (2015, Jan-Mar). Double aortic arch as a source of airway obstruction in a child. *Ann Card Anaesth.* 18 (1): 111–112. doi: 10.4103/0971-9784.148336. PMID: 25566726; PMCID: PMC4900311.
- Dodge-Khatami A. (2021). Commentary: If You Know About It, Why Not Just Fix It? Planning Surgical Repair on Asymptomatic Patients With Vascular Rings in the New Era of Prenatal Diagnosis. *Semin Thorac Cardiovasc Surg.* 33 (2): 503–504. Epub 2020 Nov 7. doi: 10.1053/j.semtcvs.2020.10.009. PMID: 33171232.
- Fernandez-Valls M, Arnaiz J, Lui D et al. (2012, Sep). Double Aortic Arch Presents With Dysphagia as Initial Symptom. *J Am Coll Cardiol.* 60 (12): 1114.
- Kir M, Saylam GS, Karadas U et al. (2012, Apr). Vascular rings: presentation, imaging strategies, treatment, and outcome. *Pediatr Cardiol.* 33 (4): 607–617. doi: 10.1007/s00246-012-0187-x.
- Lee M, Landsem L. (2022, Jan). Pulmonary Artery Sling. Updated 2022 Sep 19. *StatPearls.* Treasure Island (FL): StatPearls Publishing. URL: <https://www.ncbi.nlm.nih.gov/books/NBK562199/>.
- Licari A, Manca E, Rispoli GA et al. (2015). Congenital Vascular Rings: A Clinical Challenge for the Pediatrician. *Pediatric Pulmonology.* 50: 511–524. doi: 10.1002/ppul.23152.
- Mahmodlou R, Sepehrvand N, Hatami S. (2014, Jul-Dec). Aberrant Right Subclavian Artery: A Life-threatening Anomaly that should be considered during Esophagectomy. *J Surg Tech Case Rep.* 6 (2): 61–63. doi: 10.4103/2006-8808.147262. PMID: 25598945; PMCID: PMC4290042.
- Nguyen LT, Fleishman R, Flynn E. (2017, Feb 11). 22q11.2 microduplication syndrome with associated esophageal atresia/tracheo-esophageal fistula and vascular ring. *Clin Case Rep.* 5 (3): 351–356. doi: 10.1002/ccr3.815.
- Ochi N, Yasugi M, Takigawa N et al. (2012). Asymptomatic double aortic arch with compressed oesophagus in an adult. *Case Reports.* BMJ: 4. doi: 10.1136/bcr.12.2011.5315.
- Powell AJ, Mandell VS. (2006). Vascular rings and slings. In: *Nadas' Pediatric Cardiology.* 2nd ed. Keane JF, Fyler DC, Lock JE, Teele S (Eds). Elsevier: 811.
- Qiao Zhang, Zhou Fu, Jihong Dai et al. (2017). Tian Recurrent Wheezing and Cough Caused by Double Aortic Arch, Not Asthma. *Case Rep Cardiol.* 8079851. doi: 10.1155/2017/8079851.
- Sahni D, Franklin WH. (2022, Jan). Vascular Ring Double Aortic Arch. *Treasure Island (FL): StatPearls Publishing.* PMID: 32644364.
- Said SM, Marey G, Knutson S, Rodgers N, Richtsfeld M, Joy B, Griselli M. (2021). Outcomes of Surgical Repair of Vascular Rings and Slings in Children: A Word for the Asymptomatic. *Semin Thorac Cardiovasc Surg.* 33 (2): 492–500. Epub 2020 Sep 23. doi: 10.1053/j.semtcvs.2020.09.013. PMID: 32977012.
- Santos N, Almeida T, Janeiro MC et al. (2020). Pulmonary artery sling: a rare cause of stridor and respiratory distress. *BMJ Case Reports CP.* 13: e233793.
- Schmidt AMS, Larsen SH, Hjortdal VE. (2018, Oct). Vascular ring: Early and long-term mortality and morbidity after surgical repair. *J Pediatr Surg.* 53 (10): 1976–1979.
- Tamayo-Espinosa T, Erdmenger-Orellana J, Becerra-Becerra R, Balderrabano-Saucedo N, Segura-Standford B. (2017, Oct-Dec). Right-side aortic arch with aberrant left subclavian artery and Kommerell's diverticulum. A cause of vascular ring. *Arch Cardiol Mex.* 87 (4): 345–348. Epub 2017 Jul 29. doi: 10.1016/j.acmx.2017.03.006. PMID: 28625795.
- Tammo R, Yalynskaia TA, Rokytskaia NV y dr. (2010). Vrozhdenne sosudystye koltsa. Promeneva diahnozytyka, promeneva terapiia. 2: 76–82. [Таммо Р, Ялынська ТА, Рокицька НВ і др. (2010). Врожденні судисті кільця. Променева діагностика, променева терапія. 2: 76–82].
- Van Rosendaal PJ, Stöger JL, Kiès P, Vliegen HW, Hazekamp MG, Koolbergen DR et al. (2021, Feb 26). The Clinical Spectrum of Kommerell's Diverticulum in Adults with a Right-Sided Aortic Arch: A Case Series and Literature Overview. *J Cardiovasc Dev Dis.* 8 (3): 25. doi: 10.3390/jcdd8030025. PMID: 33652796; PMCID: PMC7996811.
- Wychulis AR, Kincaid OW, Weidman WH, Danielson GK. (1971, Mar). Congenital vascular ring: surgical considerations and results of operation. *Mayo Clin Proc.* 46 (3): 182–188.
- Yang X, Ye J, Gao Z. (2017, Oct). Double aortic arch presenting with a foreign object in the oesophagus: a case report and imaging diagnosis. *Cardiol Young.* 27 (8): 1651–1653.
- Yoshimura N, Fukahara K, Yamashita A, Doi T, Yamashita S, Homma T et al. (2020, Oct). Congenital vascular ring. *Surg Today.* 50 (10): 1151–1158. Epub 2019 Nov 1. doi: 10.1007/s00595-019-01907-5. PMID: 31676999.
- Yu D, Guo Z, You X et al. (2022). Long-term outcomes in children undergoing vascular ring division: a multi-institution experience. *Eur J Cardiothorac Surg.* 61: 605.
- Zynkovskiy MF. (2009). Vrozhdenne poroky serdtsa. Red. akad. A.F. Vozyanova. Kyev: Knyha Plus: 1170. [Зиньковський МФ. (2009). Врожденні пороки серця. Ред. akad. А.Ф. Возианова. Киев: Книга Плюс: 1170].

Відомості про авторів:

Зборовська Ольга Олександрівна — к.мед.н., асистент каф. педіатрії №2 Вінницького НМУ імені М.І. Пирогова. Адреса: м. Вінниця, вул. М. Пирогова 56А; тел. +38 (0432) 570-360. <https://orcid.org/0000-0003-0723-6131>.

Мальська Андріана Андріївна — к.мед.н., доц. каф. пропедевтики педіатрії та медичної генетики Львівського НМУ імені Д. Галицького. Адреса: м. Львів, вул. М. Лисенка, 31а; тел. +38 (032) 260-01-88. <https://orcid.org/0000-0003-3484-153X>.

Таммо Раад — к.мед.н., лікар рентгенолог відділення променевої діагностики ДУ «Науково практичний медичний центр дитячої кардіології та кардіохірургії МОЗ України». Адреса: м. Київ, вул. Чорновола, 28/1; тел. +38 (044) 238-78-07. <https://orcid.org/0000-0001-7506-9449>.

Тетерін Олександр Володимирович — лікар кардіо-ревматолог дитячий відділення функціональної та ультразвукової діагностики ДУ «Науково практичний медичний центр дитячої кардіології та кардіохірургії МОЗ України». Адреса: м. Київ, вул. Чорновола, 28/1; тел. +38 (044) 238-78-07. <https://orcid.org/0000-0002-9094-5002>.

Морковкіна Ганна Євгенівна — лікар рентгенолог відділення променевої діагностики ДУ «Науково практичний медичний центр дитячої кардіології та кардіохірургії МОЗ України». Адреса: м. Київ, вул. Чорновола, 28/1; тел. +38 (044) 238-78-07. <https://orcid.org/0000-0001-6457-0836>.

Стаття надійшла до редакції 02.12.2022 р., прийнята до друку 13.03.2023 р.