

## ORIGINAL ARTICLE

# MODERN ASPECTS OF TRAUMATIC PULPITIS TREATMENT WITH THE USE OF BIO CERAMICS

DOI: 10.36740/WLek202106110

**Nataliia G. Gadzhula, Irina M. Horlenko, Maryna A. Goray, Anastasiia M. Kvirikashvili**

NATIONAL PIROGOV MEMORIAL MEDICAL UNIVERSITY, VINNYTSIA, UKRAINE

**ABSTRACT**

**The aim:** The research was to evaluate the effectiveness of acute traumatic pulpitis treatment with the use of bioceramics according to the results of a clinical study.

**Materials and methods:** Acute traumatic pulpitis of 25 teeth in 25 patients aged 18-25 years were treated by biological direct pulp capping. In 13 patients of the main group, bioceramics was placed on the exposed pulp, and in 12 patients of the control group, calcium hydroxide paste was applied on the exposed pulp. Treatment effectiveness was evaluated according to the following criteria: the absence of clinical signs of pulpal inflammation, on X-ray – signs of dentinal bridge formation, the absence of periapical changes.

**Results:** The use of bioceramic material in patients of the main group provided a positive dynamic of treatment in 12 teeth. The need for re-treatment was diagnosed only in 1 clinical case (7.7%), in the control group – in 4 cases (33.3%).

**Conclusions:** Pulpitis treatment with the use of bioceramics provides preserving the functional properties of pulp, creation of a calcified barrier – dentin bridge and prevents the periodontal complications compared to the pulp capping with a material based on calcium hydroxide. The effectiveness of treatment in the main group was 92.3%, in the control – 66.7%.

**KEY WORDS:** traumatic pulpitis, pulp capping, bioceramics, calcium hydroxide

Wiad Lek. 2021;74(6):1341-1345

**INTRODUCTION**

It is known that inflammation of the dental pulp is a dynamic process that passes from one stage to another and ends with its repair or necrosis. The expediency of treatment of reversible pulpitis with a conservative method in the initial stages of the pathological process is based on the unique ability of the pulp to regenerate with the use of materials that stimulate the reparative functions of odontoblasts and create an aseptic environment in the pulp cavity [1, 2]. Traumatic opening of the pulp chamber leads to microbial pulp contamination, and, accordingly, to pulpal inflammation [3]. Reparative processes directly depend on the material for pulp capping. Most pastes have a unidirectional effect and are used either to remineralize dentin or to eliminate the initial stages of inflammation, and only some of them are able to multifactorially affect both the structure of dentin and pulp components [4, 5].

From the above it follows that the success of treatment is achieved by exposure for pulp tissues with materials which have bactericidal properties and stimulate the reparative functions of odontoblasts (the volume and quality of new dentine is dependent on the material applied) [1, 2, 6]. One of the first bioactive materials was calcium hydroxide. Some authors critically evaluate the quality of mineralized (calcified) barrier formed after the use of calcium hydroxide. This is explained by the resorption of the material in a humid environment, reduced efficiency in contact with

air due to partial carbonization, the emergence of tunnel defects in the formed dentin, which is permeable to microbial toxins [1, 4, 6, 7].

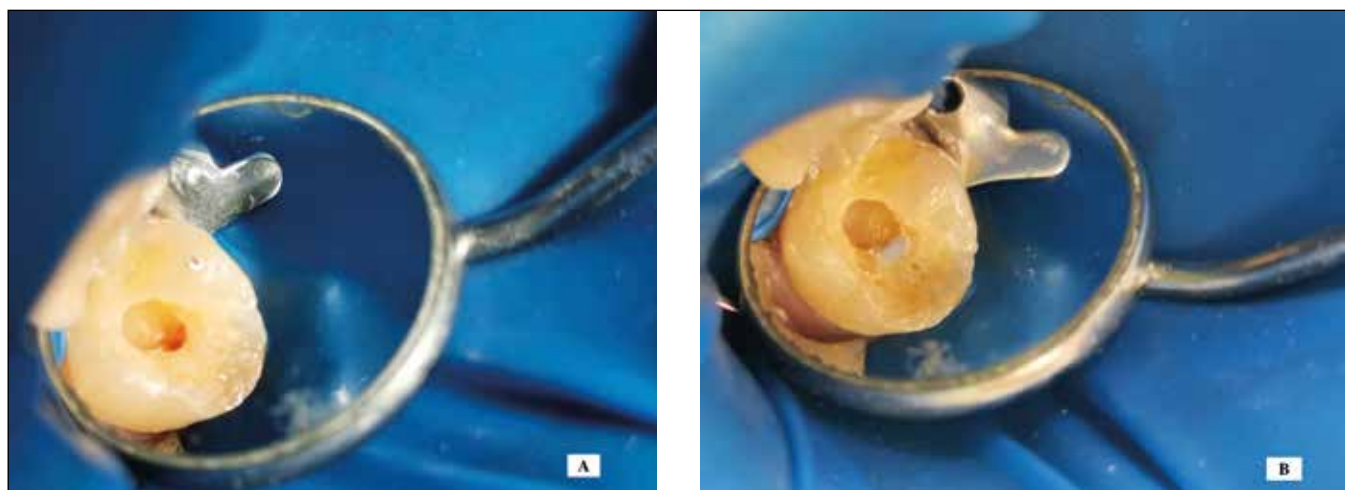
That is why we have chosen a bioceramic material based on calcium silicate, monobasic calcium phosphate, zirconium oxide, calcium hydroxide, tantalum oxide. The material has a pronounced reparative potential, antibacterial effect (pH=12.4), chemically stable in the biological environment, hydrophilic, non-shrinkable, non-toxic, it demonstrates a high biocompatibility, bioactivity and high strength [5, 8, 9, 10, 11, 12].

**THE AIM**

The aim of the research was to evaluate the effectiveness of treatment of acute traumatic pulpitis with the use of bioceramic material according to the results of a clinical study.

**MATERIALS AND METHODS**

Treatment of 25 teeth with acute traumatic pulpitis in 25 patients aged 18-25 years was carried out. Teeth were treated by biological method of direct pulp capping terms up to 12 hours. The treatment algorithm included the following stages: anaesthesia, rubber dam isolation, visual assessment of a clinical pulpal status (size of perforation does not exceed 3 mm, dentin around the exposed pulp is



**Fig. 1.** a. Acute traumatic pulpitis of 2.6 tooth\_ clinical image showing of exposed pulp; b. Clinical view of pulp capping with bioceramics of 2.6 tooth

intact) (Fig. 1a), antiseptic treatment with a 0.05% chlorhexidine solution, direct pulp capping (Fig. 1b), filling of a carious cavity [4].

In 13 patients of the main group, on the exposed pulp was placed EndoSequence Bioceramic Root Repair Material (Brasseler USA), in 12 patients of the control group on the exposed pulp the calcium hydroxide paste Dycal (Dentsply) was applied. The material was isolated with a glass ionomer cement Vitremer (3M ESPE). Restoration of an anatomical tooth shape with a light-cured material was done in cases of positive dynamics of treatment in 4 weeks.

The assessment of inflammatory state of the pulp and surrounding tissues was performed according to the subjective feelings of patients, the results of clinical examination methods, thermal test, electric pulp test (EPT) and X-ray. Patients' examinations were carried out in 1 month, 6 months and 1 year. The effectiveness of the treatment was evaluated by the following criteria: no clinical signs of pulpal inflammation, on the X-ray images – signs of dentinal bridge formation, no periapical changes. The analysis of statistical data was performed using the method of the Student parametric criterion according to the principle of variation statistics. Values of  $p < 0.05$  were considered statistically significant [13].

Biomedical Ethics Commission of Pirogov National Memorial Medical University of Ministry of Health of Ukraine (Vinnytsia), having examined the data of the materials and research methods and the materials submitted by the researchers (observation dental cards of the patients, research results, informed consent forms of patients), established that the study was carried out in compliance with the basic provisions of the GCP (1996), Council of Europe Convention on Human Rights and Biomedicine (04.04.1997), World Health Association's Helsinki Declaration on Ethical Principles for Scientific Research with Human Participation (1964-2000) and the Ministry of Health of Ukraine Order No 281 dated 01.11.2000. Based on this, the commission concluded that the proposed study has no biomedical prohibitions and restrictions, and is recommended for publication.

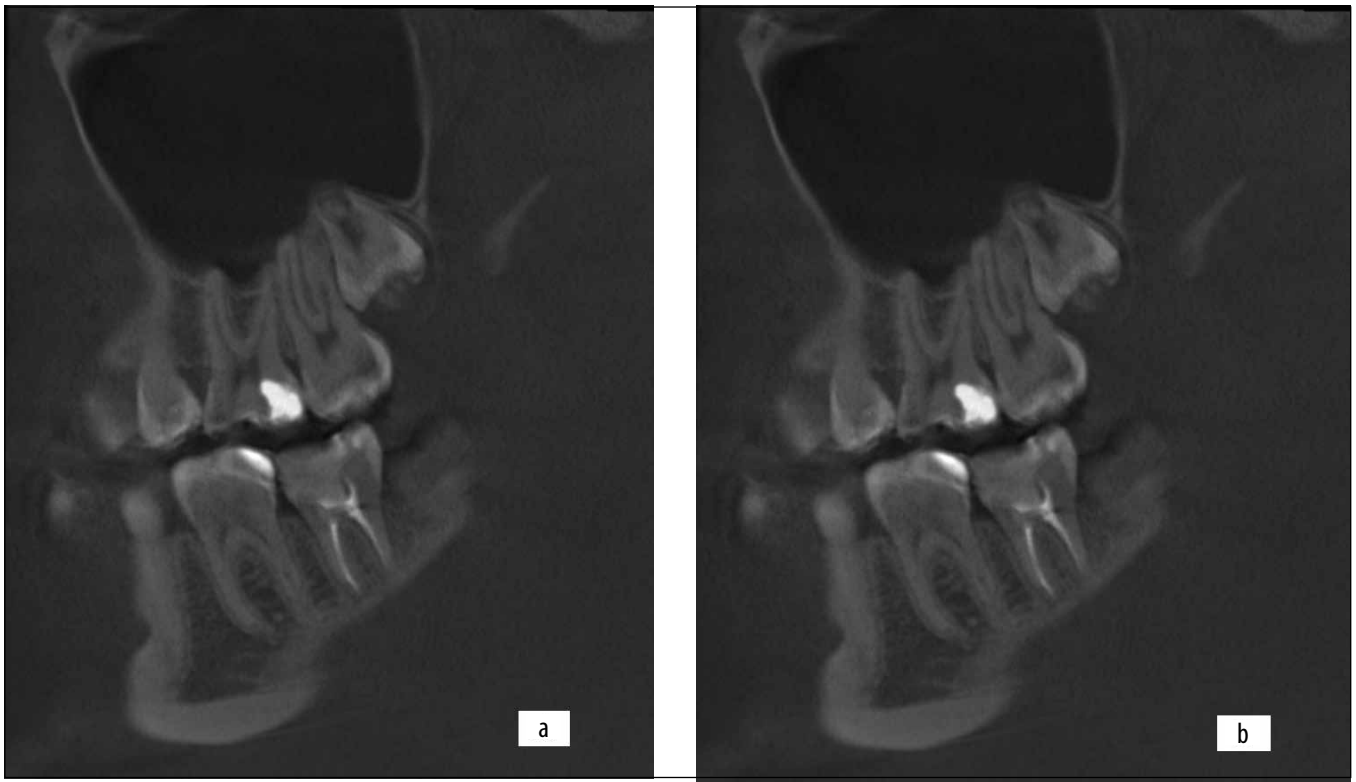
## RESULTS

In a month of treatment, the patients of the main group did not have any complaints. The teeth reaction to temperature stimuli and percussion was negative, radiographically no changes in periapical tissues were revealed. Among 12 patients of the control group the 2 complications in the forms of irreversible pulpitis were diagnosed. Occurrence of painful sensation from thermal stimuli was combined with spontaneous pain attacks of moderate intensity, alternating with painless intervals. EPT values were between 28 and 38  $\mu\text{A}$ , percussion was negative, changes in periapical tissues were not revealed. Treatment of the teeth was continued with a vital pulp extirpation method.

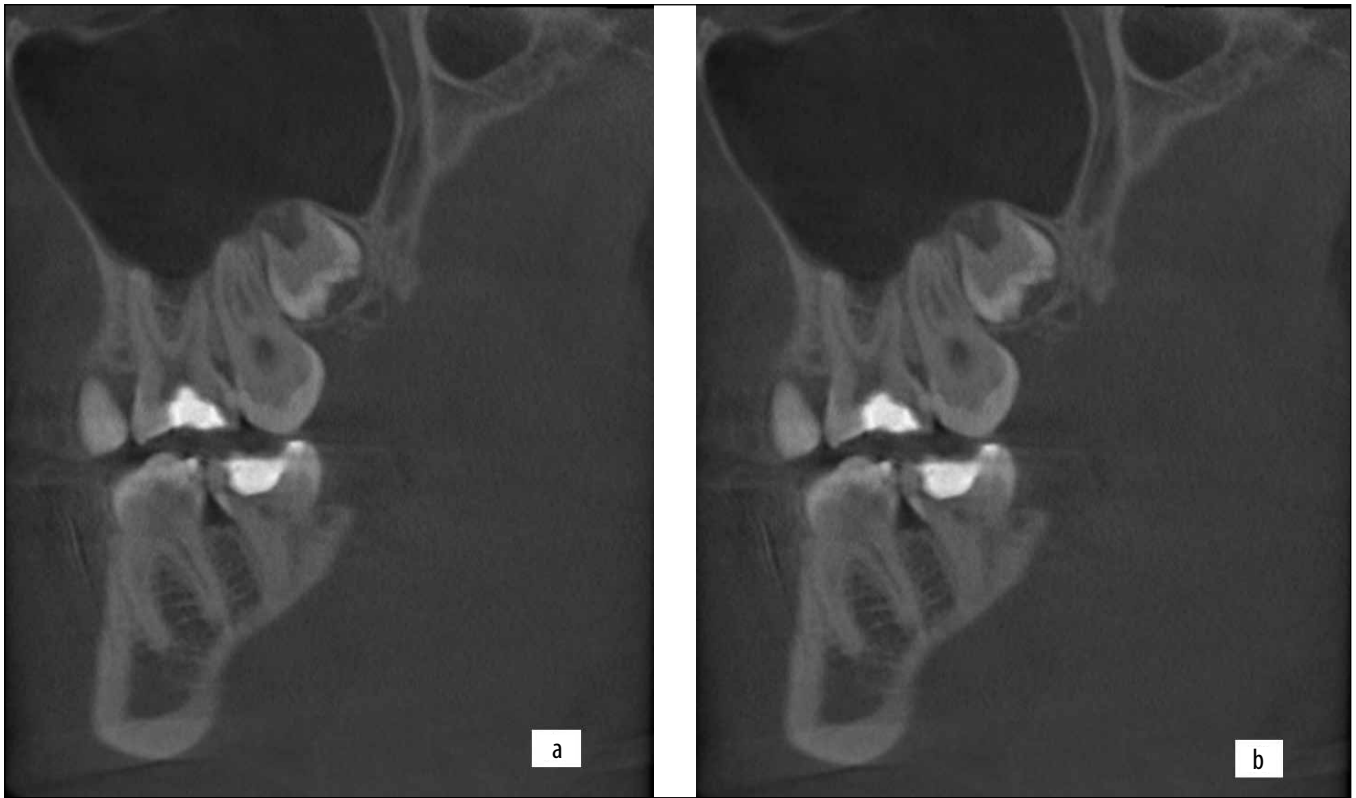In 6 months among 13 patients of the main group, a clinical well-being was not observed in one patient with initial value of EPT about 15  $\mu\text{A}$ . In this case, an increase of EPT values to 35  $\mu\text{A}$  was revealed. Pulp extirpation was performed in this tooth. The pulpal status of other teeth was characterized by the low values of EPT between  $5.44 \pm 0.42 \mu\text{A}$  and  $7.39 \pm 0.64 \mu\text{A}$ , clinical symptoms of spontaneous pain and reaction to thermal stimuli were not observed. On the X-ray images in all cases of treated teeth a tight fit of bioceramic material in the contact area with the pulp and the formation of a dentinal bridge were identified.

In the control group, six months after the treatment of teeth with a biological method, in 1 patient the pain attacks of moderate intensity, lasting up to 20 minutes were appeared. Values of EPT were 45  $\mu\text{A}$ , no changes in periapical tissues were revealed. The tooth was treated endodontically.

In 12-month of follow-up examination, the number of favorable cases in the main group of patients did not change, clinical and subjective parameters in 12 patients proved the complete success of the treatment. During objective clinical examination, the absence of marginal defects of filling materials, no signs of inflammation of the surrounding mucosa have been observed. Thermal testing and percussion were painless, values of EPT did not exceed the values of electrical excitability of normal pulp tissue. Radiographically, there were no changes in the periapical



**Fig. 2.** a. Postoperative radiograph image of 1.6 tooth after the pulp capping with a bioceramics in a month; b. Recall radiograph in a year of 1.6 tooth after pulp capping with a bioceramics



**Fig. 3.** a. Postoperative radiograph image of 2.6 tooth after the pulp capping with a calcium hydroxide in a month; b. Recall radiograph in a year of 2.6 tooth

tissues. In the period from 6 to 12 months in all clinical cases the formation of a dentinal bridge and complete repairing of dentin structure were identified (Fig. 2).

In a year of dynamic examination of the control group in 1 patient a chronic apical periodontitis was diagnosed, confirmed radiographically. Tooth treatment was contin-

ued endodontically. The values of EPT of other teeth did not exceed  $9.12 \pm 0.86 \mu\text{A}$ , thermal testing and percussion of the teeth were painless. Comparing the radiographic results of both groups it should be noted that in the patients of control group a non-complete repair of dentin structure was revealed (Fig. 3). This indicates a delayed formation of a layer of reparative dentin as result action of calcium-containing paste Dycal.

## DISCUSSION

Based on the clinical study, it was found that the use of bioceramic material containing calcium silicate, calcium phosphate, zirconium oxide, calcium hydroxide and tantalum oxide in patients of the main group provided the positive dynamics of treatment in 92.3% of cases (12 teeth). The need for re-treatment was diagnosed only in 1 clinical case within 6 months of follow-up. The use of bioceramics for direct pulp capping assisted (promoted) the absence of inflammation in the soft tooth tissues due to the antibacterial properties of the material (pH = 12.4), which is clinically confirmed by the low frequency of complications after treatment.

Clinical examination of patients of the control group in the long-term follow-up after applying the calcium hydroxide paste showed the absence of positive post-therapeutic dynamics in 2 cases within 1-3 months; in 1 case within 3-6 months; in the interval between 6-12 months in 1 patient the development of chronic apical periodontitis was revealed. Thus, the identified complications that led to a change in further treatment tactics were 4 cases (33.3%). A positive effect was achieved in 66.7% of patients (8 teeth).

X-ray analysis of reparative dentinogenesis in the main group of patients was as follows: in a month of pulpitis treatment with a biological method in all cases a tight fit of bioceramic material in the contact area with the pulp were identified, no fissured spaces were observed; the formation of the dentinal bridge was clearly revealed (Fig. 2a).

In the period from 6 to 12 months in all clinical cases of the main group of patients the formation of a dense and wide layer of reparative dentin was observed (Fig. 2b). The results are consistent with numerous studies [7, 8, 10] showed that the material, in addition to hermetic properties, has a high degree of biocompatibility with tooth tissue, tolerant to moisture and able to activate the synthetic activity of cells that produce mineralized tissues. In addition, the material has low cytotoxicity, does not damage pulp cells *in vivo* and stimulates the formation of tertiary dentin on the 7<sup>th</sup> day after treatment [5, 10].

In patients of the control group in a month of pulpitis treatment on radiographs the signs of dentinal bridge formation were revealed (Fig. 3a), in 6-12 months non-completed repairing of dentin structure was noted, indicating delayed formation of the reparative dentin layer under the action of calcium hydroxide paste (Fig. 3b).

Thus, the differences in the intensity and terms of the formation of replacement dentin under the action of bioceramics and calcium hydroxide are clearly differen-

tiated. It should be noted that a rapid restructuring of suprapulpal dentin layers, a denser and wider dentinal layer was formed after applying of bioceramic material. This indicates the shortened terms of dentinogenesis under the use of bioceramics, the ability of the material to stimulate the repairing of cellular pulp elements and activate their functional properties. The results are consistent with the literature data, which states that bioceramics stimulates the dentinal bridges formation, protecting the exposed pulp more effectively than calcium hydroxide [4, 8, 10, 11]. Bioceramic cement stimulates differentiation of pulp cells to odontoblasts/odontoblast-like cells, seals the perforation site completely, is antimicrobial, and has sufficient mechanical strength including hardness, compressive strength, and flexural modulus [4, 5, 8, 9, 10].

## CONCLUSIONS

Thus, the biological method of pulpitis treatment using bioceramics contributes to the preservation the anatomical and functional properties of the pulp and prevents the periodontal complications compared to the pulp capping with a material based on calcium hydroxide. Success of treatment with bioceramics was achieved through the creation of a sufficient volume of calcified barrier – the dentin bridge, under which a pulp was preserved. The effectiveness of treatment in the main group was 92.3%, in the comparative – 66.7%.

The obtained results reveal new possibilities of application of bioceramic materials not only in surgical, but also in conservative endodontics.

## REFERENCES

1. Ghoddsi J., Forghani M., Parisay I. New approaches in vital pulp therapy in permanent teeth. *Iran Endod J.* 2014;9(1):15-22.
2. Kovach I., Buniatian K., Makarevych A. et al. Influence of Tricalcium silicate on course of traumatic pulpitis. *Georgian medical news.* 2018;276(3):130-135.
3. Trufanova V.P., Sheshukova O.V., Lyakhova N.A. et al. Determination of the structure of acute injury of temporary and permanent frontal teeth in children, analysis of diagnostic and treatment measures and their effects. *Wiad Lek.* 2020;73(4):737-742. doi: 10.36740/WLek202004121.
4. Cao Y., Bogen G., Lim J. et al. Bioceramic Materials and the Changing Concepts in Vital Pulp Therapy. *Journal of the California Dental Association.* 2016;44(5):278-290.
5. Machado J., Johnson J.D., Paranjpe A. The Effects of Endosequence Root Repair Material on Differentiation of Dental Pulp Cells. *J Endod.* 2016; 42(1):101-105. doi: 10.1016/j.joen.2015.08.007.
6. Butvilovskij A.V., Manak T.N., Volodkevich D.L., Said O.A. Konservativnoe endodonticheskoe lechenie: sovremennye principy i metody [Conservative endodontic treatment: modern principles and methods]. *Sovremennaya stomatologiya.* 2018;2:30-33. (in Russian).
7. Gadzhula N.G. Clinical effectiveness of treatment the patients with chronic apical periodontitis. *International Journal of Medicine and Medical Research.* 2016;2(2):30-33. doi: <https://doi.org/10.11603/IJMMR.2413-6077.2016.2.7037>.
8. Assadian H., Moghaddam E.H., Amini A. et al. Review of Endodontic Bioceramics. *J Islam Dent Assoc Iran.* 2016;28(1):20-33.

9. Guo Ya-juan., Du Tian-feng, Li Hong-bo. et al. Physical properties and hydration behavior of a fast-setting bioceramic endodontic material. *BMC Oral Health*. 2016;16(1):1-6. doi: <https://doi.org/10.1186/s12903-016-0184-1>.
10. Iliescu A.A., Tulus G., Perlea P. et al. Bioceramics and endodontics: present and expectations in clinical use. *Defect and Diffusion Forum*. 2017;376:29-38.
11. Staniowski T., Brzęcka D.M. Novel Bioceramic Root Repair Material: Review of the Literature. *Dent. Med. Probl*. 2016;53(4):551-558. doi: <https://doi.org/10.17219/dmp/63945>.
12. Wang Z. Bioceramic materials in endodontics. *Endodontic Topics*. 2015;32(1):3-30. <https://doi.org/10.1111/etp.12075>.
13. Antomonov M.Yu. *Matematicheskaya obrabotka i analiz mediko-biologicheskikh dannykh [Mathematical processing and analysis of biomedical data]*. 2-e izd. Kyiv: Medinform; 2018. p. 579. (in Russian).

*The work is a fragment of the research project “Modern trends and latest technologies in the diagnosis and treatment of odontopathology, diseases of periodontal tissues and oral mucosa”, state registration № 0118U005471.*

#### **ORCID and contributionship:**

Nataliia G. Gadzhula: 0000-0003-0016-2264 <sup>A, B, D, E</sup>

Irina M. Horlenko: 0000-0001-8174-9651 <sup>B, F</sup>

Maryna A. Goray: 0000-0003-4454-9161 <sup>B, C</sup>

Anastasiia M. Kvirikashvili: 0000-0002-7917-3590 <sup>A, D</sup>

#### **Conflict of interest:**

*The Authors declare no conflict of interest.*

---

#### **CORRESPONDING AUTHOR**

##### **Nataliia G. Gadzhula**

National Pirogov Memorial Medical University

56 Pyrohov Str., 21018 Vinnytsia, Ukraine

tel: +380977011918

e-mail: gadzhula@vnmu.edu.ua

**Received:** 11.10.2020

**Accepted:** 26.04.2021

---

A - Work concept and design, B – Data collection and analysis, C – Responsibility for statistical analysis, D – Writing the article, E – Critical review, F – Final approval of the article