

UDC 616.31:577.112.386/164.184/161.2:612.1:599.323.4

INDICATORS OF MINERAL METABOLISM AND DENTAL STATUS OF YOUNG RATS BORN FROM FEMALE WITH METHIONINE-INDUCED HYPERHOMOCYSTEINEMIA

O. KUTELMAKH¹✉, R. LESYK^{2,3}, Yu. CHUMAKOVA⁴,
S. BONDAR¹, V. DRONENKO¹, L. SHKILNIAK¹

¹Vinnytsia National Pirogov Memorial Medical University, Vinnytsya, Ukraine;

²Danylo Halytsky Lviv National Medical University, Lviv, Ukraine;

³University of Information Technology and Management in Rzeszow, Rzeszow, Poland;

⁴International Humanitarian University, Odessa, Ukraine;

✉ e-mail: ahzelo1968vin@i.ua

Received: 12 July 2021; **Accepted:** 12 November 2021

We assume that the violation of homocysteine (Hcy) metabolism and vitamin D level in mothers' utero causes various abnormalities in offspring, including hard-woven teeth and periodontium impairments. The aim of this study was to evaluate the biochemical parameters of blood and alveolar bone homogenates and assess dental status of offspring born from female rats under long-term methionine hyperhomocysteinemia (HHcy). Clinical, biochemical and morphometric studies were performed on 30 female rats and 281 infantile and early juvenile rats. Serum Hcy levels were determined by competitive immunoassay with electrochemiluminescent detection, 25-hydroxyvitamin D (25OHD) level was estimated by ELISA. No violation of Hcy serum level was found in rats born from females with long-term methionine-induced hyperhomocysteinemia. Hyperhomocysteinemic diet caused by long-term use of methionine reduced the level of total and ionized calcium and phosphates in the blood of pregnant females and their offspring. Elevated levels of homocysteine and decreased vitamin D levels in pregnant females caused a delay in the complete physiological eruption of permanent molars in their offspring. Biochemical changes in the blood, jawbones and the presence of early carious processes in the teeth of young rats, in our opinion, are the result of metabolic disorders in utero caused by hyperhomocysteinemia and vitamin D deficiency in their mothers.

Key words: methionine-induced hyperhomocysteinemia, homocysteine, vitamin D, choline, dental status, tooth eruption.

According to recent studies, hyperhomocysteinemia [1] and vitamin D deficiency [2, 3], individually and in association, play a crucial role in developing pregnancy complications in mothers and offspring [4]. However, data on the possible synergism of these causal factors are not fully established. The hyperhomocysteinemia in pregnant women causes a decreasing number of newborns, the birth of infants with low body weight, and further decreasing the body weight gain [5]. Other defects in the development of the fetus and pathology of pregnant mothers with hyperhomocysteinemia are evidenced by numerous investigations in the field of obstetrics and gynecology.

We assume that the violation of the metabolism of Hcy and vitamin D in the mother causes various abnormalities in their offspring, which increases the risk of developmental defects, structural and functional disorders in the postnatal period, including hard woven teeth and impairments in periodontium, which are tissue derivatives of the cutaneous ectoderm of the embryo.

The aim of this work was to evaluate the biochemical parameters of blood and alveolar bone homogenate and assess the dental status of offspring born from female rats, with long-term methionine hyperhomocysteinemia and after the enriching the diet with choline and vitamin D.

Materials and Methods

The two-part experiment was conducted in accordance with the current requirements for the humane treatment of experimental animals, adopted by the European Convention for the Protection of Vertebrate Animals Used for Research and Other Scientific Purposes (Strasbourg, 1986), the First National Congress of Ukraine of Bioethics (Kyiv, 2001), in compliance with the rules approved by the Committee on Bioethics of Vinnytsia National Pirogov Memorial Medical University.

The first part of the experiment was performed on adult female rats. Animals were divided into 3 groups: intact control and two experimental, 10 rats each (Table 1). Animals of all groups received a semi-synthetic starch-casein diet (basic diet), which included in physiological doses all macro- and micronutrients [6]. In the second (2) group, a methionine model of hyperhomocysteinaemia was reproduced by enriching the main diet with 1% L-methionine, ie 10 g per 1 kg of dry food [7]. In the third (3) group of animals, choline and vitamin D were added to the main diet to correct methionine hyperhomocysteinaemia [8]. Choline is a well-known agent which reduce plasma Hcy levels [9] due to an activation of the enzyme betain-gomocysteine methyltransferase, which converts Hcy to methionine. Choline was introduced into the diet in the form of a water-soluble compound – choline chloride [10] in the amount of 500 mg/kg of diet. An aqueous solution of choline chloride was added in a calculated amount ex tempore during the preparation of ready-to-eat food. Supplementation of vitamin D to the standard diet is explained by the fact that a decrease in the blood level of vitamin D was observed under the state of hyperhomocysteinaemia, as described

previously [11, 12]. Vitamin D was introduced into the diet at a dose of 0.15 mg/kg of feed. Due to the fact that hyperhomocysteinaemia may inhibit the activation of vitamin D, its active form was added to the diet in the form of a fat-soluble drug “Alpha D3-TEVA” [10], in the amount of 1 µg/kg of diet. Both forms of vitamin D were previously included in the fatty component of the diet – oil. A control group of animals (1 group) was injected intragastrically with an equivalent volume of 1% starch gel. Water is provided to the animals ad libitum.

The second part of the study was conducted on 281 rats of infantile and early juvenile period, obtained from experimental females from the previous part of the experiment. At the end of the lactation period in adult females, rats of group 2 received a methionine diet, 3 group - a methionine diet adjusted by choline and vitamin D (group 1). General characteristics of the animals by groups (duration of the experiment, number of offspring, body weight of rats at the beginning and end of the experiment) are given in Table 2. The duration of the experiment on rats of different groups was not identical, because it was calculated by the day of eruption of the last permanent molar: this parameter varied slightly in different groups. Teething was determined by visual inspection of the oral cavity of individual animals in each group, starting from day 30 of life, with an interval of 1 day, and from day 40 – daily. Before euthanasia, *in vivo*, a visual assessment of the condition of the oral mucosa was performed to determine the presence and nature of the inflammatory process. After that, the mucous membranes of the gums, tongue and cheeks were treated with Lugol's solution, and after 30-60 sec a 1% solution of toluidine blue was applied (after 10-30 sec the areas of acute inflammation turned to brown-violet color in

Table 1. The duration of the first part of the experiment in days

Groups of female rats	Stages of the first part of the experiment and their duration		
	I-st Reproduction of the hyperhomocysteinaemic model	II-nd Fertilization of female rats	III-rd Pregnancy
Control, $n = 10$	28 days	1-4 days	20-22 days
Methionine-induced hyperhomocysteinaemia, $n = 10$	28 days	1-4 days	17-19 days
Methionine-induced hyperhomocysteinaemia corrected by choline and vitamin D, $n = 10$	28 days	1-4 days	20-23 days

contrast to weakly stained areas of healthy mucous membranes). At the end of the experiment, the rats were euthanized under ether anesthesia. Blood from the heart and lower jaws were taken for research. Biochemical studies were performed in blood serum and homogenates of skeletal lower jaws [13, 14].

Serum obtained from rats of each group pooled into a single sample was analyzed. 6 exemplar were taken from each group for evaluation. Similarly, the homogenates of the lower jaws were taken for the same manner. Serum Hcy levels were determined by competitive immunoassay with electrochemiluminescent detection, and the determination of vitamin D (serum), namely 25-hydroxyvitamin D (25OHD), was performed by enzyme-linked immunosorbent assay on a solid sorbent "ELISA" (analyzer and test system "EUROIMMUN", Germany). The levels of total protein, total calcium and inorganic phosphorus were detected photometrically on an automatic biochemical analyzer, and the content of ionized calcium (Ca^{2+}) was potentiometrically detected (ion-selective electrode method) on a semi-automatic electrolyte analyzer. Determination of alkaline and acid phosphatases in the blood and homogenates of the jaws was performed according to the method [15].

Morphometric studies were performed on the skeletal right mandibles after mechanical removal

of soft tissues (with a previous one-day exposure in 5% NaOH). We used a method of computerized photo-fixation of fragments of jaws with root teeth using a digital camera (Canon EOS 700D 18-55 IS STM) and a microscope MBS-10 with a fixed distance and strict parallelism. We derived a standard ratio of monitor pixels and millimeter divisions of the caliper (SHC-II-250 0.1 cells), which was 237 px in 1 mm. The calculations were performed using the software PhotoM 1.21. In order to visually differentiate the demineralization process from alimentary pigmentation of fissures, molars removed from the wells and kept in a 10% solution of hydrogen peroxide during the day. Teeth in which the fissures remained dark were considered carious. Additionally, to confirm the presence of carious process, the examined teeth were kept in a solution of caries marker "VOCO" for 30 sec on a vibrating table (to deepen the permeability of the red dye in the area of demineralization), then they were washed and centrifuged for 1 min. Statistical processing of the results was performed for the mean values of the Student's *t*-test. The results are presented as $M \pm m$. The changes were considered statistically significant at $P < 0.05$.

Results and Discussion

As it can be seen from Table 2, in females of group 2 with hyperhomocysteinaemia the number of

Table 2. Characteristics of groups of females, duration of experiments on rats, number of born rats and their body weight ($M \pm m$)

Groups of rats	Duration of the experiment from birth (days) ($M \pm m$)	Characteristics of offspring			
		Total number of the young rats per group	Average number of young rats in females ($M \pm m$)	Primary mass, (gr., $M \pm m$)	Average final mass, (gr., $M \pm m$)
Control, $n = 10$	38-42 (39.26 \pm 1.41)	103	10.30 \pm 0.95	5.71 \pm 0.32	70.20 \pm 2.35
Methionine-induced hyperhomocysteinaemia, $n = 10$	40-45 (43.75 \pm 1.24) $P_1 < 0.05$	77	7.70 \pm 0.67 $P_1 < 0.05$	4.05 \pm 0.48 $P_1 < 0.05$	55.40 \pm 3.22 $P_1 < 0.05$
Methionine-induced hyperhomocysteinaemia corrected by choline and vitamin D, $n = 10$	36-42 (39.21 \pm 1.99) $P_1 > 0.05$ $P_2 < 0.05$	101	10.10 \pm 0.88 $P_1 > 0.05$ $P_2 < 0.05$	5.45 \pm 0.40 $P_1 > 0.05$ $P_2 < 0.05$	65.50 \pm 2.97 $P_1 > 0.05$ $P_2 < 0.05$

Note: in this and the following tables $P < 0.05$ means a probable difference between the groups, $P_{1,2}$ - digits correspond to the comparison group

offspring was statistically smaller compared to group 1 and group 3, which confirms the available data on the negative impact of hyperhomocysteinaemia on the reproductive function of females [16]. At the end of the experiment, body weight in rats of group 2 was probably ($P < 0.05$) lower than the control and animals of group 3, between which there was no statistically significant difference. The difference between the initial and final body weight in rats was in group 1 ~64.5 gr, in group 2 ~51.3 gr, in group 3 ~60 gr.

Biochemical studies showed that the level of total serum protein was 57.6 ± 3.09 gr/l in the control group, 57.2 ± 2.44 gr/l in group 2 and 58.8 ± 1.13 gr/l in 3 groups of rats. A significant difference in this parameter between groups of animals was not observed, which indicates the preservation of protein-synthesizing function of the liver and the body as a whole and the importance of protein homeostasis on the background of hyperhomocysteinaemia.

Although the level of Hcy in group 2 rats was slightly higher, it probably did not differ from the values of groups 1 and 3 (Fig. 1), in the latter it was almost the same. This can be explained by the fact that young animals have increased protein synthesis and metabolism of amino acids, including methionine and Hcy. Based on the above, it can be argued that the hyperhomocysteinaemia was absent in rats of group 2.

In group 2 of animals, the level of vitamin D probably ($P < 0.05$) decreases in comparison with groups 1 and 3. A possible reason is a change in the structure and activity of the protein part of cytochrome P450, which synthesizes the active form of vitamin D. Hyperhomocysteinemia increases the formation of reactive oxygen species and thiolactone homocysteine – substances that can oxidize and homocysteinilation of proteins and reduce their functions. Slightly higher levels of vitamin D were recorded in group 3 rats, but no significant difference with control was observed (Fig. 2).

Applied hyperhomocysteinaemic diet in pregnant females and their offspring, probably ($P < 0.05$) reduces the level of total and ionized calcium and phosphates in the blood of young animals (group 2) as compared to control group and group 3. Thus, the level of total calcium (Fig. 3) in animals with simulated hyperhomocysteinaemia was lower by 16% and ~18%, the level of ionized calcium – by 14% and ~16% (Fig. 4), and the level of total phosphorus - by ~14% and 12%, in groups 1 and 3, respectively

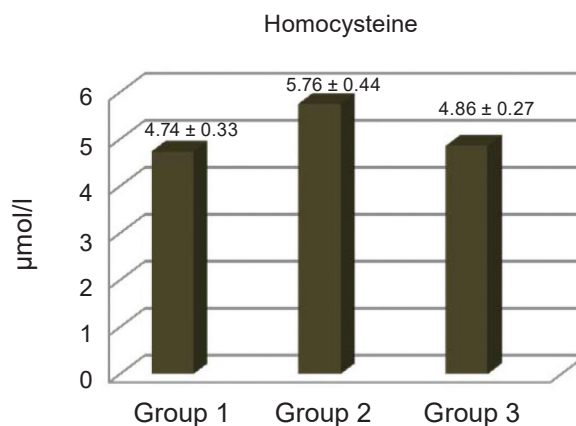


Fig. 1. Serum levels of homocysteine in the young rats

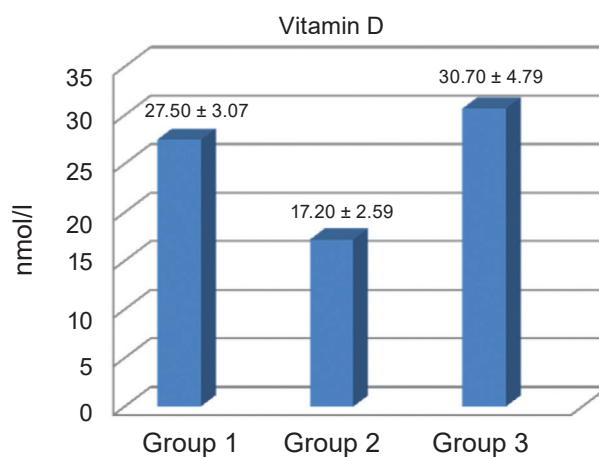


Fig. 2. Serum 25OHD levels in the young rats

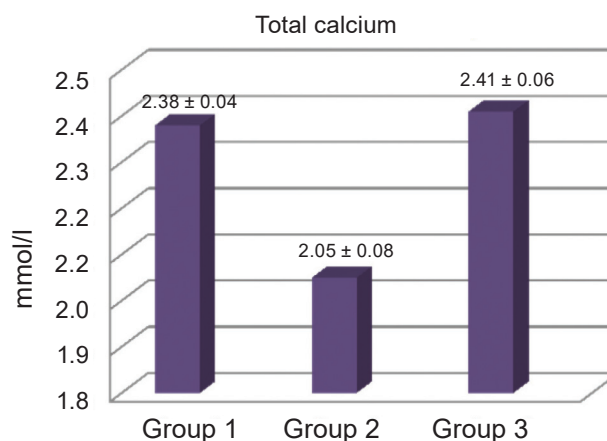


Fig. 3. The level of total calcium in the serum of young rats

(Fig. 5). Thus, changes in blood mineral composition in experimental rats occur in the prenatal period and are more related to vitamin D status than to Hcy.

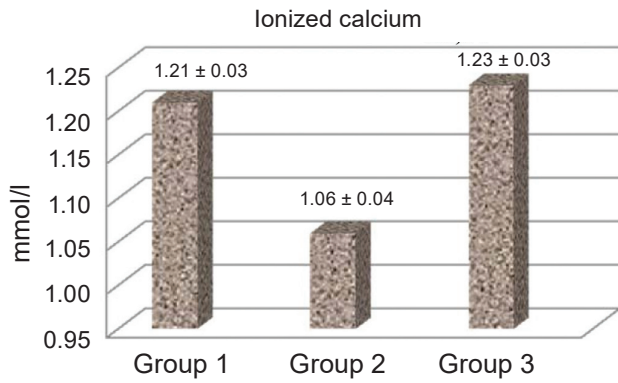


Fig. 4. Serum ionized calcium levels of the young rats

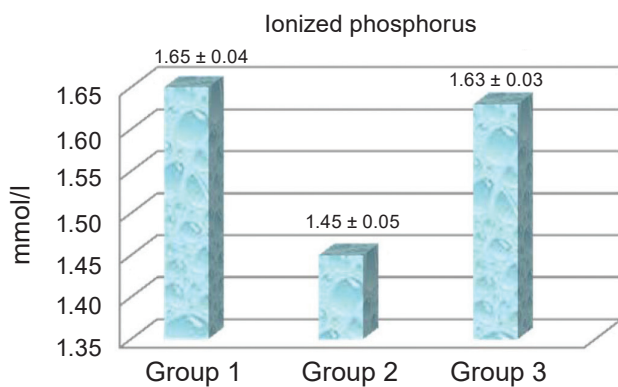


Fig. 5. Serum ionized phosphorus levels of the young rats

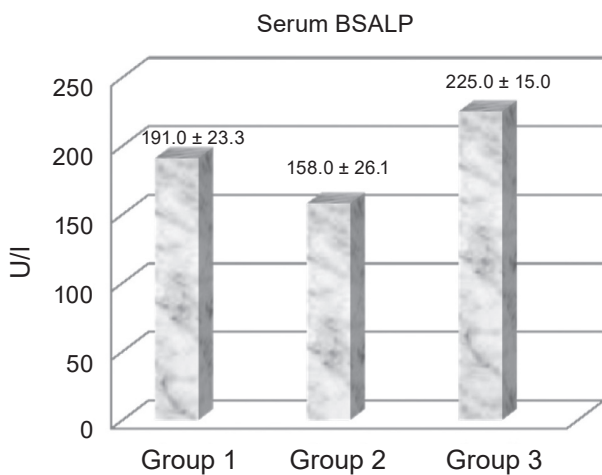


Fig. 6. Serum BSALP levels in the young rats

The results of the study of the activity of enzymes that affect bone mineral density are shown in Fig. 6-9. The activity of the bone isoform of ALP (BSALP) in the serum is the lowest in animals of group 2, but a probable difference ($P < 0.05$) is ob-

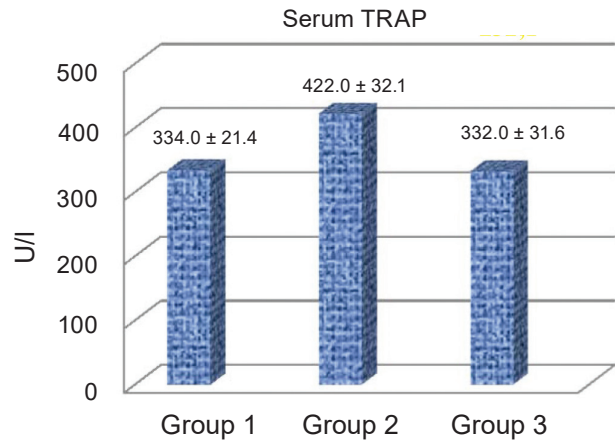


Fig. 7. Serum TRAP levels in the young rats

served only with the results of experimental group 3 (Fig. 6).

The activity of tartrate-resistant acid phosphatase (TRAP) in group 2 is probably ($P < 0.05$) higher than in the control group, and as compared to group 3 is registered at the level of the tendency to probability (Fig. 7).

The rate of ALP activity in the bone tissue of the mandible in rats of group 3 is probably higher, and activity of acid phosphatase is lower than in group 2 ($P < 0.05$) (Fig. 8, Fig. 9).

According to the activity of the above enzymes, we determined the index of mandibular bone mineralization in rats of group 2 with methionine-induced hyperhomocysteinaemia. It is probably ($P < 0.05$) less than in animals of intact control and rats with corrected hyperhomocysteinaemia, namely – in ~2,2 times fold.

On day 30 of life in rats of all groups, the presence of the first and second permanent molars

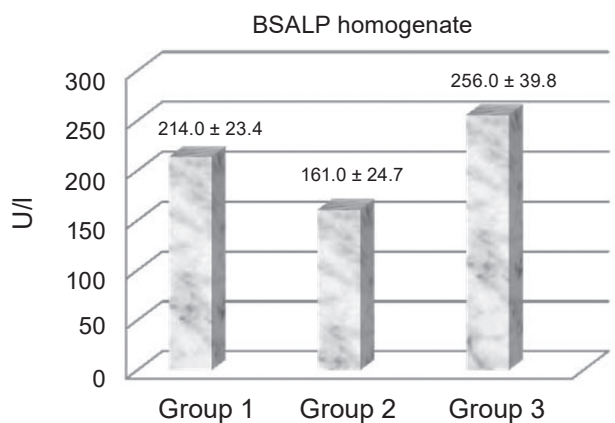


Fig. 8. Levels of BSALP in homogenates of edentulous mandibles of the young rats

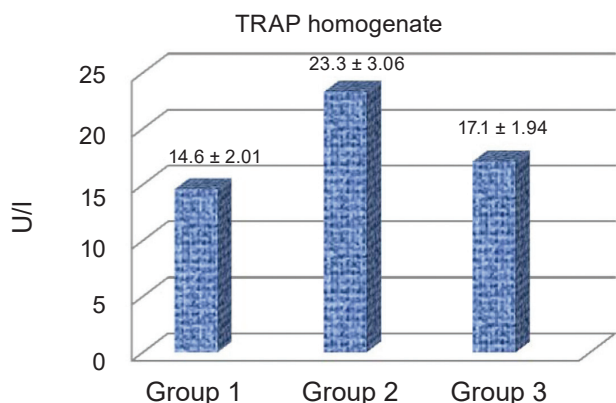


Fig. 9. Levels of TRAP in homogenates of edentulous mandibles of the young rats

was registered, but the final completion of molar eruption occurred at different times. In the control group, the fastest eruption of the third molar was registered on day 36 from birth, in group 2 – on day 40, and in group 3 – on day 34 of life. On average, the presence of all permanent molars was registered at 39.3 ± 1.41 days of life in the control group, in group 2 – at 43.8 ± 1.24 days, and in group 3 – at 39.2 ± 2.03 days, moreover, between 2 and 1 groups of rats this parameter was considered statistically significant ($P < 0.05$), and between 2 and 3 groups – was registered at the level of the tendency to probability. Thus, elevated levels of Hcy and, as a consequence, decreased levels of vitamin D in pregnant females cause a delay in complete physiological eruption of permanent molars in their offspring. Table 4 shows the data of morphometric studies of the size of the molars of the mandible of experimental rats.

Significant differences in the width and thickness of the studied teeth in rats of all groups were not detected. The difference in the height of the crowns of the first and second molars between the studied groups was not detected, and the crown height of the last permanent tooth in group 2 animals was probably smaller compared to the control and group 3. The above differences can be explained by the slowing down of the final eruption of the 3rd molar, which is most likely due to the incomplete formation of its roots due to impaired calcium-phosphorus metabolism in young rats. Signs of inflammation in the gums, pathological mobility, periodontal pockets in the area of the molars in rats of all groups were not observed. Atrophy of the alveolar sprout in

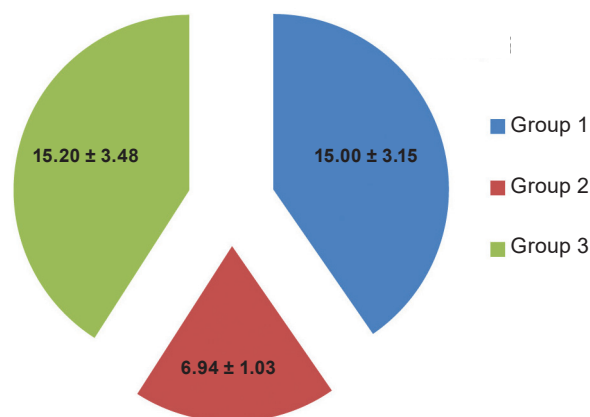


Fig. 10. Index of mineralization of the mandible in the young rats ($M \pm m$)

all groups was determined within the physiological norm.

The presence of superficial carious process in the teeth, which was localized only in the fissures, was registered only in 2 and 3 groups of rats. However, in animals of group 3 caries was detected in the first or second molars in isolated cases (only in the area of one fissure), and in group 2 – in all examined permanent teeth. In our opinion, this is due to the violation of mineral metabolism in utero under the influence of hyperhomocysteinaemia and/or vitamin D deficiency and, as a consequence, the imperfection of the enamel structure in the natural recesses of the occlusal surface of the molars.

Our results indicate that hyperhomocysteinaemia and vitamin D deficiency in the organism adversely affect calcium-phosphorus metabolism, which is actively reflected in the functioning of bone tissue and tooth physiology. This negative effect causes a decrease in the mineral density of the jaw bones, which in the future may lead to an increase in the number of fractures or destructive changes in the dental alveoli, as well as to the progression of the carious process.

Conclusions. Long-term simulation of methionine hyperhomocysteinaemia in pregnant female rats and hyperhomocysteinaemic diet reduces vitamin D status but does not increase Hcy levels in young offspring of infantile and early juvenile periods. Biochemical changes in blood, jaw bones and the presence of early carious process in the teeth of young rats, in our opinion, are the result of metabolic disorders in utero, caused by hyperhomocysteinaemia and vitamin D deficiency in their mothers. Our research re-

Table 4. Width, thickness and height of molar crowns of the right branch of the mandible of experimental young rats

Number group, number of animals	The width of the molars (mm)			The thickness of the molars (mm)			The height of the molars (mm)		
	1 st	2 nd	3 rd	1 st	2 nd	3 rd	1 st	2 nd	3 rd
Group 1, n = 103	2.96 ± 0.04	2.01 ± 0.02	1.81 ± 0.05	1.81 ± 0.06	1.91 ± 0.06	1.57 ± 0.08	1.35 ± 0.04	1.37 ± 0.06	1.28 ± 0.04
Group 2, n = 77	2.89 ± 0.06 $P_1 > 0.05$	1.95 ± 0.07 $P_1 > 0.05$	1.86 ± 0.09 $P_1 > 0.05$	1.72 ± 0.07 $P_1 > 0.05$	1.85 ± 0.04 $P_1 > 0.05$	1.45 ± 0.06 $P_1 > 0.05$	1.44 ± 0.08 $P_1 > 0.05$	1.38 ± 0.05 $P_1 > 0.05$	1.15 ± 0.02 $P_1 < 0.05$
Group 3, n = 101	2.91 ± 0.08 $P_1 > 0.05$ $P_2 > 0.05$	2.02 ± 0.05 $P_1 > 0.05$ $P_2 > 0.05$	1.83 ± 0.06 $P_1 > 0.05$ $P_2 > 0.05$	1.76 ± 0.09 $P_1 > 0.05$ $P_2 > 0.05$	1.89 ± 0.06 $P_1 > 0.05$ $P_2 > 0.05$	1.44 ± 0.06 $P_1 > 0.05$ $P_2 > 0.05$	1.41 ± 0.08 $P_1 > 0.05$ $P_2 > 0.05$	1.38 ± 0.05 $P_1 > 0.05$ $P_2 > 0.05$	1.26 ± 0.06 $P_1 > 0.05$ $P_2 < 0.05$

sults confirm the importance of the correction of hyperhomocysteinaemia with choline and vitamin D, that prevents the loss of bone mineral density of the jaws and effectively inhibits the carious process in the fissures of the root teeth of young rats.

Conflict of interest. Authors have completed the Unified Conflicts of Interest form at http://ukr-biochemjournal.org/wp-content/uploads/2018/12/coi_disclosure.pdf and declare no conflict of interest.

Funding. ?????

ПОКАЗНИКИ МІНЕРАЛЬНОГО ОБМІНУ ТА СТОМАТОЛОГІЧНОГО СТАТУСУ МОЛОДИХ ЩУРІВ, НАРОДЖЕНИХ ВІД САМОК ІЗ МЕТІОНІН-ІНДУКОВАНОЮ ГІПЕРГОМОЦИСТЕЇНЕМІЄЮ

O. I. Kutelmakh¹✉, P. B. Lesyk^{2,3},
Ю. Г. Чумакова⁴, С. А. Бондар¹,
В. Г. Дроненко¹, Л. І. Шкільняк¹

¹Національний медичний університет
ім. М. І. Пирогова, Україна;

²Львівський національний медичний університет
імені Данила Галицького, Україна;

³Університет інформаційних технологій
та менеджменту, Жешув, Польща;

⁴Міжнародний гуманітарний
університет, Одеса, Україна;

✉e-mail: ahzelol1968vin@i.ua

Ми припускаємо, що порушення метаболізму гомоцистеїну (Нсу) і рівня вітаміну D у матері внутрішньоутробно спричиняє різні аномалії у їх нащадків, у тому числі патологію у твердих тканинах зубів та порушення в пародонті. Метою роботи було вивчення біохімічних показників у крові та гомогенатах альвеолярних кісток та оцінка статусу зубів потомства, народженого від самок щурів після тривалої метіонінової гіпергомоцистеїнемії (ННсу). Клініко-біохімічні та морфометричні дослідження щурів проводили на 30 щурах-самках та 281 щурах інфантильного та раннього ювенільного періоду. Рівні Нсу в сироватці крові визначали за допомогою конкурентного імуноаналізу з електрохемілюмінесцентним визначенням, рівень 25ОНD оцінювали за допомогою ІЕА. У щурів, народжених від самок з ННсу, порушення рівня Нсу у сироватці не виявлено. Гіпергомоцистеїнемічна дієта, знижу-

вала рівень загального та іонізованого кальцію та фосфатів у крові вагітних самок та у їх потомства. Підвищений рівень гомоцистеїну і знижений рівень вітаміну D у вагітних самок спричиняли затримку повного фізіологічного прорізування постійних молярів у їх потомства. Зроблено припущення, що біохімічні зміни в крові, щелепних кістках та наявність раннього каріозного процесу в зубах молодих щурів, є наслідком внутрішньоутробного порушення обміну речовин, спричиненого ННсу та дефіцитом вітаміну D у їх матерів.

Ключові слова: метіонін-індукована гіпергомоцистеїнемія, гомоцистеїн, вітамін D, холін, стоматологічний статус, прорізування зубів.

References

1. Sakamoto A, Ono H, Mizoguchi N, Sakura N. Betaine and homocysteine concentrations in infant formulae and breast milk. *Pediatr Int.* 2001; 43(6): 637-640.
2. Wall CR, Stewart AW, Camargo CA Jr, Scragg R, Mitchell EA, Ekeroma A, Crane J, Milne T, Rowden J, Horst R, Grant CC. Vitamin D activity of breast milk in women randomly assigned to vitamin D₃ supplementation during pregnancy. *Am J Clin Nutr.* 2016; 103(2): 382-388.
3. Workalemahu T, Badon SE, Dishigalitzky M, Qiu C, Williams MA, Sorensen T, Enquobahrie DA. Placental genetic variations in vitamin D metabolism and birthweight. *Placenta.* 2017; 50: 78-83.
4. Glueck CJ, Jetty V, Rothschild M, Duhon G, Shah P, Prince M, Lee K, Goldenberg M, Kumar A, Goldenberg N, Wang P. Associations between Serum 25-hydroxyvitamin D and Lipids, Lipoprotein Cholesterols, and Homocysteine. *N Am J Med Sci.* 2016; 8(7): 284-290.
5. Bergen NE, Jaddoe VWV, Timmermans S, Hofman A, Lindemans J, Russcher H, Raat H, Steegers-Theunissen RPM, Steegers EAP. Homocysteine and folate concentrations in early pregnancy and the risk of adverse pregnancy outcomes: the Generation R Study. *BJOG.* 2012; 119(6): 739-751.
6. Ostrovsky YM. Experimental vitaminology (reference manual). Minsk: Science and technology, 1979. 552 p.
7. Nigam GK, Ansari MN, Bhandari U. Effect of rosuvastatin on methionine-induced hyperhomocysteinaemia and haematological changes in rats. *Basic Clin Pharmacol Toxicol.* 2008; 103(3): 287-292.
8. Kutelmakh OI, Lutsyuk MB, Lesyk RB, Kutelmakh YuO, Popova OI. Effect of Experimental Hyperhomocysteinemia and its Correction by Choline and Vitamin D on the Biochemical Indicators of the Female rats. *Exp Clin Physiol Biochem.* 2019; (1(85)): 72-74.
9. Pentiuik OO, Lutsyuk MB, Andrushko II, Postovitenko KP. Homocysteine metabolism and its role in pathology. *Ukr Biokhim Zhurn.* 2003; 75(1): 5-17. (In Ukrainian).
10. Kovalenko VN. Compendium 2017-Drugs. K.: Morion, 2017. 2560 p. (In Ukrainian).
11. Holick MF. The vitamin D deficiency pandemic: Approaches for diagnosis, treatment and prevention. *Rev Endocr Metab Disord.* 2017; 18(2): 153-165.
12. Owczarek D, Cibor D, Sałapa K, Jurczyszyn A, Mach T. Homocysteine in patients with inflammatory bowel diseases. *Przegl Lek.* 2014; 71(4): 189-192.
13. Kozhemyakin YM, Khromov OS, Filonenko MA, Sayretdinova GA. Scientific and practical recommendation sfor the maintenance of laboratory animals and work with them. Kyiv, 2002. 155 p.
14. Kutelmakh OI, Lutsyuk MB, Lesyk RB, Kutelmakh YuO, Popova OI. The biochemical parameters of blood and homogenate of the alveolar bone of female rats at long-term experimental methionine hyperhomocysteinemia and its correction with choline and vitamin D. *Exp Clin Physiol Biochem.* 2019; 4(88): 22-28.
15. Vagner VK, Putilin VM, Kharabuga GG. Methods and results of studying serum alkaline phosphatase isoenzymes (intestinal and liver fractions) in acute surgical diseases of the abdominal cavity organs. *Vopr Med Khim.* 1981; 27(6): 752-755. (In Russian).
16. Gaiday AN, Tussupkaliyev AB, Bermagambetova SK, Zhumagulova SS, Sarsembayeva LK, Dossimbetova MB, Daribay ZZh. Effect of homocysteine on pregnancy: A systematic review. *Chem Biol Interact.* 2018; 293: 70-76.