

PRACA ORYGINALNA  
ORIGINAL ARTICLE

## COMPARATIVE ASSESSMENT OF BILE DUCT DECOMPRESSION METHODS IN PATIENTS WITH OBSTRUCTIVE JAUNDICE OF NON-TUMOR GENESIS

Oleg Y. Kanikovskiy, Yaroslav V. Karyi, Yura V. Babiichuk, Yevhen V. Shaprynskiy

NATIONAL PIROGOV MEMORIAL MEDICAL UNIVERSITY, VINNYTSYA, UKRAINE

### ABSTRACT

**Introduction:** Obstructive jaundice is one of the most common diseases of the digestive system observed in 10-15% of the world's population. The question of making a choice among methods of bile duct decompression is still under discussion, since both single-stage and two-stage methods of biliary decompression lead to progression of hepatic insufficiency after restoration of bile passage.

**The aim:** To determine a tempo of biliary decompression after external and internal drainage of bile ducts, endoscopic transpapillary interventions in patients with obstructive jaundice of non-tumor genesis.

**Materials and methods:** We analyzed the outcomes of surgical treatment of 180 patients with obstructive jaundice of the non-tumor genesis. The patients were divided into three groups: group I (n = 86), where endoscopic methods of biliary decompression were used; group II (n = 48), where biliodigestive anastomoses were formed; and group III (n = 46), where the external drainage of bile ducts was conducted. The average age was  $62 \pm 6.0$  years. The average duration of obstructive jaundice was  $20 \pm 3.7$  days.

**Results:** The patients of the group I demonstrated a gradual decrease of bilirubin and alkaline phosphatase levels, which reached the normal readings on Day 7. The patients of the group II demonstrated normal levels of bilirubin and alkaline phosphatase on Day 14. The patients of the group III demonstrated rapid decrease of bilirubin and alkaline phosphatase levels, which reached the normal readings on Day 28. The transaminase level in each group of patients had reached the norm earlier.

**Conclusions:** No significant disturbances of the functional state of the liver after endoscopic transpapillary interventions were observed. Formation of areflux biliodigestive anastomoses was accompanied by a moderate rate of biliary duct decompression. The external drainage of biliary ducts was characterized by a rapid rate of biliary decompression, leading to a post-compression syndrome.

**KEY WORDS:** obstructive jaundice, external drainage of biliary ducts, biliodigestive anastomosis, endoscopic transpapillary intervention

Wiad Lek 2019, 72, 7, 1247-1252

### INTRODUCTION

According to WHO, obstructive jaundice (OJ) is one of the most common diseases of the digestive system observed in 10-15% of the world's population [1, 2]. The benign genesis of OJ is preconditioned by choledocholithiasis, stenotic papillitis, chronic fibrous pancreatitis, strictures of the bile ducts, parapapillary diverticula, and other diseases. The obstruction of the distal portion of the common bile duct (CBD) makes up to 14.7-35.5% of the total bile duct diseases [3, 4]. The discussion regarding a choice among the methods of biliary decompression is still underway. Most clinical institutions prefer a two-stage treatment method. Perhaps, a single-stage treatment approach is being increasingly used as the experience is gained and surgical techniques are improved [5, 6]. However, both single-stage and two-stage methods of bile duct decompression lead to a progression of hepatic insufficiency after bile duct restoration with 7-42% of patients having a fatal outcome [7, 8].

### THE AIM

To determine a tempo of biliary decompression after external and internal drainage of bile ducts, endoscopic transpapillary interventions in patients with obstructive jaundice of non-tumor genesis.

### MATERIALS AND METHODS

In the period from 2002 to 2018 180 patients with obstructive jaundice of non-tumor genesis received treatment at the surgical clinic of the medical faculty No. 2 of the National Pirogov Memorial Medical University 107 (59.4%) patients were females and 73 (40.6%) patients were males. The patients were divided by age according to WHO recommendations. There were 12 (6.7%) patients of a younger age, 30 (16.7%) patients of a middle age, 63 (35.0%) elderly patients, 70 (38.8%) senior patients, and 5 (2.8%) long-livers. The average age was  $62 \pm 6.0$  years. The duration of obstructive jaundice up to 14 days was

diagnosed in 97 (53.9%) patients, from 14 to 28 days – in 60 (33.3%) patients, and more than 28 days – in 23 (12.8%) patients. The average duration of obstructive jaundice was  $20 \pm 3.7$  days.

The obstructive jaundice underlying diseases were: choledocholithiasis – in 104 (57.8%) patients, Mirizzi's syndrome – in 14 (7.8%) patients, common bile duct stricture – in 7 (3.9%) patients, stenotic papillitis – in 18 (10.0%) patients, chronic fibrous pancreatitis – in 10 (5.5%) patients, pancreas head cyst – in 5 (2.8%) patients, duodenal ulcer penetrated in hepatoduodenal ligament – in 2 (1.1%) patients, and postcholecystectomy syndrome – in 20 (11.1%) individuals. Postcholecystectomy syndrome was caused by recurrent choledocholithiasis in 6 (3.3%) patients, by residual choledocholithiasis – in 8 (4.4%) patients, and by stenotic papillitis – in 6 (3.3%) patients.

Concomitant pathology was diagnosed in 156 (86.7%) patients, namely: ischemic heart disease – in 35 (19.4%) patients, hypertension – in 30 (16.7%) patients, chronic obstructive pulmonary disease – in 25 (13.9%) patients, dyscirculatory atherosclerotic encephalopathy – in 20 (11.1%) patients, diabetes mellitus – in 19 (10.6%) patients, peptic stomach and duodenal ulcer – in 14 (7.8%) patients, varicose disease of the lower extremities – in 33 (18.3%) patients, and obliterating atherosclerosis of the lower extremities vessels – in 23 (12.8%) patients. In 43 (23.9%) cases, a combination of two or more concomitant diseases was observed.

The methods of research were bioethical expertise at the Ethics and Bioethics Committee of the National Pirogov Memorial Medical University (Minutes No. 30 dated 10.12.2018). General clinical, laboratory, and instrumental study methods were used for diagnostics of bile duct obstruction. The cholestasis indicators included: an increase of the level of general and direct bilirubin, alkaline phosphatase; the indicators of the cytolytic syndrome were also assessed – a pre-surgery aspartate aminotransferase and alanine aminotransferase activity, as well as those on Days 1, 3, 5, 7, 10, 14, 28 after decompression of bile ducts.

The instrumental examination methods involved transabdominal ultrasonography, endoscopic ultrasonography, fibrogastroduodenoscopy, endoscopic retrograde pancreatic cholangiography, intraoperative cholangiography, and magnetic resonance imaging. Transabdominal ultrasonography was chosen the screening method for diagnostics of gallbladder and bile duct pathology and conducted for all patients. An echography was performed on a Lodgiq-500 PRO Series GE diagnostic unit. All patients with bile duct obstruction were subjected to fibrogastroduodenoscopy using a Pentax-290V fibrogastroduodenoscope. For direct contrast of bile ducts, endoscopic retrograde pancreatic cholangiography was performed using a 30% water-soluble contrast 10-20 ml and 3-5 ml for contrasting the main pancreatic duct. For contrasting bile ducts during surgery, intraoperative cholangiography was performed by injection of 10-20 ml of 30% contrast agent through a cystic duct remnant or a biliary duct puncture. With the impossibility of cannulation of a major duodenal papilla, endoscopic

ultrasonography was applied using the Olympus Exera EU M 60 diagnostic set. The Somatom-CR computerized tomograph was used for magnetic resonance imaging of the pancreas.

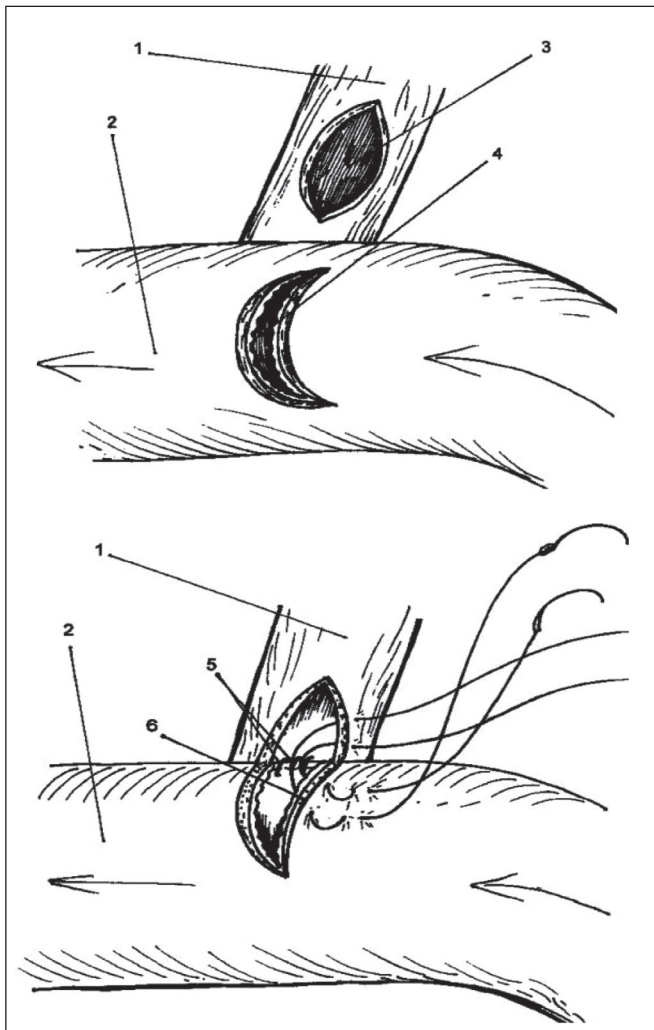
## RESULTS

We used transabdominal ultrasonography to detect bile duct dilatation (CBD diameter greater than 9 mm suggested the presence of bilateral hypertension) and the presence of concrements therein. At the same time, the number of concrements in CBD was precisely measured by endoscopic retrograde pancreatic cholangiography. The informativity of transabdominal ultrasonography for diagnostics of OJ causes was equal to 116 (64.4%). In 19 (10.6%) cases, the unsatisfactory results of transabdominal ultrasonography were preconditioned by severe flatulence – 7 (3.9%), obesity – 4 (2.2%), the presence of multiple small concrements (less than 3 mm) in the terminal portion of the CBD – 5 (2.8%), and aerocolia – 3 (1.7%). Endoscopic ultrasonography was used in such cases.

All patients with OJ were subjected to fibrogastroduodenoscopy, which gave the possibility to assess the shape and size of the duodenal papilla, the nature and volume of bile released, and to decide upon the possibility of further endoscopic retrograde pancreatic cholangiography. Fibrogastroduodenoscopy was also used for OJ differential diagnostics between a concrement stuck in the distal CBD and a pathology of major duodenal papilla in 18 (10.0%) patients.

Endoscopic retrograde pancreatic cholangiography was conducted in 70 (38.9%) cases. Choledocholithiasis was diagnosed in 52 (28.9%) patients, and stenotic papillitis – in 18 (10.0%) patients. Endoscopic retrograde pancreatic cholangiography failed to perform in 30 (16.7%) patients due to the presence of a calculus in the ampulla of major duodenal papilla in 19 (10.6%) patients, parapapillary diverticula in 9 (5.0%) patients, and the state after the Billroth II stomach resection in 2 (1.1%) patients. We used endoscopic ultrasonography when it was impossible to perform cannulation of major duodenal papilla. In addition, endoscopic ultrasonography made it possible to objectively estimate the proportion of calculi diameters and the terminal CBD portion. Complications after endoscopic retrograde pancreatic cholangiography were observed in 8 (4.4%) patients: acute pancreatitis – in 4 (2.2%) patients, acute cholangitis – in 2 (1.1%) patients, and bleeding from major duodenal papilla in 2 (1.1%) patients when endoscopic retrograde pancreatic cholangiography was combined with endoscopic papillosphincterotomy.

40 patients (22.2%) were subjected to intraoperative cholangiography. For that purpose, a contrast was introduced into bile ducts through a cystic duct remnant in 20 (11.1%) patients, and in 12 (6.7%) cases at puncture of CBD in patients with open cholecystectomy. During the laparoscopic cholecystectomy, intraoperative cholangiography was performed by catheterization of the cystic duct in 8 (4.4%) patients. Choledocholithiasis was diagnosed in 19 (10.6%) patients, Mirizzi's syndrome –



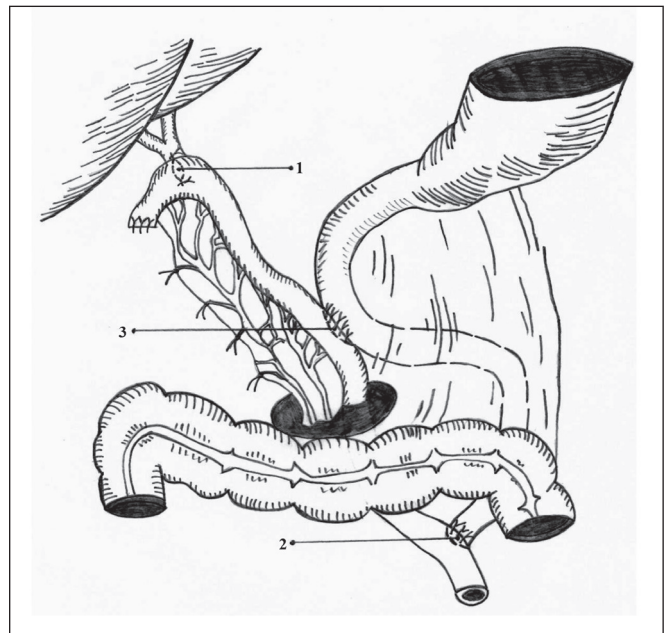
**Fig. 1.** A method of choledochoduodenostomy formation with the use of intraoperative technique of the duodenal contents reflux prevention.

- supraduodenal CBD portion – 1
- descending duodenal portion – 2
- longitudinal choledochotomy – 3
- crescent-shaped duodenotomy – 4
- choledochoduodenostomy "side-to-side" – 5
- duodenal opening – 6

in 14 (7.8%) patients, and CBD stricture – in 7 (3.9%) patients. In 5 (2.8%) cases, we observed complications after introduction of contrast in the bile duct: acute pancreatitis in 3 (1.7%) patients, and acute cholangitis in 2 (1.1%) patients.

Magnetic resonance imaging was used in 17 (9.4%) patients. In case of pancreas pathology, magnetic resonance imaging was used for diagnostics of chronic fibrous pancreatitis in 10 (5.6%) patients, pancreatic head cyst – in 5 (2.8%) patients, and magnetic resonance imaging was used for diagnostics of duodenal ulcer penetrated in hepatoduodenal ligament – in 2 (1.1%) cases.

In the course of the study, the patients were divided into three groups: group I (86 patients), where endoscopic



**Fig. 2.** A method of combined areflux hepaticojejuno duodenostomy.

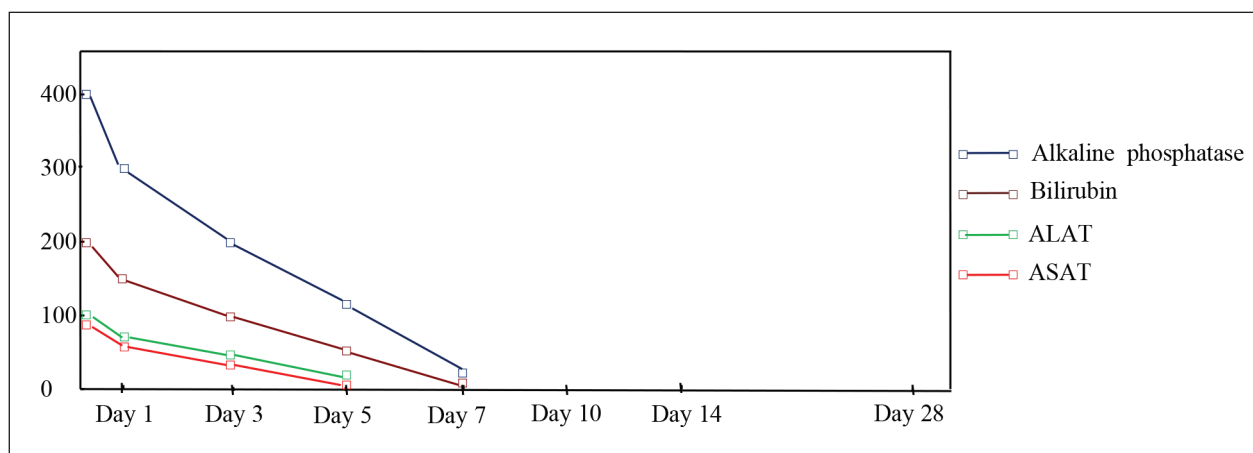
- hepaticojejunostomy "side-to-side" – 1
- interstitial anastomosis "end-to-side" – 2
- duodenojejunostomy "side-to-side" – 3

methods of biliary decompression were used, group II (48 patients), where biliodigestive anastomosis was formed, and group III (46 patients), in which external drainage of bile ducts was performed.

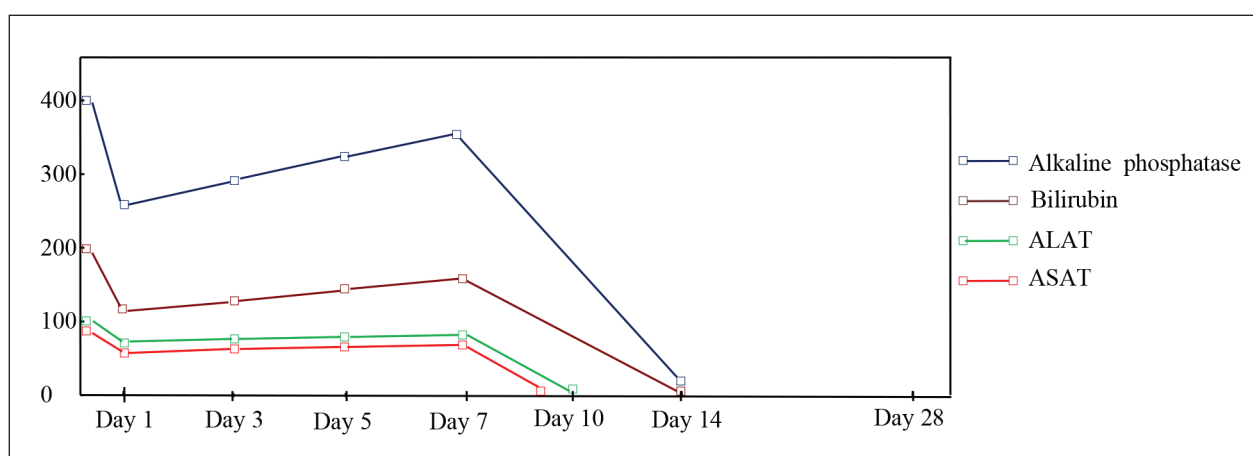
In group I patients, the endoscopic methods of biliary decompression were used in 86 (47.8%) cases. At the first stage, endoscopic papillary balloon dilatation was performed in 3 (1.7%) patients with single concretions up to 5 mm in diameter located in the distal CBD portions. We used balloons with a diameter of 4 and 6 mm. The balloons were filled with 30% contrast medium and monitored using radiocontrast labels. The balloon pressure was 4-9 atm. The duration of dilation was 15-60 seconds.

Incomplete endoscopic papillosphincterotomy (up to 1.0 cm) was performed in 22 (12.2%) patients with choledocholithiasis, which enabled a self-discharge of calculi with diameters up to 10 mm. In addition, we used incomplete endoscopic papillosphincterotomy in 18 (10.0%) patients with stenotic papillitis. A complete endoscopic papillosphincterotomy (over 1.0 cm) was performed in 19 (10.6%) patients, which enabled the lithoextraction using a Dormia basket (Olympus FG-22Q, Boston scientific trapezoid RX). In case of multiple calculi, we used lithoextractors with a conductor (Boston scientific trapezoid RX with guidewire PT2). After complete endoscopic papillosphincterotomy, a mechanical lithotripsy with Olympus BML-201Q lithotripter was performed in 12 (6.7%) cases of 10-20 mm calculi, followed by removal of fragmented concretions with Dormia basket.

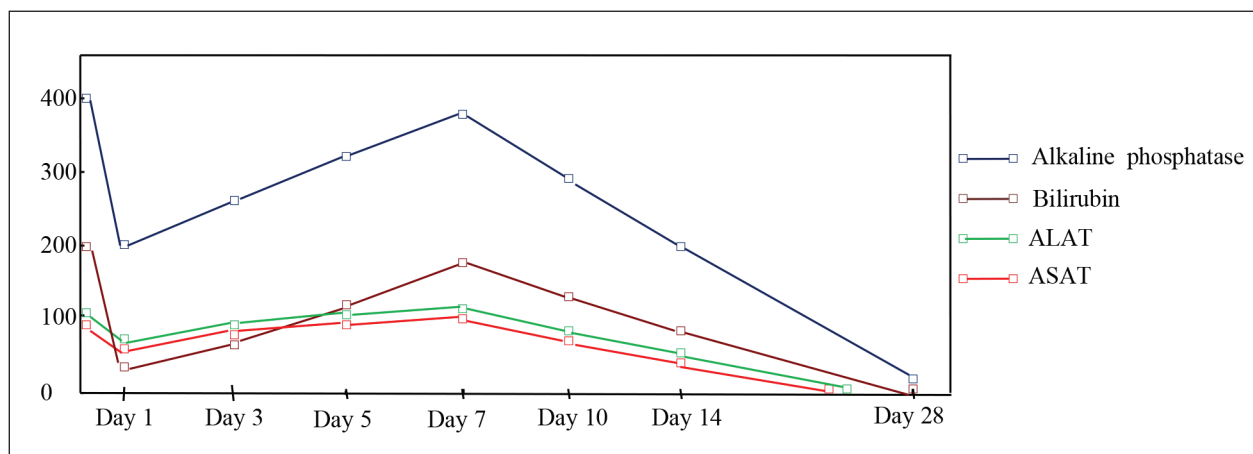
Endobiliary transpapillar stenting (stent diameter – 7 Fr) was performed for prolonged biliary decompression in 3



**Fig. 3.** Levels of bilirubin, alkaline phosphatase, ALAT, ASAT in group I patients.



**Fig. 4.** Levels of bilirubin, alkaline phosphatase, ALAT, ASAT in group II patients.



**Fig. 5.** Levels of bilirubin, alkaline phosphatase, ALAT, ASAT in group III patients.

(1.7%) patients with a stricture of CBD terminal portion. The stent encrusted with bile acid salts was replaced in 3-4 months. In case of purulent cholangitis, a nasobiliary drainage was performed in 9 (5.0%) patients, which made it possible to decompress and sanitation bile ducts. Laparoscopic cholecystectomy was performed at stage II, after treatment of OJ and purulent cholangitis.

Group II patients were subjected to internal drainage of bile ducts in 48 (26.7%) cases. In obstruction of distal

CBD portions, a choledochoduodenostomy was formed using an intraoperative technique for prevention of reflux of duodenal contents (patent of Ukraine No. 85986). We mobilized a supraduodenal CBD portion 1 and prepared a site for anastomosis on the descending duodenal portion 2. We performed a 15 mm-long longitudinal choledochotomy 3 and a crescent-shaped duodenotomy 4 in a transverse direction with a convex portion up to the intake portion of the gut. We formed a



choledochoduodenostomy using a "side-to-side" technique by 5 seams in one row across all layers of the walls of both hollow organs. When forming the upper edge of the anastomosis, the seam captured the serous-muscular wall of the duodenum, retreating 10 mm from the edge of the duodenal opening 6 in the proximal direction. When tightening a knot, the crescent flap was invaginated into the duodenal cavity, forming a slit-like valve that prevented duodenobiliary reflux and rapid decompression of bile ducts after surgery (fig. 1). Areflux choledochoduodenostomy was performed in 38 (21.1%) patients: in 23 (12.8%) cases of choledocholithiasis combined with stenotic papillitis, in 10 (5.5%) cases of chronic fibrous pancreatitis, and in 5 (2.8%) cases of the pancreas head cyst.

Combined areflux hepaticojejunoduodenostomy (patent of Ukraine No.112735) was formed in 10 (5.5%) patients, i.e. 4 (2.2%) individuals with CBD stricture and 6 (3.3%) patients with Mirizzi's type II syndrome. The areflux hepaticojejunostomy by "side-to-side" 1 technique was performed. For that purpose, we stitched and tucked up the front wall of the empty gut to form a cone, having departed 3-4 cm from the blind end of the small intestine. Under a ligature, we dissected the intestine wall and expanded the point opening with a clamp in the transverse direction. Subsequently, we conducted a longitudinal hepaticotomy and formed an anastomosis between the common hepatic duct and the empty intestine with a 15-20 mm single-row knot suture, with adaptation of the mucous membranes of the anastomosis organs. Upon passing a peristaltic wave, the gut wall "closed", which prevented a reflux of the intestinal contents in bile duct and rapid biliary decompression. The continuity of the intestinal tube was restored by applying two-row interstitial anastomoses of the "end-to-side" 2 type, 30-40 cm from the pre-formed biliodigestive anastomosis. In order to prevent the formation of peptic ulcers and for duodenostasis prophylaxis, an additional "side-to-side" duodenojejunostomy was formed between the excluded portion of the intestine and the descending branch of the duodenum 3 (fig. 2).

Y-shaped drainage (patent of Ukraine No. 101302) was used to prevent a leakage of bile in the abdominal cavity from the line of formed biliodigestive anastomosis. The drainage tube was led out to the anterior abdominal wall through a contraincision and connected to a constant suction unit (5-10 cm of water column). Using a vacuum unit made it possible to prevent a leakage of bile into the abdominal cavity.

We performed the external drainage of bile ducts in 46 (25.5%) group III patients. Laparoscopic cholecystectomy with cysticolitotomy with a Fogarty occlusion catheter was performed in 10 (5.5%) patients with up to 5 mm concrements below the point where the cystic duct run into the common hepatic duct. Laparoscopic cholecystectomy with external drainage of CBD was performed in 8 (4.4%) patients with Mirizzi's type I syndrome.

Open cholecystectomy with choledocholithotomy was performed in 26 (14.4%) patients with over 20 mm

concrements that could not be removed transpapillary. In 20 (11.1%) patients, a probe-obturator of extrahepatic bile duct was used (patent of Ukraine No. 104826). In the postoperative period, the volume of the obturator balloon was gradually reduced for 7-10 days, which made it possible to carry out dose-controlled decompression of bile ducts and to prevent a post-decompression liver dysfunction. A separation of ulcer defect was performed in 2 (1.1%) patients with duodenal ulcer penetrated in hepatoduodenal ligament. After the separation, a 1/3 duct circle-long defect was formed in the CBD. T-shaped drainage-balloon (patent of Ukraine No.104469) was used to prevent the formation of a CBD stricture after the duct defect suturation. The balloon dilatation at the level of CBD plastics lasted 3 months. No CBD stricture signs were present after two years after the surgery.

## DISCUSSION

In patients with OJ in the postoperative period, there are three syndromes: mesenchymal-inflammatory, cholestatic and cytolytic. High activity of hepatic cytolysis on the background of OJ and is a causes progression of hepatic insufficiency after bile duct restoration in the postoperative period [9, 10]. The severity of the patient's condition and the high frequency of postoperative complications have long led surgeons to the idea of multi-stage surgery in OJ [11]. Therefore, the study a tempo of the biliary decompression after various methods drainage of bile ducts will enable to prevent post-decompression liver dysfunction [12].

Gradual decrease of bilirubin and alkaline phosphatase levels on Days 1, 3, and 5 after endoscopic interventions, and reaching the normal level on Day 7 was observed in group I patients. Alanine aminotransferase (ALAT) and aspartate aminotransferase (ASAT) decreased to the standard levels on Day 5 (fig. 3). No significant violations of the functional state of the liver were observed after endoscopic transpapillary interventions, which is optimal for a post-compression period.

The group II patients demonstrated a decrease of bilirubin and alkaline phosphatase levels on Day 1 after formation of biliodigestive anastomoses, gradual increasing of the levels on Days 3, 5, and 7, and normalization thereof on Day 14. The ALAT activity restored on Day 10, ASAT – a day earlier (fig. 4). The formation of areflux choledochoduodeno-anastomosis and combined areflux hepaticojejunoduodenostomy was accompanied by a moderate rate of decompression of bile ducts due to the presence of a valve mechanism.

The group III patients demonstrated a rapid decrease of bilirubin and alkaline phosphatase levels on Day 1 after external drainage of bile ducts, their gradual increase on Days 3, 5, and 7, a decrease on Days 10, 14, and normalization on Day 28. The level of transaminases (ALAT, ASAT) reached the norm earlier – on Days 23 and 21, respectively (fig. 5). The external decompression of the biliary system was accompanied by a rapid decrease of pressure in bile ducts, which led to post-decompression liver dysfunction, required a dose-controlled decompression of bile ducts for 7-10 days and appropriate medicinal correction.

## CONCLUSIONS

1. No significant violations of the functional state of the liver were observed after endoscopic transpapillary interventions.
2. The formation of areflux biliodigestive anastomosis was accompanied by a moderate rate of biliary duct decompression due to the presence of a valve mechanism.
3. The external drainage of biliary ducts was characterized by a rapid rate of biliary decompression, which led to a post-decompression syndrome, and required a dose-controlled decompression of bile ducts and appropriate medicamental correction.

## REFERENCES

1. Topal B., Vromman K., Aerts R. Hospital cost categories of one-stage versus two-stage management of common bile duct stones. *Surg. Endosc.* 2010; 24: 413-416.
2. De Palma G.D., Luglio G., Maione F. et al. Endoscopic snare papillectomy: a single institutional experience of a standardized technique. A retrospective cohort study. *Int. J. Surg.* 2015; 13: 180-183.
3. Li Zhe-Fu, Chen Xiao-Ping. Recurrent lithiasis after surgical treatment of elderly patients with choledocholithiasis. *Hepatobil. Pancr. Dis. Int.* 2007; 6: 67-71.
4. Savolyuk S.I., Losyev V.O. Assessment of the structural-functional changes of the collagen in the wall of the common bile duct in acute cholangitis in patients with choledocholithiasis. *Reports of morpholog.* 2016; 1(22): 145-148.
5. Stark A., Hines O.J. Endoscopic and operative palliation strategies for pancreatic ductal adenocarcinoma. *Semin. Oncol.* 2015; 42(1): 163-176.
6. Santo, M.A., Domene C.E., Riccioppo, D. Common bile duct stones: analysis of the videolaparoscopic surgical treatment. *Arg. Gastroenterol.* 2012; 49(1): 41-51.
7. Desiaterik V.I., Kotov A.V., Mamchur D.V. Ways to improve the results of surgical treatment for obstructive jaundice on the background of gallstone disease. *Ukrain. J. Surg.* 2017; 1(32): 100-105.
8. Yang M.J., Kim J.H., Yoo B.M. et al. Partially covered versus uncovered self-expandable nitinol stents with anti-migration properties for the palliation of malignant distal biliary obstruction: A randomized controlled trial. *Scand. J. Gastroenterol.* 2015; 50(12): 1490-1499.
9. Orel Y.M., Dziubanovskiy O.I., Shkrobot L.V. Structural changes of liver tissue in the conditions of modelled cholestasis and after it liquidation. *Hospital Surg.* 2016; 2: 45-49.
10. Lilly M.C., Arregai M.E. Balanced approach to choledocholithiasis. *Surg. Endoscop.* 2001; 15(5): 467-472.
11. Costi R., Gnocchi A., Di Mario F. et al. Diagnosis and management of choledocholithiasis in the golden age of imaging, endoscopy and laparoscopy. *World J. Gastroenterol.* 2014; 20(37): 1388-1401.
12. Nychytaylo M.Y., Dziubanovskiy O.I. Comparison of dynamics of cytolytic and cholestatic indicators and the tempo of the biliary decompression after one-step laparoscopic and open operation interventions of patients with choledocholithiasis complicated with obstructive jaundice. *Hospital Surg.* 2017; 1: 8-16.

### Authors' contributions:

*According to the order of the Authorship.*

### Conflict of interest:

*The Authors declare no conflict of interest.*

---

## CORRESPONDING AUTHOR

**Yaroslav V. Karyi**

Surgery Department of the Medical Faculty No.2,  
National Pirogov Memorial Medical University  
56 Pirogov Str., Vinnytsya 21018, Ukraine  
tel: +380677429457  
e-mail: yaroslavkaryi@gmail.com

**Received:** 10.02.2019

**Accepted:** 06.06.2019