

PRACA ORYGINALNA
ORIGINAL ARTICLE

IMPROVING THE RESULTS OF THE LAPAROSCOPIC CHOLECYSTECTOMY IN PATIENTS WITH COMPLICATED COURSE OF THE CALCULOUS CHOLECYSTITIS

Oleg Y. Kanikovskiy, Yaroslav V. Karyi, Yura V. Babiichuk, Yevhen V. Shaprynskyi

NATIONAL PIROGOV MEMORIAL MEDICAL UNIVERSITY, VINNYTSYA, UKRAINE

ABSTRACT

Introduction: The laparoscopic cholecystectomy (LCE) has become “gold standard” in treatment of the gallstone disease (GSD). However, introduction of LCE is accompanied by increase in the frequency of the bile duct injuries by 2-5 times, and transfer to the conversion offsets main advantages of the laparoscopic access.

The aim: To improve the results of treatment of the patients with complicated course of the calculous cholecystitis by developing new methods of the laparoscopic cholecystectomy.

Materials and methods: The results of surgical treatment of 420 patients with complicated course of the calculous cholecystitis were analyzed. The patients were divided into two groups: group I (n = 210) where the standard four-trocar LCE was used and the group II (n = 210) where the developed methods of LCE were used. The average age made up 62 ± 6.0 years. Duration of disease made up from 1 month to 35 years.

Results: The patients in group I LCE with complicated course of the acute cholecystitis was performed in 108 (25.7%) cases, chronic – in 102 (24.3%) cases. The patients in group II surgical intervention with complicated course of the acute cholecystitis was performed in 112 (26.7%) cases, chronic – in 98 (23.3%) cases. The patients of group I intraoperative injuries were observed in 12 (5.7%) cases and patients of group II – in 4 (1.9%) cases. The conversion was applied in 13 (6.2%) and in 4 (1.9%) cases, respectively. 2 (0.9%) patients died.

Conclusions: Introduction of the developed methods of LCE with complicated course of the calculous cholecystitis allows to reduce the frequency of intraoperative injuries by 3,8% and conversion rate – by 4,3% ($p < 0,001$).

KEY WORDS: complicated course of the acute and chronic calculous cholecystitis, laparoscopic cholecystectomy, intraoperative injuries

Wiad Lek 2019, 72, 5 cz. I, 790-794

INTRODUCTION

The incidence of GSD disease in the last decades has a tendency to increasing, especially its complicated forms [1, 2]. Among the population of Europe, the incidence of GSD disease makes up 17-25%, over the age of 60 – 35-55% [3, 4]. Among the patients with complicated GSD 65-70% are persons of elderly and old age [5]. LCE has become “gold standard” in treatment of GSD. The advantages of LCE over the open method are determined by the less trauma of abdominal wall, decrease in the level of complications and decrease in the duration of stay of the patient in the hospital [6, 7]. However, introduction of LCE is accompanied by increase in the frequency of the bile duct injuries by 2-5 times compared with the open method of surgery, and transfer to the conversion negates main advantages of the laparoscopic access [8, 9, 10].

THE AIM

To improve the results of treatment of the patients with complicated course of the calculous cholecystitis by developing new methods of the laparoscopic cholecystectomy.

MATERIALS AND METHODS

In the period from 2002 to 2018 at the surgical clinic of the medical faculty No. 2 of National Pirogov Memorial Medical

University, Vinnytsya there were 420 patients with complicated course of the calculous cholecystitis treated. There were 133 men (31.7%), and 287 (68.3%) women. Average age was 62 ± 6.0 years. Duration of disease made up from 1 month to 35 years.

The complicated course of the acute calculous cholecystitis was observed in 220 (52.4%) patients, including empyema of gallbladder – in 74 (17.6%), perivesical infiltrate – in 83 (19.8%), perivesical abscess – in 22 (5.2%), biliary peritonitis – in 6 (1.4%), choledocholithiasis – in 35 (8.4%) cases. The complicated course of the chronic calculous cholecystitis was registered in 200 (47.6%) patients, including sclerotic gallbladder – in 49 (11.6%), gallbladder hydrops – in 37 (8.8%), widespread adhesion process – in 66 (15.7%), Mirizzi's syndrome – in 10 (2.4%), choledocholithiasis – in 15 (3.6%), biliodigestive fistula – in 5 (1.2%), stenosing papillitis – in 18 (4.3%) cases.

The screening method for diagnostics of gallbladder and bile duct pathology included transabdominal ultrasonography, which was performed for all patients. Echography study was performed on the diagnostic apparatus Lodg-iq-500 PRO Series GE. In the patients with obstruction of the common bile duct (CBD), fibrogastroduodenoscopy was performed using fibrogastroduodenoscope Pentax-290V. The endoscopic retrograde pancreatic cholano-

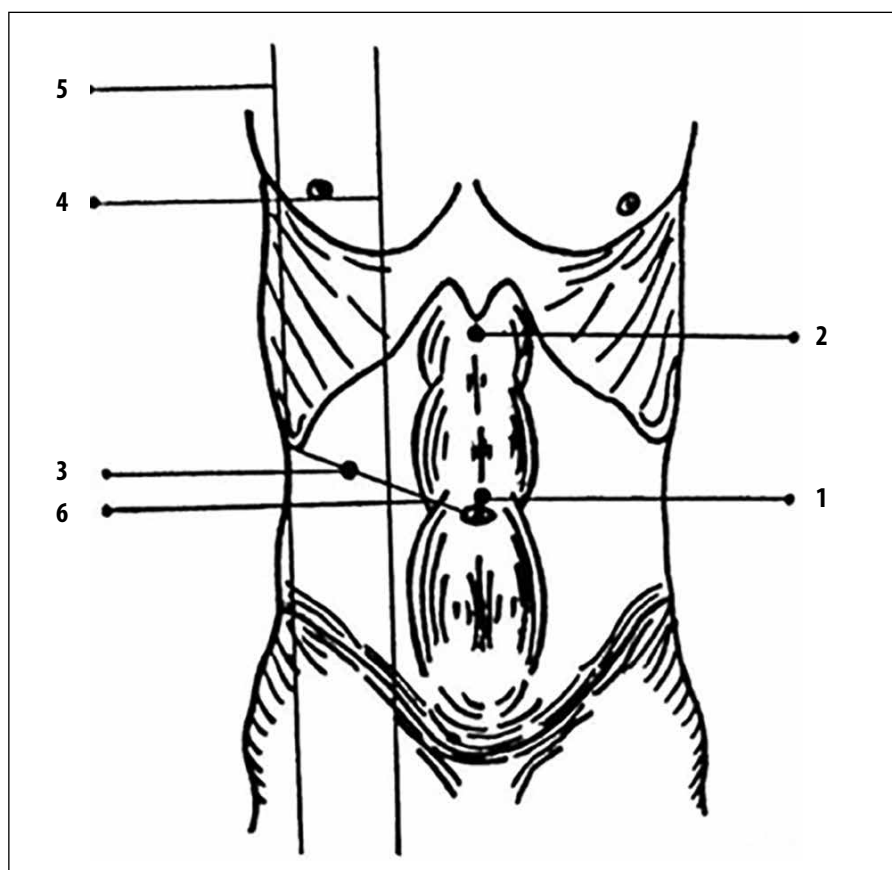


Figure 1. The method of three-trocar laparoscopic cholecystectomy in the widespread adhesion process in the hepatoduodenal area

first port – 1
 second port – 2
 third port – 3
 medioclavicular line – 4
 front axillary line – 5
 oblique line – 6

giography was used for direct contrasting of the bile ducts using 30% of contrast in volume of 10-20 ml and 3-5 ml for contrasting of the main duct of pancreas. For contrasting of the bile ducts during operation, the intraoperative cholangiography was performed by administering 10-20 ml of 30% contrast through the cystic duct or by biliary puncture. By the impossibility of cannulation of the major duodenal papilla the endoscopic ultrasonography was performed using the diagnostic apparatus Olympus Exera EU M 60 and magnetic resonance imaging on the computer tomography Somatom-CR.

RESULTS AND DISCUSSION

During the study the patients were divided into two groups: group I, where the standard four-trocar LCE was performed and described by Reddick-Olsen, included 210 persons and group II – 210 patients, where the developed methods of LCE were used: “The method of the laparoscopic cholecystectomy in the complicated course of the acute and chronic calculous cholecystitis” (patent of Ukraine No. 77985) and “The method of three-trocar laparoscopic cholecystectomy in the widespread adhesion process in the hepatoduodenal area” (patent of Ukraine No. 111662).

For prevention of intraoperative injuries of the hepatoduodenal area the patients of both groups were thoroughly examined before operation, and the timely scheduled surgical treatment of the patients with GSD was carried out in the “cold” period. By the acute cholecystitis, LCE was

conducted in period of up to 72 hours from the onset of the disease, with a lower probability of perivesical complications. With duration of the chronic cholecystitis over 5 years, there was marked sclerosis of gallbladder wall, that’s why the planned surgical intervention was attempted at the shortest duration of GSD.

LCE under the intubation anesthesia was performed in 298 (69.3%) patients. In 132 (30.7%) patients with the severe cardiovascular and pulmonary diseases, LCE was performed under the epidural anesthesia. For the purpose of anesthesia, catheterization of the epidural space was continued in early postoperative period. Pneumoperitoneum was created and maintained at the average pressure level of 12-14 mm Hg. The maximum intra-abdominal pressure was 15 mm Hg. The pressure in the abdominal cavity of patients older than 60 years in presence of cardiovascular and pulmonary pathology was not more than 10 mm Hg. By the long surgical intervention, after 20-30 minutes, the pressure was reduced to 4-6 mm Hg for up to 10 minutes.

LCE in the patients of group I (n = 210) was performed according to the standard four-trocar method. LCE by complicated course of the acute calculous cholecystitis was performed in 108 (25.7%) patients, chronic – in 102 (24.3%) patients.

Four-trocar LCE (Reddick-Olsen) was performed as follows: 4 trocars were introduced into the abdominal cavity (the first one, of 10 mm, to the paraumbilical area, the second, of 10 mm, – to the epigastric area, the third and fourth, of 5 mm, – in the right hypohondria area). After

insertion of instruments into the abdominal cavity, the main traction was performed for the gallbladder bottom and lateral traction – for Hartmann's pocket. Mobilization of the gallbladder was carried out by the L-shaped electrode from medial surface to lateral in projection of the gallbladder neck. After discharge of the cystic duct, one clip was applied proximally and two clips – on its distal department. The cystic duct was crossed between clips. The cystic artery was clipped in proximal department or coagulated with bipolar clamp and crossed. After intersection of tubular structures of the Calot triangle gallbladder was removed from the liver bed. The gallbladder was removed from the abdominal cavity through the under-ensiform access or through the umbilical ring in presence of the umbilical hernia.

The developed methods of LCE were used for the patients of group II (n = 210). The operative interference by the complicated course of the acute calculous cholecystitis was performed in 112 (26.7%) patients, chronic – in 98 (23.3%) patients.

The method of the laparoscopic cholecystectomy in the complicated course of the acute and chronic calculous cholecystitis (patent of Ukraine No. 77985) was applied in 150 (35.7%) cases. 4 trocars were also introduced in the abdominal cavity. All ports, except for the first one, were introduced under control of laparoscope. For the more secure introduction of the first trocar, aponeurosis was previously dissected by the scalpel for 3-4 mm. The direction of the trocars introduction was oblique in projection of the gallbladder. Then revision of organs of the abdominal cavity was performed. Due to presence of the tense gallbladder in 44 (10.4%) patients there was difficulty in grasping it with a clamp, that's why the operation was started with puncture of the gallbladder and evacuation of its contents. When the acute process lasted for more than 72 hours, the infiltrate became dense, which created danger of intraoperative injuries. In 68 (16.2%) patients due to presence of the dense perivesical infiltrate, which spread to the hepatoduodenal ligament, it was impossible to seize the Hartmann's pocket and to perform the lateral traction. In such cases, the gallbladder was mobilized from the lateral (free wall) to the medial wall in the projection of the gallbladder neck, which made it possible to avoid intraoperative injuries. After mobilization of the gallbladder neck with a clamp, the lateral traction for the Hartmann's pocket was performed. Dissection of the cystic duct and arteries was carried out with opening of the Calot triangle at the sufficient distance from the major bile ducts and blood vessels. The cystic duct was dissection to distance sufficient for its clipping and crossing. First, the proximal clip was laid as close as possible to the gallbladder neck, and then – two clips to distal section of the cystic duct. It was crossed between the clips. With diameter of the cystic duct over 5 mm it was clipped by the cascade technique. For this purpose, the clip was placed on 2/3 of diameter of the duct and crossed it over the clip. After that, the second clip was placed and the duct was completely crossed. The cystic artery was clipped in the proximal department

with one clip or coagulated with the bipolar clamp, leaving a long residual limb. Crossing of the cystic artery was performed by the L-shaped electrode or scissors near the gallbladder wall. In the pronounced infiltrative changes the full mobilization of main trunk of the cystic artery was not the aim. In such cases, the vessels were clipped which clearly passed on the wall of the gallbladder (arteries of II, III order). After intersection of the cystic duct and arteries, the gallbladder was isolated from the bed in the connective tissue layer between the wall of the gallbladder and the liver parenchyma. For the clear detection of the connective tissue layer, traction of the gallbladder was performed for the bottom in opposite direction to the mobilization area. In the postoperative period, for control of bile leakage and hemorrhage, the subhepatic space was drained by the tubular drainage, which was removed on 1-2 day of the postoperative period.

In the presence of the sclerotic gallbladder in 30 (7.1%) patients LCE had technical difficulties due to induration and rigidity of its walls, filling of the lumen of the gallbladder with stones, shortening and shrinking of the tubular structures of the Calot triangle. Due to induration and shrinking of the gallbladder walls, lateral traction for the Hartmann's pocket was more difficult, and there was high placement of the cystic duct and artery observed. In such cases, the gallbladder was mobilized from the lateral wall to the medial one in projection of the Hartmann's pocket. High mobilization of the gallbladder made it possible to avoid intraoperative injuries. In 8 (1.9%) patients with the severe sclerotic changes removal of the gallbladder from the bed created danger of significant damage to the liver. In such cases, the anteriolateral wall of the gallbladder was cut off by the scissors or the L-shaped hook. After that the mucoclast of the back wall was carried out by the bipolar clamp. The cut part of the gallbladder together with its contents was placed in the container and removed from the abdominal cavity.

By the excessive peritoneal adhesion in the hepatoduodenal area there is a risk of the intraoperative bile duct injuries by introducing of the first and third trocars. In such cases, in 60 (14.3%) patients, the method of three-trocar laparoscopic cholecystectomy in the widespread adhesion process in the hepatoduodenal area was used (patent of Ukraine No. 111662). Prior to the surgery, the transabdominal ultrasonography of the paraumbilical area was performed to prevent intraoperative injuries by introducing of the first trocar. The first port 1, of 10 mm in diameter, was introduced into the paraumbilical area. Under laparoscopic control, the second port 2, of 10 mm in diameter, was introduced to the epigastric area. After revision of the abdominal cavity, the third port 3, of 5 mm in diameter, was introduced in the middle of distance between the medioclavicular line 4 and the front axillary line 5 at the intersection with the oblique line 6, which connects the right arc of the ribs with the navel (figure 1). In the presence of the widespread peritoneal adhesion process in the subhepatic space, the low input of the third port made it possible to prevent injuries to the tubular

structures of the hepatoduodenal area. With the help of a grasper, introduced into the abdominal cavity through the third trocar, main traction was performed for the bottom of the gallbladder. The dissection of the adhesions was carried out by the L-shaped electrode at distance necessary to mobilize the gallbladder neck. After that, the lateral traction was performed on the gallbladder neck with the grasper from the third port. Due to the fact that the third trocar was located in the middle of distance between the medioclavicular line and the front axillary line, traction for the bottom and neck of the gallbladder was carried out without any technical difficulties and did not complicate the course of the surgical intervention.

In the patients of both groups, 75 (17.9%) minimally invasive interventions were performed on the bile ducts. By the complicated course of the acute calculous cholecystitis in 30 (7.1%) cases the two-stage tactics was used (LCE with the endoscopic transpapillary interventions in early postoperative period). At the first stage endoscopic hydrostatic balloon dilation of the major duodenal papilla was performed in 3 (0.7%) patients in the presence of single stones with the diameter of up to 5 mm located in the distal parts of the CBD. In 27 (6.4%) patients endoscopic papillosphincterotomy (EPS) was performed. Spontaneous passage of stones of up to 10 mm in diameter occurred in 11 (2.6%) of the cases. Lithoextraction by means of the Dormia basket (Olympus FG-22Q, Boston scientific trapezoid RX) was performed in 10 (2.4%) patients. Mechanical lithotripsy was performed using Olympus BML-201Q lithotripter in 6 (1.4%) patients with diameter stones of 10-20 mm, after what the fragmented stones were removed with the Dormia basket. The single-stage interventions (LCE with the lithoextraction through the cystic duct) were performed in the presence of the not dense perivesical infiltrate in 5 (1.2%) patients, when CBD was defined without technical difficulties.

In the presence of complicated course of the chronic calculous cholecystitis, the two-stage tactics (EPS followed by LCE) was used in 10 (2.4%) patients with choledocholithiasis and 18 (4.3%) – with the stenosing papillitis, which were diagnosed before surgery. The time interval between EPS and LCE was minimal (2-3 days), which reduced the risk of migration of the stones in CBD. In the absence of the sclerotic gallbladder and excessive peritoneal adhesion, the one-stage intervention was performed: LCE with the cysticolithotomy – in 5 (1.2%) patients with choledocholithiasis, LCE with the external drainage of the CBD through the cystic duct – in 7 (1.7%) patients with Mirizzi's syndrome of the I type.

Conversion in the patients of group I was applied in 13 (6.2%) cases due to impossibility of verifying the tubular structures of the Calot triangle during 30 minutes. The transrectal minilaparotomy was performed in 6 (2.8%) patients, including because of the dense perivesical infiltrates – in 2 (0.9%), sclerotic gallbladder – in 2 (0.9%), excessive peritoneal adhesion in the hepatoduodenal area – in 2 (0.9%) cases. The suprmedian laparotomy was performed in 7 (3.3%) patients: 1 (0.5%) because to inju-

ry of the right hepatic artery, 2 (0.9%) – complete injury of the CBD, Mirizzi's syndrome of type II – in 1 (0.5%), biliodigestive fistula – in 3 (1.4%) cases. In the patients of group II conversion on the suprmedian laparotomy was performed in 4 (1.9%) cases. The reason for this was: Mirizzi's syndrome of type II – in 2 (0.9%), biliodigestive fistula – in 2 (0.9%) cases.

The intraoperative injuries of the patients of group I were observed in 12 (5.7%) patients: complete injury of the CBD – in 2 (0.9%), marginal injury of the CBD – in 1 (0.5%), clapping of the common hepatic duct – in 1 (0.5%), cystic duct stump inefficiency – in 3 (1.4%), bile leakage from the gallbladder bed – in 2 (0.9%), bleeding from the right hepatic artery – in 1 (0.5%), bleeding from the bed of the gallbladder – in 2 (0.9%) cases. 2 (0.9%) patients died due to the extensive myocardial infarction and massive thromboembolism of the pulmonary artery. The patients of group II intraoperative injuries arose in 4 (1.9%) patients: cystic duct stump inefficiency – in 2 (0.9%), bile leakage from the gallbladder bed – in 2 (0.9%) cases. There were no fatalities.

The statistical data analysis showed a statistically significant difference of the frequency of the intraoperative injuries after the standard four-trocar LCE and developed methods of LCE ($p < 0.001$) and conversions in patients of groups I and II ($p < 0.001$). The evaluation of long-term results based on the questionnaire SF-36 (Short Form-36) showed no real difference in the studied groups of patients.

CONCLUSIONS

1. Introduction of the developed methods of LCE with complicated course of the calculous cholecystitis allows to reduce the frequency of intraoperative injuries by 3,8% and conversion rate – by 4,3% ($p < 0,001$).
2. When combine the calculous cholecystitis with the choledolithiasis, it is expedient to use the two-stage surgical intervention: LCE with the endoscopic transpapillary interventions in early postoperative period with the acute course of the calculous cholecystitis and EPS followed by LCE for the chronic course of the cholecystitis.
3. The single-stage operations (LCE with the subsequent intervention on the bile ducts) it is expedient to use in patients with the acute cholecystitis, complicated by the not dense perivesical infiltrate, and in absence of the sclerotic gallbladder and excessive peritoneal adhesion in the chronic cholecystitis.

REFERENCES

1. Becker B.A., Chin E., Mervis E. Emergency biliary sonography: utility of common bile duct measurement in the diagnosis of cholecystitis and choledocholithiasis. *Engl. J. Med.* 2014; 46(1): 54-60.
2. Anand A., Pathania B.S., Singh G. Conversion in laparoscopic cholecystectomy: An Evaluation study. *J. Med. Educat. & Resear.* 2007; 9(4): 171-174.
3. Dan D., Harmanan D., Maharaj R. Laparoscopic cholecystectomy: analysis of 619 consecutive cases in a Caribbean setting. *J. Natl. Med. Assoc.* 2009; 101(4): 355-360.

4. Topal B., Vromman K., Aerts R. Hospital cost categories of one-stage versus two-stage management of common bile duct stones. *Surg. Endoscop.* 2010; 24: 413-416.
5. Costi R., Mazzeo A., Tartamella F. Cholecystocholedocholithiasis: a case-control study comparing the short- and long-term outcomes for a "laparoscopy-first" attitude with the outcome for sequential treatment (systematic endoscopic sphincterotomy followed by laparoscopic cholecystectomy). *Surg. Endoscop.* 2010; 24: 51-62.
6. Litwin D.E., Cahan M.A. Laparoscopic cholecystectomy. *Surg. Clin. North Am.* 2008; 88(6): 1295-1313.
7. Wolf A.S., Nijssen B.A., Sokal S.M. Surgical outcomes of open cholecystectomy in the laparoscopic era. *Am. J. Surg.* 2009; 197(6): 781-874.
8. Mercado M.A., Chan C., Orozco H. Prognostic implications of preserved bile duct confluence after iatrogenic injury. *Hepatogastroenterol.* 2005; 52(61): 40-44.
9. Le V.H., Smith D.E., Johnson B.L. Conversion of laparoscopic to open cholecystectomy in the current era of laparoscopic surgery. *Am. Surg.* 2012; 78(12): 1392-1395.
10. Zhang W.J., Li J.M., Wu G.Z. Risk factors affecting conversion in patients undergoing laparoscopic cholecystectomy. *ANZ J. Surg.* 2008; 78(11): 973-976.

Authors' contributions:

According to the order of the Authorship.

Conflict of interest:

The Authors declare no conflict of interest.

CORRESPONDING AUTHOR

Yaroslav V. Karyi

National Pirogov Memorial Medical University, Vinnytsya

Surgery Department of the Medical Faculty No. 2

56 Pirogov Str., Vinnytsya, Ukraine, 21018

tel: +380677429457

e-mail: yaroslavkaryi@gmail.com

Received: 11.01.2019

Accepted: 10.04.2019