



Wiadomości Lekarskie

Czasopismo Polskiego Towarzystwa Lekarskiego



Pamięci
dra Władysława
Biegańskiego

TOM LXXII, 2019, Nr1

Rok założenia 1928

Tetiana V. Khmara, Ihor I. Zamorskii, Mariana O. Ryznychuk, Mariana I. Kryvchanska, Oleh M. Boichuk, Roman R. Dmytrenko PECULIARITIES OF PRENATAL VAGINA MORPHOGENESIS CHARAKTERYSTYKA MORFOGENEZY POCHWYW OKRESIE PRENATALNYM	72
Sergii V. Popov, Oleksandr I. Smyian, Andrii N. Loboda, Olena K. Redko, Svitlana I. Bokova, Oleksandr P. Moshchych, Viktoriia O. Petraschenko, Svitlana N. Kasian, Olena V. Savchuk PECULIARITIES OF ANTIBIOTIC-ASSOCIATED DIARRHEA DEVELOPMENT IN CHILDREN WITH ACUTE RESPIRATORY INFECTIONS ODMIENNOŚCI ROZWOJU BIEGUNKI POANTYBIOTYKOWEJ U DZIECI Z OSTRYMI INFEKCIAMI GÓRNYCH DROG ODDECHOWYCH	79
Oleksandr A. Iaroshevskiy, Olga G. Morozova, Anna V. Logvinenko, Yana V. Lypynska NON-PHARMACOLOGICAL TREATMENT OF CHRONIC NECK-SHOULDER MYOFASCIAL PAIN IN PATIENTS WITH FORWARD HEAD POSTURE NIEFARMAKOLOGICZNE METODY LECZENIA PRZEWLEKŁEGO ZESPOŁU BÓLEWEGO MIĘŚNIOWO-POWIĘZIOWEGO SZYI I BARKU U PACJENTÓW Z POSTAWĄ GŁOWY PRZODUJĄCEJ	84
PRACE POGLĄDOWE / REVIEW ARTICLES	
Liudmyla I. Ostrovskaya MODERN APPROACHES TO PREVENTION OF PERIODONTAL DISEASES IN PREGNANCY: A REVIEW NOWOCZESNE STRATEGIE ZAPOBIEGANIA CHOROBYM PRZYJĘBIA W CIĄŻY: PRZEGLĄD LITERATURY	89
Nataliia V. Medvedovska, Valeriy I. Bugro, Ivan I. Kasianenko THE STUDY OF REGIONAL PECULIARITIES OF PARENTERAL VIRAL HEPATITIS INCIDENCE DYNAMICS AMONG CHILDREN AS AN INSTRUMENT OF DEVELOPING COMPLEX REGIONAL SOCIAL PROGRAMS ON THE PREVENTION OF ITS INCREASE BADANIE REGIONALNYCH ODMIENNOŚCI DYNAMIKI WYSTĘPOWANIA PARENTERALNEGO WIRUSOWEGO ZAPALENIA WĄTROBY U DZIECI JAKO NARZĘDZIE SŁUŻĄCE ROZWOJOWI KOMPLEKSOWYCH REGIONALNYCH SPOŁECZNYCH PROGRAMÓW MAJĄCYCH NA CELU ZAPOBIEGANIE WZROSTOWI TEGO TYPU ZAKAZEN	95
Olena O. Terzi THE GENESE OF PREDICTIVE-PERSONIFIED MEDICINE AND THE PROBLEMS OF ITS IMPLEMENTATION IN UKRAINE POWSTANIE PREDYKCYJNO-SPERSONALIZOWANEJ MEDYCYNY I PROBLEMY Z JEJ WDROŻENIEM NA UKRAINIE	99
Viktoriia O. Yaremchuk THE USE OF MEDICAL KNOWLEDGE IN THE CRIME INVESTIGATION WYKORZYSTANIE WIEDZY MEDYCZNEJ W DOCHODZENIACH KRYMINALISTYCZNYCH	103
Oleh G. Shekera THE FOUNDATION OF AN EFFECTIVE HEALTH CARE SYSTEM OF UKRAINE – FAMILY MEDICINE WPROWADZENIE SYSTEMU EFEKTYWNEJ OPIEKI MEDYCZNEJ NA UKRAINIE – MEDYCYNY RODZINNEJ	107
Piotr Feusette, Marek Gierlotka, Andrzej Tukiendorf, Joanna Płonka, Jarosław Bugajski, Beata Łabuz-Roszak, Robert Bryk NIEWYDOLNOŚĆ SERCA W WOJEWÓDZTWIE OPOLSKIM – EPIDEMIOLOGIA I PERSPEKTYWY NA PRZYSZŁOŚĆ HEART FAILURE IN OPOLE VOIVODESHIP – EPIDEMIOLOGY AND FUTURE PERSPECTIVES	112
Beata Łabuz-Roszak, Iwona Mańka-Gaca DYSFUNKCJA AUTONOMICZNEGO UKŁADU NERWOWEGO W PADACZCE DYSFUNCTION OF THE AUTONOMIC NERVOUS SYSTEM IN EPILEPSY	120
OPISY PRZYPADKU / CASE REPORTS	
Igor Alexander Harsch, Thomas Heß, Peter Christopher Konturek SEVERE METABOLIC SYNDROME AND PRIMARY AMENORRHEA AS MAIN PATHOPHYSIOLOGICAL FEATURES IN A SUBTYPE OF TURNER SYNDROME (46, X, DEL (X) Q 21) CIĘŻKA POSTAC ZESPOŁU METABOLICZNEGO I PIERWOTNY BRAK MIESIĄCZKI JAKO GŁÓWNE CECHY PATOFIZJOLOGICZNE W PODTYPIE ZESPOŁU TURNERA (46, X, DEL (X) Q 21)	124
Kateryna Tarianyk, Natalia Lytvynenko, Tetiana Purdenko, Viktoriia Hladka DIAGNOSTIC ERRORS DURING INTRAMEDULLAR PROCESSES BŁĘDY DIAGNOSTYCZNE W TRAKCIE OCENY PROCESÓW WEWNĄTRZDZIENIOWYCH	129
Veronika M. Dudnyk, Irina I. Andrikevych, Hennadiy M. Rudenko, Tetiana G. Korol, Kateryna V. Khromykh TROMBOSIS OF MESENTERIAL VESSELS IN ACUTE LYMPHOBLASTIC LEUKEMIA (CASE REPORT) ZAKRZEPICA NACZYŃ KREZKI W PRZEBIEGU OSTREJ BIAŁACZKI LIMFOBLASTYCZNEJ (OPIS PRZYPADKU)	133
Olga Wajtryt, Tadeusz M Zielonka, Aleksandra Kaszyńska, Andrzej Falkowski, Katarzyna Życińska ZESPOŁ KOUNISA - ALERGICZNY ZAWAŁ SERCA. OPIS PRZYPADKU KOUNIS SYNDROME - ALLERGIC MYOCARDIAL INFARCTION. A CASE REPORT	137

OPIS PRZYPADKU
CASE REPORT**TROMBOSIS OF MESENTERIAL VESSELS IN ACUTE LYMPHOBLASTIC LEUKEMIA (CASE REPORT)****ZAKRZEPICA NACZYŃ KREZKI W PRZEBIEGU OSTREJ BIAŁACZKI LIMFOBLASTYCZNEJ (OPIS PRZYPADKU)****Veronika M. Dudnyk, Irina I. Andrikevych, Hennadiy M. Rudenko, Tetiana G. Korol, Kateryna V. Khromykh**
VINNYTSA NATIONAL PYROGOV MEMORIAL MEDICAL UNIVERSITY, VINNYTSA, UKRAINE**ABSTRACT**

The article presents data on classification, diagnostic problems, treatment of acute lymphoblastic leukemia in children. Remaining unresolved problems of protocol chemotherapy complications of acute lymphoblastic leukemia. The presented clinical case of successful treatment of thrombosis of mesenteric vessels in a child with acute lymphoblastic leukemia, which included the stages of thrombolytic therapy and surgical treatment for resection of necrotized part of the ileum.

KEY WORDS: Acute lymphoblastic leukemia, chemotherapy, mesenteric thrombosis, children

Wiad Lek 2019, 72, 1, 133-136

INTRODUCTION

Acute lymphoblastic leukemia (ALL) is one of the most common malignant diseases of childhood and accounts for about 75% of all hemoblastosis. Often acute lymphoblastic leukemia affects children aged 2 to 5 years, mostly boys [1].

Diagnosis and modern classification of ALL based on studies of peripheral blood, liquor and bone marrow, namely cytological, cytochemical, cytogenetic and immunophenotyping. According to the results of a morphological study, 85% of patients have L1 variant by FAB (French-American-British classification). Majority of children, common-ALL and B-linear leukemia (85.8%) are diagnosed, whereas the proportion of prognostically unfavorable T-ALL is 14.2%, which is associated with an initial hyperleukocytosis, hepato-splenomegaly, and the presence of mediastinal tumor by immunophenotypic signs. The presence of cytogenetic translocations t(9;22) and t(4;11) are prognostically unfavorable and occur in 10-15% of patients. About 20% of affected children is genetically determined location translocation t(12;21) type EVI6/RUNX1, associated with initial low white blood cells (aleukemic and leukopenic form) and has a favorable prognosis [2].

Due to modern protocols of chemotherapeutic treatment of ALL has moved from the category of non-curable to potentially curable diseases [3]. However, these adverse factors as infectious and septic conditions, disease recurrence, development of secondary tumors, toxic effects of cytotoxic drugs and disturbances in the hemostatic system can lead to fatal consequences. To date, problems of diagnostics, treatment and prevention of ALL protocol chemotherapy complications remain incompletely solved [4].

Acute abdominal conditions are relatively rare, but potentially possible as complications in the treatment of ALL. Progress in the development of chemotherapeutic drugs led to an increase in the proportion of longer duration of remission and survival with improved blood transfusion, antibiotics and supportive care resulted in increased frequency of acute abdominal abnormalities in patients with leukemia [5]. One of the most severe complications that develops in children with hemoblastosis at the treatment stage is acute cerebrovascular disruption of mesenteric vessels, the treatment of which remains difficult and does not always result in a positive outcome for the patient [6].

The development of mesenteric thrombosis is due to the combination of the Virchow triad (blood flow disorders, hypercoagulation and inflammation of the vascular wall) and observed in 5.2% of patients with ALL at the treatment stage, of which 80% dominated by venous thrombosis and in 20% of patients - arterial vessels. In addition, in 58.3% of cases, thrombi occurs in the central nervous system (28.6% of the sinus thrombosis) and in the upper limbs, often due to the presence of a central venous catheter [7].

Modern studies have shown that malignant cells are involved in the formation of endothelial dysfunction, platelet activation and blood coagulation. Cytotoxic therapy is the main factor contributing to the development of thrombosis of mesenteric vessels and disorders in the hemostasis in children with ALL. Thus, corticosteroids and L-asparaginase induced hypercoagulation due to lower levels of natural anticoagulants, which requires the use of low fraction heparins for therapeutic or prophylactic purposes. Also, the pathogenesis of mesenteric blood vessel thrombosis may be due not only to the effect of chemotherapy,

but also to the congenital prothrombotic status of the patient, namely, the congenital antiphospholipid syndrome. For the diagnosis of thrombophilia, the most common laboratory tests indicating the causes of thrombosis are also used, namely: the mutation of the prothrombin G20210A and the gene of MTHFR, the antithrombin deficiency III, the deficiency of protein C, the hyperhomocysteinemia, the hypolipoproteinemia, the deficiency of protein S, the presence of antiphospholipid antibodies, the dysfibrinogenemia, the mutation V factor, an increase in the levels of factors VIII, IXa and XI [8].

In addition, an important factor that leads to thrombosis of mesenteric vessels is the disseminative intravascular clotting (DIC), which develops in patients with leukemia in the background of sepsis. During the last decade, molecular markers that are secreted in the nucleus of cells in acute cell lysis, which include the HMGB1 protein, are studied. This factor binds to chromatin when the integrity of the membrane of atypical cells is lost and isolated in the extracellular space, which acts on Toll-like receptors and leads to cell activation through MAP kinase. In case of sepsis this marker is an inflammatory cytokine. In addition, it activates the system of coagulation, inhibits anticoagulant protein C and stimulates the expression of tissue factors on monocytes, which leads to the development of the DIC [9].

Diagnosis of mesenteric blood vessel thrombosis is very complicated and requires careful analysis of clinical changes, laboratory and instrumental research methods. The main clinical manifestation of mesenteric thrombosis is an unbearable sharp abdominal pain, multiple vomiting, and emptying with impurities of the blood. The condition of the child is severe; the skin covers pale color with an earthy gray tint. Characteristic X-ray signs of mesenteric vessels thrombosis are pronounced intestinal pneumatosis, the absence of peristalsis and the Clyber bowl with horizontal levels. However, the most informative method of diagnosis is laparoscopy, which makes it possible to carefully and qualitatively evaluate the nature and prevalence of pathological changes in the intestine.

One of the methods of treating mesenteric thrombosis is surgical intervention with resection of the necrotic area of the intestine [10]. However, the indicators of postoperative and total mortality remain rather high and make up 65 - 85%, and with the development of peritonitis reach 90-100%.

CASE PRESENTATION

The child B. (girl), 4 years old, admitted to the oncohematological department of the regional children's clinical hospital on January 5, 2018 with complaints of general weakness, slipping, refusal of food, fever to 39°C, weight loss and pronounced pallor of the skin. The above listed complaints disturbed the child for a week. The objective examination revealed: the skin and mucous membranes are pale with hemorrhagic syndrome in the form of a petechial, non-symmetrical, polychrome rash localized on the trunk and the limbs. Increase in cervical and submucosal lymph nodes in diameter up to 1 cm, with a dense consistency were found. From the side of the cardiovascular and broncho-pulmonary system of pathology were not detected. The abdomen is symmetrical, takes part in the act of

breathing, the peristalsis is preserved, the liver and spleen are not enlarged, the physiological excrement is not affected. Diagnostics was performed according to the protocol ALL - BFM 2009: hematological blood test; bone marrow research, which included cytological, cytochemical, molecular genetic and immunophenotyping. Morphological study of cytocentrifugate of liquor and diagnosis: Acute lymphoblastic leukemia, FAB - variant L1, common - ALL type with coexpression of two myeloid antigens CD₁₃ and CD₃₃.

The child given an induction course of chemotherapy. From the first day of chemotherapy, the child received prednisone at a rate of 60 mg/m², against which background, regression of peripheral tumor mass and normalization of temperature indices observed. At day 8 hematological blood test was performed, where leukopenia was detected - 1.7×10⁹/l and the absence of blast cells in the leukocyte formula. In addition, the girl received infusion of Vincristine - 1.5 mg/m² and doxorubicin - 30 mg/m². On the 12th day of the induction course of treatment, the condition of the girl worsened, namely hyperthermia appeared, and leukopenia and neutropenia increased, which did not allow the continuation of the introduction of L-asparaginase. Taking into account signs of febrile neutropenia, an antibiotic and antitumor antibodies and human immunoglobulin intravenously administered. On the 15th day of protocol No. 1 a bone marrow test was performed, in which 2% of blasts were detected and a bone marrow remission was detected; an immunocytogenesis of bone marrow revealed a population of leukemic blasts, representing 4.03% of nucleated cells, which was consistent with the status of FMR (middle-risk group).

At day 18 of the induction course of chemotherapy, the child's condition deteriorated: fever and severe abdominal pain. Physical examination: pronounced pallor of the skin with earthy tint and hemorrhagic syndrome with polymorphic rash on the limbs, legs and anterior abdominal wall. Auscultation in the lungs vesicular breathing. Tones of the heart are rhythmic, tachycardia, systolic murmur. The abdomen is enlarged, painful in all parts, peristalsis sharply weakened. The liver + 3 cm, the spleen was not enlarged. Stool 1 times scanty. Urination is free, urine is light. Hematological blood analysis: anemia (Hb 65 g/l), leukopenia 1.2×10⁹/l, thrombocytopenia 10 thousand/μl. Laparoscopy performed for vital signs with revision and rehabilitation of the abdominal cavity, appendectomy, superimposition of enterostoma and cecostoma, took histological material for further morphological examination.

Intestinal wall swollen with a gray-black hue, no peristalsis and pulsation of blood vessels during examination of the abdominal cavity. From the abdominal cavity was evacuated about 2 liters of serous - hemorrhagic effusion, erythema, edema, vessels without pulsation, peritoneum in multiple hemorrhages (Figs 1 and 2).

Thrombosis of mesenteric vessels with total necrosis of the colon wall, hemorrhagic infarction and inflammatory infiltration detected at histological examination; significant edema and degenerative changes in the small intestine, with the presence of hypersecretion of mucus and desquamation of the epithelium in the mucous membrane.

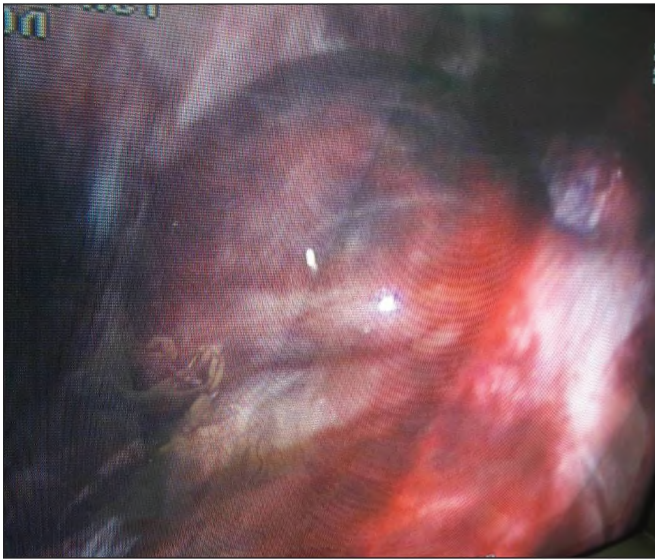


Fig. 1. Colon in mesenteric thrombosis

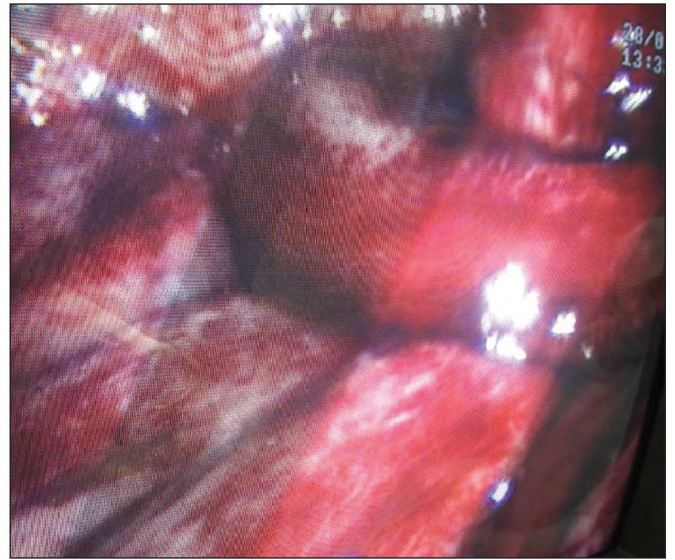


Fig. 2. Small intestine with mesenteric thrombosis

Table I. Dynamic of the hematology blood test in postoperative period

Units	27.01. 2018	28.01. 2018	29.01. 2018	30.01. 2018	31.01. 2018	01.02. 2018	02.02. 2018
Leukocytes *10 ⁹ /l	0.5	1.0	2.6	2.6	2.0	2.2	2.3
Hb, g/l	60	58	80	60	72	76	74
Platelets, thousand/ μ l	0	0	10	218	70	30	48

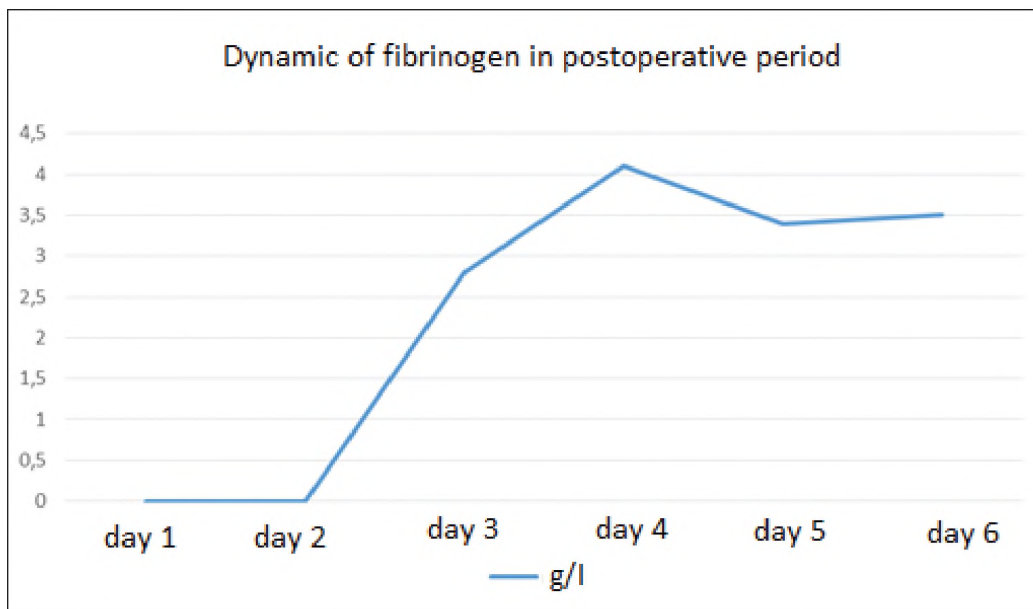


Fig. 3. Dynamics of fibrinogen indicators

In the postoperative period, the child's condition remained extremely severe, the severity was due to hemorrhagic syndrome (bleeding from postoperative wounds, hemorrhagic discharge on nasogastric probe and urinary catheter). In a dynamic study in blood hematological analysis anemia, leukopenia and thrombocytopenia preserved (Table I).

In the postoperative period, the child needed daily massive hemotransfusions of erythrocytes, platelets, and plasma. In addition, the girl received infusion therapy, antibacterial and antimycotic drugs, colony stimulating factor, Novoseven.

Test of secondary hemostasis: D-dimer 1.02 μ g (N-to 0.5 μ g), prothrombin time 12.8 seconds (N- 9.9-11.8 seconds), the inter-

national normalized ratio is 1.15 (N-1.0), activated partial thromboplastin time 40.7% (N- 22.7-31.8 seconds), thrombin time 18.8 seconds (N-14, 0-21.0 seconds), coagulation of the blood extended from 7 to 8 minutes hypocoagulation were observed. On the background of hemostatic therapy in the coagulogram, a positive dynamics of the fibrinogen indices observed (Fig. 1).

During the week, hemorrhagic syndrome was preserved due to thrombocytopenia and DIC, but after 10 days after surgery, it was possible to stop the bleeding, the patient's condition gradually improved, normalization of peripheral blood parameters.

To establish the presence of pathological changes in the mucous membrane of different parts of the gastrointestinal tract in the child, fibrogastroduodenoscopy and colonoscopy performed. In fibrogastroduodenoscopy, the esophagus and duodenum without pathological changes, while the mucous membrane of the stomach is hyperemic, with sharp erosions in diameter 0,2 - 0,3 cm without strain of fibrin. During colonoscopy in the direct, sigmoid and descending sections of the large intestine the mucous membrane is hyperemic with a blurred vascular pattern and multiple erosions in the diameter from 0.2 to 0.4 cm, which are covered with hemorrhagic stratification, in the lumen of the intestine, fibrinous-purulent contents. Endoscopic examination of the blind, ascending and transverse colon was also carried out through the preformed bowel movement. It was found that the mucous membranes of the cecum with cyanotic tint, contact with multiple erosions in the diameter of 0,2 - 0,3 cm covered with hemorrhagic contents. In the transverse colon, there were also isolated shallow erosions against the background of the pink mucosa.

CT scan of the abdominal cavity in the postoperative period: a small amount of free fluid and infiltration of the mesentery of the small intestine noted. True data in favor of thrombosis of mesenteric vessels not found. The transverse colon brought to the anterior abdominal wall. In the abdominal cavity on the left flank, as well as in the cavity of the small pelvis, tubular catheters.

Condition stabilized, confirmed bone and brain remission, which allowed to continue chemotherapy.

CONCLUSIONS

1. Acute lymphoblastic leukemia is the most common oncological disease of childhood, occurring in 75% of all hemoblastosis, of which the common-ALL-type is more commonly diagnosed, making up 85.8%.
2. Modern chemotherapy for acute lymphoblastic leukemia has transmitted this disease in a potentially curable one. However, chemotherapy needs further improvement aimed at reducing the toxicity of drugs and preventing severe complications.
3. In 5,2% of children, acute lymphoblastic leukemia is complicated by mesenteric thrombosis, in which the mortality is 65-85%.
4. The management of children with acute lymphoblastic leukemia requires careful examination of the hemostasis system in order to prevent the DICs syndrome.

REFERENCES

1. Lee JW, Cho B. Prognostic factors and treatment of paediatric acute lymphoblastic leukaemia. *Korean J Pediatr* 2017;6 0(5):129-137.
2. Jarosova M, Volejnikova J, Porizkova I, Holzerova M, Pospisilova D, Novak Z, Vrbkova J, Mihal V. Chromosomal aberrations in childhood acute lymphoblastic leukaemia: 15-year single center experience. *Haematology Am Soc Hematol Educ Program* 2016, 2(1):561-566.
3. van der Veer A, Zaliova M, Mottadelli F, De Lorenzo P, TeKronnie G, Harrison CJ, Cavé H, Trka J, Saha V, Schrappe M, Pieters R, Biondi A, Valsecchi MG, Stanulla M, den Boer ML, Cazzaniga G. IKZF1 status as a prognostic feature in BCR-ABL1- positive childhood ALL. *Blood* 2014; 123(11):1691-1698.
4. Stary J, Zimmermann M, Campbell M, Castillo L, Dibar E, Donska S, Gonzalez A, Izraeli S, Janic D, Jazbec J, Konja J, Kaiserova E, Kowalczyk J, Kovacs G, Li CK, Magyarosy E, Popa A, Stark B, Jabali Y, Trka J, Hrusak O, Riehm H, Masera G, Schrappe M. Intensive chemotherapy for childhood acute lymphoblastic leukaemia: results of the randomized intercontinental trial ALL IC-BFM 2002. *J Clin Oncol.* 2014 Jan 20;32(3):174-84.
5. Acute mesenteric ischemia: guidelines of the World Society of Emergency Surgery. Bala et al. *World Journal of Emergency Surgery* (2017) 12:38. DOI 10.1186/s13017-017-0150-5
6. C.J. Harrison, Blood spotlight on iAMP21 acute lymphoblastic leukemia (ALL), a high-risk pediatric disease, *Blood* 125 (9) (2015) 1383–1386.
7. S. Alexander, J.D. Pole, P. Gibson, et al., Classification of treatment-related mortality in children with cancer: a systematic assessment, *Lancet Oncol.* 16 (16) (2015) e604–610.
8. Mirjana Mitrovic et al. Thrombotic events in acute promyelocytic leukemia *Thrombosis Research* No 135 (2015) p. 588–593
9. Treatment for disseminated intravascular coagulation in patients with acute and chronic leukemia (Review) *Cochrane Database of Systematic Reviews* 2015, Issue 6. Art.No.: CD008562.DOI:10.1002/14651858.CD008562.pub3
10. Acute mesenteric ischemia: guidelines of the World Society of Emergency Surgery Bala et al. *World Journal of Emergency Surgery* (2017) 12:38 DOI 10.1186/s13017-017-0150-5

Authors' contributions:

According to the order of the Authorship.

Conflict of interest:

The Authors declare no conflict of interest.

CORRESPONDING AUTHOR

Kateryna V. Khromykh

Vinnytsa National Pyrogov Memorial Medical University
56 Pirihovala St., 21018, Vinnytsa, Ukraine
e-mail: kate_khromykh@yahoo.com

Received: 23.07.2018

Accepted: 25.11.2018