

При изготовлении гистологических препаратов, предварительно проводили декальцинацию сегментов челюстей с последующей окраской гематоксилином, эозином и азаном. Установлено, что действие опиоида в малых дозах в течение 6 недель, приводит к очаговому поражению мягких тканей пародонта и формирование пародонтального кармана, с распространением воспалительного процесса на твердые ткани пародонта. Наряду с этим отмечали признаки защитных и компенсаторно-приспособительных реакций.

Ключевые слова: опиоид, крысы, пародонт, микроскопическое исследование.

Статья надійшла: 20.01.18 р.

decalcification of jaw segments was performed followed by staining with hematoxylin, eosin and azan in the manufacture of histological preparations. It was defined that the action of opioid in small doses for 6 weeks leads to focal lesions of soft periodontal tissues and the formation of the periodontal pocket with the spread of the inflammatory process to hard periodontal tissues. Simultaneously, signs of protective and compensatory-adaptive reactions were marked.

Key words : opioid, rats, periodontium, microscopic examination.

Рецензент Єрошенко Г.А.

DOI 10.26724/2079-8334-2018-4-66-222-226

УДК: 616.716.4-001.5+616.156-001

R.L. Furman, A.S. Barilo, S.S. Polishchuk, N.M. Isakova, A.M. Yur, T.M. Kamishyna
National Pirogov Memorial Medical University, Vinnytsia

TREATMENT OF PAIN SYNDROME IN PATIENTS WITH MANDIBLE FRACTURES BY MEANS OF RESTORATIVE THERAPY

E-mail: furmanruslan1977@gmail.com

The purpose of the study was a comprehensive assessment of the pain syndrome major indices in patients with mandibular fractures accompanied by injury of the inferior alveolar nerve using conventional therapeutic regimen supplemented by the administration of drug product Nucleo CMP Forte. Decrease of pain syndrome was revealed in both groups but with different dynamic pattern. At the beginning of the study LANSS scale indices were nearly identical in both groups, while on the 7th and 14th day they were 1.35 and 2.03 times lower, respectively, in treatment group than in comparison group. On the first day NTSS-9 scale values did not practically differ in studied patients, being somewhat higher in treatment group. On the 7th and 14th day the values were 1.24 and 3.82 times better, respectively, in treatment group than in the group of comparison. The analysis of dynamic pattern of complaints as well as the objective findings in angular fractures of the mandible, accompanied by the damage of inferior alveolar nerve, demonstrated that the administration of drug product Nucleo CMP Forte accelerated the regression of pain syndrome in the course of treatment.

Key words: mandibular fractures, pain syndrome, pain scale indices, inferior alveolar nerve.

The work is a fragment of the research project "Development of methods for comprehensive treatment of patients with maxillofacial area pathological processes of different etiologies, with account of individual features", state registration No. 0114U00020.

Injuries of the facial bones hold a special place among mechanical skeletal injuries due to their anatomic features, and because of high incidence of severe functional and cosmetic disorders which follow them. In recent years an increase of traumatism in general is seen both in Ukraine and abroad, including the incidence of dentofacial injuries. It should be noted that persons with dentofacial injuries make 20-40% of all dental surgery in-patients, and mandibular bone injury is considered to be the most common pathology (72-91.9% of all cases of facial bone fractures in peacetime [15, 8, 9]).

The fractures of mandibular body are associated with the damage of inferior alveolar nerve – the largest branch of mandibular nerve, passing in the mandibular bone canal of the same name. This nerve is the peripheral branch of trigeminal nerve, and its injury causes a number of physiologic and morphologic changes in facial tissues and oral cavity organs. The damage of this branch of trigeminal nerve in mandibular fractures can over time be manifested by severe paroxysmal facial pains. Peripheral nerve injury is accompanied by different sense disorders in the corresponding innervation zone, the development of pain syndrome of various intensity as well as frequent emotional and stress disorders [13, 10, 7, 14]. Most of injuries are associated with pain syndrome of various degree of severity. The diagnostics of neurodental diseases is a great challenge in maxillofacial surgery, the main clinical manifestation of them being pain syndrome and neurologic disorders in dentofacial region [4, 1, 6]. Neuropathic pain (NP) develops due to the damage of different divisions of somatosensory nervous system. It can also be caused by the damage of afferent somatosensory system at any level, from peripheral sensory nerves to cerebral cortex, as well as by disturbances in descending antinociceptive systems. Neuropathic component is thought to support long-term pain in traumas, when the pain itself is caused by inflammatory changes in the local region. NP develops due to the damage or dysfunction of the system transmitting pain signal in the normal condition. Disorders associated with NP development belong to heterogeneous group of diseases with the involvement of peripheral and central nervous systems. Pathophysiologic basis for neuropathic pain is neuron hyperexcitation occurring as a result of plastic changes in the structures involved

in transmission and processing of nociceptive signals. NP can greatly influence the person's quality of life. It often poorly responds to treatment because of its resistance to many drugs and is followed by side effects despite effective drug therapy. Neuropathic pain, developing due to the damage or dysfunction of peripheral and central nervous system structures, as opposed to nociceptive (physiologic) pain in body tissue injury, is not protective by character, but it is chronic desadaptative state accompanied by sensor, vegetative and trophic disorders [12, 2, 5].

The patients hospitalized with mandibular fractures are usually administered no adequate drug therapy, aimed at the rehabilitation of the damaged inferior alveolar nerve, or its administration is rather delayed, thus being ineffective. Taking into consideration rather high prevalence of pain syndrome, its influence on working capacity, activity, quality of life, disability and great economic expenditures, need for study of this urgent problem becomes obvious [3, 11].

Because of the fact that neuropathic pain can develop in orthodontic treatment, partial and complete removable dentures as well, the study of new methods of treatment of this pathology and their introduction into clinical practice seems to be one of the promising fields of research in dentistry.

The purpose of the study was a comprehensive assessment of major pain syndrome indices in patients with mandibular fractures accompanied by the inferior alveolar nerve injury in conventional therapeutic regimen supplemented by administration of drug product Nucleo CMP Forte.

Materials and methods. To achieve the target goal, operative and postoperative treatment was performed to 50 patients (46 males and 4 females) with angular fractures of the mandible accompanied by the clinical signs of inferior alveolar nerve damage. The study was carried out at the Department of Maxillofacial Surgery of Vinnytsia City First Aid Hospital and Dentofacial Department of Vinnytsia Regional Clinical Hospital named after M.I.Pirogov from September, 2015 to October, 2017.

The patients with angular fractures (isolated unilateral, combined bilateral) with no clinical manifestations of contralateral nerve damage were selected for adequate processing of the data obtained. There was either no bone dislocation in the patients or it measured to 1 cm. Due to its elasticity and mobility, no complete rupture of inferior alveolar nerve in non-ballistic angular mandibular fractures occurs.

The patients were divided into two clinical groups – treatment group and comparison group. Treatment group consisted of 25 patients (23 males and 2 females) 18 to 31 years of age (average age 24.9 years). Those patients underwent conventional range of therapeutic measures including the operation for bone fragment reposition and splinting of both jaws, 10 day parenteral (i/m) administration of broad-spectrum antibiotic (ceftriaxone) and non-steroid anti-inflammatory drug (diclofenac) as well as additional administration of 10 parenteral (i/m) injections of drug product Nucleo CMP Forte in the dose of 3 ml once a day. The average duration of in-patient treatment was 13.5 days.

The subjects of comparison group were 25 patients (23 males and 2 females), 19 to 30 years of age (average age 24.6 years). Those patients underwent conventional management including bone fragment reposition and splinting of both jaws, 10 day parenteral (i/m) administration of broad-spectrum antibiotic (ceftriaxone) and non-steroid anti-inflammatory drug (diclofenac). The average duration of hospital stay was 14.4 days.

The severity of pain syndrome and neuropathy symptoms was evaluated using the LANSS pain scale, questionnaire DN4, the Visual Analogue Scale (VAS) (assessment of subjective feelings of pain intensity) and Neuropathy Total Symptom Scores (NTSS-9).

The LANSS Pain scale (Leeds Assessment of Neuropathic Symptoms and Signs, M.Bennett, 2001). The grading scale of neuropathic symptoms and signs. According to this scale the patient is asked 5 questions concerning the intensity and character of his pain; the signs of allodynia and impaired sensitivity in innervation zone are detected as well. Every question has the corresponding value in scores. To receive the total value, the parameters of sensor descriptors and sensitivity tests are summarized. The maximal value is 24. If the sum is <12, neuropathic mechanisms of pain development are unlikely. If the sum is >12, neuropathic mechanisms of pain formation are probable.

DN4 Questionnaire - for diagnostics of neuropathic pain, Bouhassira D, et al., 2005. According to DN4 questionnaire method, assessment interview with the patient is conducted. The questionnaire consists of two blocks of questions: the first one (7 items) is filled in by the examiner after interviewing the patient, and the second one (3 items) – after clinical examination of the patient. The first block evaluates such positive sensory symptoms as spontaneous pain (burning sensation, sensation of coldness, electric shock sensation), paresthesia and dysesthesia (“skin crawling”, tingling, numbness, pruritus). The second block helps to reveal allodynia and negative sensory symptoms. If the score is 4 or higher, the pain is of neuropathic origin. If the score is less than 4, the pain is unlikely to be neuropathic pain. Maximal score is 10.

The Visual Analogue Scale (VAS) (Huskisson E. C., 1974). This is a subjective assessment method of pain severity when the patient is asked to mark with a pen the point on the non-graded 10 cm line that best describes his pain intensity. The left boundary corresponds to “0” (absence of pain), the right one – to “10” (unbearable pain). Usually 10 cm paper, cardboard or plastic ruler is used for this purpose. On the back of the

ruler centimeter divisions are made, by which the doctor registers the values obtained in the examination chart. One of the major advantages of this scale is its ease of administration. In dynamic assessment the change in pain intensity is considered objective and significant, if the actual VAS value differs from the previous one by more than 13 mm. The Visual Analogue Scale reflects the intensity of pain experienced by the patient at the time of examination. Pain intensity is marked by the patient himself. As to its disadvantages, VAS scale is a unidimensional measure of pain intensity, i.e. only pain intensity can be determined by this scale. Because of this, other methods of pain assessment are usually used in studies as well.

Neuropathy Total Symptom Scores (NTSS-9). NTSS-9 scale measures symptoms for the previous 24 hours. The scale can be used to evaluate a number of symptoms developing in patients with traumatic damage of inferior alveolar nerve. The severity and frequency of such symptoms as shooting pain, burning sensation, aching pain, allodynia (a painful response to normally innocuous stimulus), static hyperalgesia, tingling, numbness, sensation of coldness in the zone of inferior alveolar nerve innervation, cramps (mimic muscle twitching) can be assessed both separately and in combination. The sum of all symptom indices is used for comprehensive evaluation of neuropathy symptoms by NTSS-9 scale.

The studies were carried out for three times during the period of treatment: on admission (the first day), on the 7th and 14th days of treatment. The patients were required to undergo a course of treatment without analgesics because of analgesic effect of diclofenac, which could confound the study results. The examination was carried out in the following way: at the day of admission - within the shortest possible time prior to drug prescription, on the 7th and 14th days of treatment - in the morning prior to medicinal manipulations (not less than 6 hours after the previous drug administration).

As the antimicrobial drug included in therapeutic complex had no influence on the study results, it was used according to conventional treatment regimen equally in treatment group and in the group of comparison.

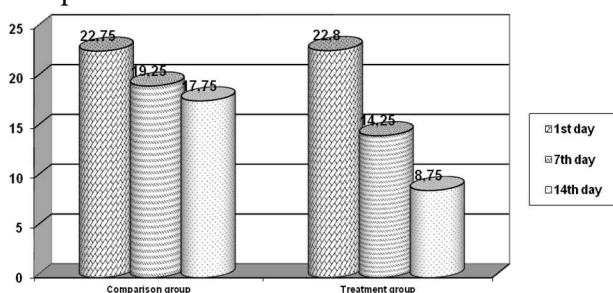


Fig. 1. LANSS pain scale indices.

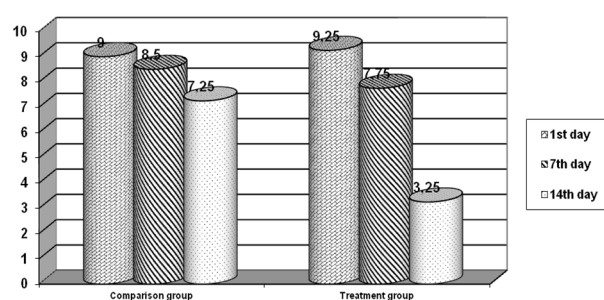


Fig. 2. DN 4 questionnaire indices.

Results of the study and their discussion. The following data were obtained after the analysis of study results. The signs of allodynia, impaired sensitivity in the innervation zone as well as the intensity and character of the pain were established using the LANSS pain scale. Decreased scale indices were revealed in both groups indicating the reduction of pain syndrome. It is not surprising, because acute period (1-3days) is followed by regeneration in the fracture zone, if no inflammatory complications develop, leading to the decrease of pain syndrome. But the reduction of pain intensity was not the same in two groups (fig.1).

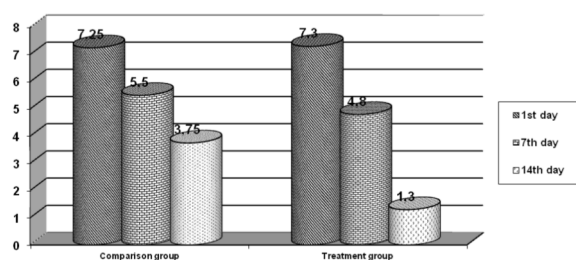


Fig. 3. Dynamic pattern of VAS indices.

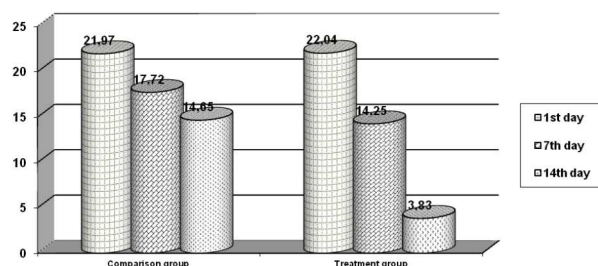


Fig. 4. NTSS - 9 scale indices.

At the beginning of the study the indices were nearly equal in both groups, but on the 7th and 14th days they were 1.35 and 2.03 times lower, respectively, in treatment group than in the group of comparison.

The analysis of DN 4 questionnaire data found the following pattern of relationship (fig.2).

At the beginning of the study practically no differences in the indices between groups were revealed, moreover, they were somewhat higher in treatment group. On the 7th day the difference was insignificant (the values were 2.03 times lower in treatment group). But on the 14th day there was significant difference in the indices – 2.23 times lower in treatment group than in the group of comparison.

The next diagram (fig 3) shows the tendency of VAS (Visual Analogue Scale) indices to decrease both in treatment group and in the group of comparison.

Significantly more rapid decrease of pain was revealed in treatment group. On admission the indices in that group were similar to those in the group of comparison, they were 1.15 times lower on the 7th day, being insignificantly different. But on the 14th day VAS indices were 2.9 times lower than those in comparison group.

Examination data obtained by Neuropathy Total Symptom Scale (NTSS-9) are presented in table 1 and fig.4.

Table 1

Neuropathy Total Symptom Scale (NTSS - 9)		
Days	Group of comparison	Treatment group
First day	21.97±0.98	22.04±0.95
7 th day	17.72±3.39	14.25±1.55
14 th day	14.65±2.89	3.83±0.53

Clear-cut differences between the groups are seen in the improvement of the patients' state. It is obvious, that on the first day the indices were similar, being even somewhat higher in treatment group. On the 7th day the indices were 1.24 times lower and on the 14th day - 3.82 times lower in treatment group than in the group of comparison.

Since LANSS, DN4, VAS and NTSS-9 scales characterize pain syndrome from various perspectives, the results were different with existing similar tendency.

Conclusions

1. Thus, having analyzed the dynamics of patients' complaints as well as the objective data in angular fractures of the mandible accompanied by the inferior alveolar nerve damage, the administration of drug product Nucleo CMP Forte was found to accelerate the regression of pain syndrome in the course of treatment.

2. The drug significantly decreased the severity of all neuropathy manifestations, associated with the inferior alveolar nerve damage: shooting pain, burning sensation, aching pain, allodynia (aberrant pain), static hyperalgesia, tingling, numbness, sensation of coldness, cramps (twitching).

3. The patients benefited subjectively and clinically from the treatment with Nucleo CMP Forte. Because of the fact that neuropathic pain can develop in orthodontic treatment, partial and complete removable dentures as well, the administration of drug product Nucleo CMP Forte is warranted in combined therapy of both mandibular fractures, followed by clinical signs of inferior alveolar nerve damage, and neuropathic pain in orthodontics and orthopedic stomatology.

References

1. Bobyriov VM, Petrova TA, Ostrovska GYu, Mulyar LA, Kolot EG. Pryntsyppyy zastosuvannya nenarkotychnykh analgetykyv v stomatolohichniy praktytsi. Visnik problem biolohiyi i medytsyny. 2016; 2, 1 (128):164-167. [in Ukrainian]
2. Bystrov NK, Bystrova EL. Effektivnost primeneniya preparata Ketorol® v stomatologicheskoy praktike. Stomatolog praktik. 2014; 3:26-28. [in Russian]
3. Katilov OV, Bandurka NM, Dmitriev DV, Layko LI. Mehanizmy bolyu i osoblyvosti diagnostyky boliovykh syndromiv u ditey. Visnik Vinnytskoho natsionalnoho medychnoho universytetu. 2015; 1, 19:224-229. [in Ukrainian]
4. Krazhan SN, Gandylyan KS, Sharipov EM, Volkov EV, Pismenova NN. Mestnoye obezbolivanie i anesteziologiya v stomatologii: uchebnoe posobie. Stavropol: izdatelstvo StGMU. 2014; 202s. [in Russian]
5. Mazur IP, Suprunovich IM. Zastosuvannya preparatu «Orasept» v kompleksnomu likuvanni zakhvoryuvan parodonta. Dentaklub. 2016; 9:9-10. [in Ukrainian]
6. Nidzelskyi MYa, Tsvetkova NV, Sokolovska VM. Profilaktyka bolioвого syndromu pry korystuvanni znimnyy protezamy. Ukrayinsky stomatolohichniy almanakh. 2017; 3:26-28. [in Ukrainian]
7. Ogonovskiy RZ, Paterega NI. Zastosuvannya flyukturuyuchykh strumiv u stomatolohiyi i shchelepno-lytsevyi khirurhiyi (oglyad literatury). Bukovynskiy medychnyi visnyk. 2015; 19, 4 (76):223-226. [in Ukrainian]
8. Pshyk SS, Bozhenko NL, Pshyk RS, Bozhenko IM. Miofastsialnyi boliovyi syndrom – Deyaki aspekty diahnostryky ta likuvannya. Lvivskiy klinichnyi visnyk 2013; 3(3):52-56. [in Ukrainian]
9. Sidelnikova LF, Kolenko YuG, Grig NI. Obosnovanie vybora optimalnoy terapii pri lechenii boli i vospaleniya v stomatologicheskoy praktike. Sovremennaya stomatologiya. 2013; 4:17-21. [in Russian]
10. Fleysher GM. Analgeticheskoye deystviye Ketorola® pri bolevom syndrome v stomatologicheskoy praktike. Stomatolog praktik. 2014; 2:40-42. [in Russian]
11. Furman RL, Barylo OS, Korol AP. Kliniko-eksperymentalne doslidzhennya efektyvnosti vykorystannya Nucleo C.M.P. forte pry travmakh nerva. Scientific Journal «ScienceRise: Medical Science» 2016; 6(2):57-63. [in Ukrainian]
12. Czajkowska D, Lisiński P, Samborski W. Terapia manualna w leczeniu zespołu bólu mięśniowo-powięziowego w przebiegu bruksizmu. Dental forum. 2013; 41(1):57-64.
13. Pigg M, Svensson P, Drangsholt M, List T. Seven-year follow-up of patients diagnoses with atypical odontalgia: A prospective study. J Orofac pain. 2013; 27:151-164.
14. Todorovic L. Patient with Chronic Orofacial Pain in a Private Dental Office - Diagnostic Dilemmas. Balk J Dent Med. 2016; 20(2):78-82.
15. Zakrzewska JM. Differential diagnosis of facial pain and guidelines for management. British Journal of Anaesthesia. 2013; 111 (1):95-104.

Реферати**ЛІКУВАННЯ БОЛЬОВОГО СИНДРОМУ У ХВОРИХ З ПЕРЕЛОМАМИ НИЖНЬОЇ ЩЕЛЕПИ ЗАСОБАМИ РЕСТАРАТИВНОЇ ТЕРАПІЇ**

Фурман Р.Л., Барило А.С., Поліщук С.С., Ісакова Н.М., Юр А.М., Канишна Т.М.

Метою дослідження була комплексна оцінка основних показників больового синдрому у пацієнтів з переломами нижньої щелепи, що супроводжуються пошкодженням нижнього альвеолярного нерва, за допомогою звичайного терапевтичного режиму, доповненого застосуванням препарату Нуклео ЦМФ форте. Проведено оперативне і післяопераційне лікування 50 пацієнтів з кутовими переломами нижньої щелепи, що супроводжувалися клінічними проявами ушкодження нижнього альвеолярного нерва. Зниження больового синдрому виявлено в обох групах, але з різною динамікою. На початковому етапі дослідження показники шкали LANSS були майже однаковими в обох групах, тоді як в основній групі на 7-й і 14-й день вони становили 1,35 і 2,03 рази нижчі, відповідно, ніж у групі порівняння. У перший день значення шкали NTSS-9 практично не відрізнялися у досліджуваних пацієнтів, і були дещо вище в основній групі. На 7-й і 14-й день значення в 1,24 та 3,82 рази було краще, ніж в групі порівняння. Аналіз динамічної картини скарг, а також об'єктивні висновки при кутових переломах нижньої щелепи, що супроводжується пошкодженням нижнього альвеолярного нерва, показали, що введення препарату Нуклео ЦМФ форте прискорило регресію больового синдрому в ході лікування.

Ключові слова: переломи нижньої щелепи, больовий синдром, показники за шкалою болю, нижній альвеолярний нерв.

Стаття надійшла 25.05.18 р.

ЛЕЧЕНИЕ БОЛЕВОГО СИНДРОМА У БОЛЬНЫХ С ПЕРЕЛОМАМИ НИЖНЕЙ ЧЕЛЮСТИ СРЕДСТВАМИ РЕСТАРАТИВНОЙ ТЕРАПИИ

Фурман Р.Л., Барило А.С., Полищук С.С., Исакова Н.Н., Юр А.М., Канишная Т.М.

Целью исследования была комплексная оценка основных показателей болевого синдрома у пациентов с переломами нижней челюсти, сопровождающихся повреждением нижнего альвеолярного нерва, с помощью обычного терапевтического режима, дополненного применением препарата Нуклео ЦМФ форте. Проведено оперативное и послеоперационное лечение 50 пациентов с угловыми переломами нижней челюсти, что сопровождалось клиническими проявлениями повреждения нижнего альвеолярного нерва. Снижение болевого синдрома выявлено в обеих группах, но с разной динамикой. На начальном этапе исследования показатели шкалы LANSS были почти одинаковыми в обеих группах, тогда как в основной группе на 7-й и 14-й день они составляли в 1,35 и 2,03 раза ниже, соответственно, чем в группе сравнения. В первый день значение шкалы NTSS-9 практически не отличались в исследуемых пациентах, и были несколько выше в основной группе. На 7-й и 14-й день значение в 1,24 и 3,82 раза было лучше, чем в группе сравнения. Анализ динамической картины жалоб, а также объективные выводы при угловых переломах нижней челюсти, сопровождающийся повреждением нижнего альвеолярного нерва, показали, что введение препарата Нуклео ЦМФ форте ускорило регрессию болевого синдрома в ходе лечения.

Ключевые слова: переломы нижней челюсти, болевой синдром, показатели по шкале боли, нижний альвеолярный нерв

Рецензент Єрошенко Г.А.

DOI 10.26724/2079-8334-2018-4-66-226-231

УДК 611.31.013:611.716.4.018

О.В. Цигикало, С.Ю. Палис

ВДНЗ України «Буковинський державний медичний університет», Чернівці

ОСОБЛИВОСТІ МОРФОГЕНЕЗУ ТА ВАРІАНТНОЇ АНАТОМІЇ НИЖНЬОЇ ЩЕЛЕПИ У ПЛОДІВ ЛЮДИНИ

palissegre@gmail.com

З метою з'ясування закономірностей морфогенезу, варіантної анатомії та особливостей динаміки просторово-часових змін будови нижньої щелепи у ранньому періоді онтогенезу людини досліджено 60 препаратів плодів людини 160,0-450,0 мм тім'яно-куприкової довжини (4-9-й місяці внутрішньоутробного розвитку) із застосуванням комплексу традиційних і новітніх методів морфологічного дослідження (антропометрія, комп'ютерна томографія, морфометрія, виготовлення серій послідовних гістологічних зрізів, мікроскопія, тривимірне комп'ютерне реконструювання, статистичний аналіз). Встановлені закономірності індивідуальної анатомічної мінливості, статево-вікові та конституційні особливості будови нижньої щелепи в плодovому періоді онтогенезу людини. Визначені критичні періоди морфогенезу нижньої щелепи в пренатальному періоді онтогенезу людини. Створено реконструктивні та математичні моделі нижньої щелепи для з'ясування її функціональної морфології та ембріотопографії.

Ключові слова: нижня щелепа, плід, внутрішньоутробний розвиток, людина.

Наукове дослідження є фрагментом планової комплексної НДР «Закономірності морфогенезу та структурно-функціональні особливості тканин і органів в онтогенезі людини», № державної реєстрації 0116U002938.

З'ясування джерел, вивчення хронологічної послідовності основних етапів ембріогенезу та з'ясування особливостей будови нижньої щелепи у віковій динаміці її розвитку є актуальним завданням морфології, розв'язання якого дозволить розробити нові та удосконалити існуючі заходи профілактики, методи ранньої діагностики та хірургічної корекції природжених вад нижньої щелепи людини [1]. Аномалії розвитку щелепно-лицевої ділянки людини посідають третє місце серед природжених вад. В Україні щороку народжується близько 600 дітей з вадами щелепно-лицевої ділянки, у середньому по кожній з областей – від 15 до 46 випадків на рік [4, 6]. Косметичні порушення, які є зазвичай наслідком природжених щелепно-лицевих деформацій, можна віднести