

MD

MEDICAL

Medicinska
revija

DATA

medical
review

ISSN 1821-1585

Vol.5 /Nº3 /2013. Septembar/Septembre

<http://scindeks.nb.rs/issue.aspx?issue=9142&lang=en>

<http://scindeks.nb.rs/issue.aspx?issue=9142&lang=sr>

www.md-medicaldata.com



IZDAVAČKI SAVET / EDITORIAL ADVISORY BOARD

Akademik/Academician **Vladimir Kanjuh**, SANU, AMN-SLD

Akademik/Academician **Antonije Škokljev**, MANU, AMN-SLD

UREĐIVAČKI ODBOR / EDITORIAL BOARD

Glavni i odgovorni urednik/Editor-in-Chief

Prof. dr sc. med. **Petar Spasić**, AMN-SLD

Zamenik glavnog i odgovornog urednika/Deputy Editor-in-Chief

Prof. dr sc. med. **Dušan Lalošević**, AMN-SLD

*Originalni članci/
Original articles*

PHYLOGENETIC AND ONTOGENETIC
PECULIARITIES OF DEVELOPMENT AND
ANATOMY OF THE MANDIBULAR MENTAL
REGION

Correspondence to:

Prof. Sergei Mykhailovich Shuvalov,
MD, PhD

Department of oral and maxillofacial
surgery (head of the department – Prof.
Shuvalov S. M.), Vinnitsa National
Medical University named after N. I.
Pirogov,
Pirogov str. 56, Vinnitsa 21018, Ukraine,
Tel. +380974802342
E-mail address: dr_shuvalov@mail.ru

FILOGENETSKE I ONTOGENETSKE
SPECIFIČNOSTI RAZVOJA I ANATOMIJE
MENTALNE REGIJE DONJE VILICE

Sergei Mykhailovich Shuvalov¹, Olesia Viktorovna
Bedyk¹, Milan Knezevic² and Gordana Andjelic³

¹Department of oral and maxillofacial surgery (head of the department –
Prof. Shuvalov S. M.), Vinnitsa National Medical University named after
N. I. Pirogov, Pirogov str. 56, Vinnitsa 21018, Ukraine,

²Faculty of Medicine and Public Health Sciences ULPGC, Hospital
Universitario Insular, Las Palmas, Spain,

³Institute for Medical Research, Military Medical Academy, Belgrade,
Serbia

Key words

mandible, chin, sublingual artery,
sublingual nerve

Ključne reči

donja vilica, brada, podjezična arterija,
podjezični živac

Abstract

This study examined the peculiarities of anatomy, blood supply, and innervation of the bone of mental region and the surrounding soft tissues, together with the development of chin in phylogenesis and ontogenesis. In addition, a comparative anatomical study of the innervation and blood supply of the bone and surrounding soft tissues in humans and animals was conducted.

The conclusions of this research are as follows: the chin itself should be considered as a small area of bone with a triangular shape at the frontal part of the mandible. Its occurrence in humans can be attributed to an upright posture. During the formation of the foetus, this bone is formed from the separate centres of ossification, and for a long time period, it is presented separately from the mandible. The innervation and blood supply of the chin's protrusion are provided primarily by the sublingual arteries and nerves, which have special foramina on the lingual surface of the mandible. Knowledge of these peculiarities is necessary during the performance of local anaesthesia, implant placement, genioplasty, and in the treatment of fractures of the mental region of the mandible.

INTRODUCTION

Maxillofacial surgeons are increasingly interested in the anatomy of mandibular mental region nowadays. The range of possible operations in the chin area is pretty wide, and many periodontal surgical manipulations with different vestibular accesses in this area are developed. Labial incisions in the area of the anterior part of the mandible are used also for genioplasty ⁽¹⁾ and for the performance of intraoral transmental suction lipectomy ⁽²⁾. Bone blocks from the mental area are used as grafts for alveolar bone augmentation in the frontal part of the maxilla ⁽³⁾, and corticocancellous autografts from the chin are used to graft alveolar clefts ⁽⁴⁾. This area of the mandible is also one of the sites for the

fixation of intraoral distractors and the subsequent transversal expansion of the mandible ⁽⁵⁾.

Mandibular mental fractures healing peculiarities were specified by Rauer ⁽⁶⁾, Habal and Ariyan ⁽⁷⁾, and Malyshev and Kabakov ⁽⁸⁾. However, the anatomy of this area has not been sufficiently studied, therefore difficulties in the investigation of the innervation and blood supply are frequent. They are related to the limited anatomical access for the study of the terminal vessels, nerves and bone connections in the midline.

The aim of this paper was to study the peculiarities of the anatomy, blood supply, and innervation of the chin bone and the surrounding soft tissues, along with the development of the chin in phylogenesis and ontogenesis. This study also

sought to determine the usefulness of these data for oral surgeons by conducting a comparative anatomical study of the innervation and blood supply of the bone and surrounding soft tissues in humans and animals.

MATERIALS AND METHODS

A topographic-anatomical study of the mental area was performed at the Department of Anatomy, Bukovina State Medical University and the Department of Anatomy, Vinnitsa National Medical University, named after N. I. Pirogov (Ukraine). Anatomical specimens of four aborted fetuses after 10-14 weeks of development (approximately 2.5-3.5 months), six aborted fetuses after 24-26 weeks of development (approximately 6-6.6 months), and 4 dead new-borns born on time (in total 14 cadavers) were investigated to study the development of the "proper chin area."

To study the blood supply and innervation of this area, the sublingual areas and the bone of the front portion of the mandible of 8 human cadavers were dissected. Computed tomograms of 23 patients were studied to determine the extraosseous nutritional foramina on the lingual surface of the mandible. To specify the innervation zones on the skin of the chin area and the lower lip, 7 patients received an inferior alveolar nerve block, and 12 patients received an inferior alveolar nerve block together with a mylohyoid nerve block, according to the methods of Clark et al. (9).

The dissection of 6 pig heads and 5 calf heads was performed for the comparative anatomical study of the directions of the vessels and nerves in animals and humans.

RESULTS

Development of the chin

We assume that the appearance of the chin in humans could be the result of the human upright posture. This configuration is most likely necessary for the fixation of the genioglossal, geniohyoid and digastric muscles, which are also fixed to the hyoid bone and are used to support the entire pharynx-laryngeal complex. A lower position of the larynx and pharynx, which facilitates speech formation in humans, requires a more stable and strong fixation to the chin.

Evolutionarily, the „proper chin" should refer to the small triangular area in the front region of the mandible, not the area between the mental foramina, as it is considered traditionally.

During the dissection of the mandibles of 3-month and 6-month fetuses, a triangular area of bone with sloping sides on the vestibular surface, with no bony connection to the body of the mandible and easily separated from it, was identified (Figures 1, 2, 3). During the dissection of mandibles of new-borns, the freely lying "chin bone" was not found, but its contours together with an initial fibrous fusion to the body of the mandible were clearly defined. This "proper chin bone" was easily separated with a rasp strictly on the line of junction with the body of the jaw. In a new-born, the two parts of the mandible are fused with fibrous tissue, and the fusion is not linear but appears as an inverted "Y", as the site of the future chin protrusion is not fully connected to the body of the jaw (Figure 4).

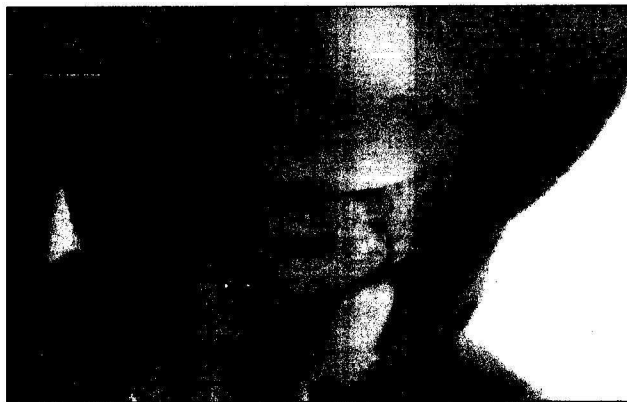

Figure 1. "The proper chin bone" in a 3-month-old foetus.



Figure 2. "The proper chin bone" in a 6-month-old foetus connected to the body of the mandible.

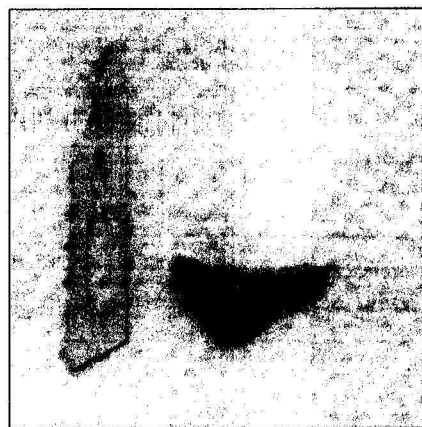


Figure 3. "The proper chin bone" from a 6-month-old foetus. The chin bone is easily separated from the mandible.

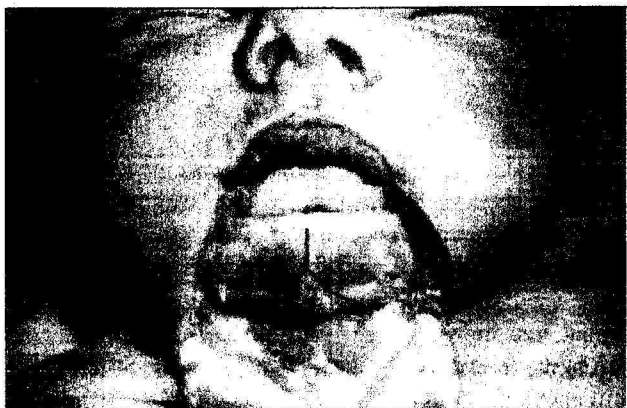

Figure 4. Chin area in a new-born.

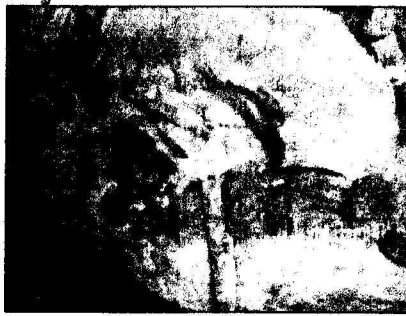

Figure 5. The branches of the sublingual arteries that enter the bone of the chin from the lingual side through the corresponding openings.

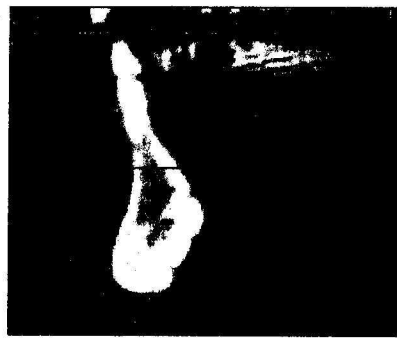


Figure 6. Superior and inferior lingual foramina and canals on computed tomography images.



Figure 7. Branches of the sublingual arteries of a calf; note how they plunge under the mandible.

Blood supply

We also investigated the terminal branches of the sublingual artery. The study of the anatomical specimens of human cadavers showed that the sublingual artery bifurcates at the level of the canines; the two branches enter the superior and inferior foramina on the lingual surface of the mental area (Figure 5). Superior and inferior lingual foramina with the appropriate channels were also clearly seen on the computed tomograms of the mandible (Figure 6).

Animals lack the chin, therefore we assume that their sublingual arteries do not enter the bone from the lingual side. After the dissection of the soft tissues in the mouth floor of the calves and pigs, it was found that the branches of sublingual artery submerge under the mandible and supply the tissues of the mouth floor, the lower lip and the fibrous space between the two parts of the mandible (Figure 7).

Comparing the areas of different nerve blocks revealed the following: after the inferior alveolar nerve block, most patients experienced anaesthesia of the chin tissues that was significantly less than that of the corresponding half of the lower lip. After the additional mylohyoid nerve block, the numbness of the skin around the chin increased (Figure 9).

During the dissection of the sublingual and submandibular areas in animals, we found that mylohyoid nerves submerge under the mandible (Figure 10) and innervate the tissue of the sensitive "pad" and sensory tactile hair on the skin in the area of the frontal part of the mandible (Figure 11 a, b). This area enables the animals to sense the ground and plants, and in humans it presents as an oval area of innervation on the skin of the chin. The zone of mylohyoid nerve innervation on the skin of the chin is most likely a formation derived from animals that has lost its original purpose (involution of innervation with parallel evolution of the chin).

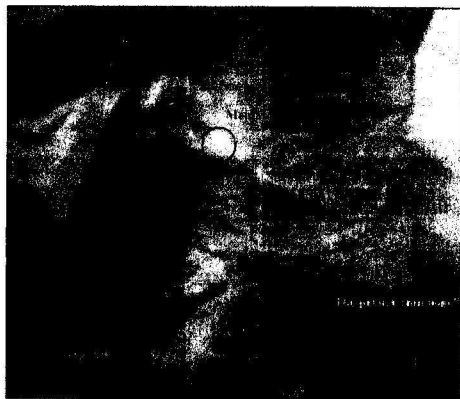

Figure 8. The incisive branch of the mental nerve approaches the teeth above the „proper chin.”

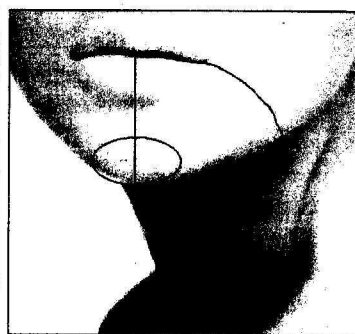


Figure 9. The zone of numbness of the chin skin after the inferior alveolar and mylohyoid nerve blocks.

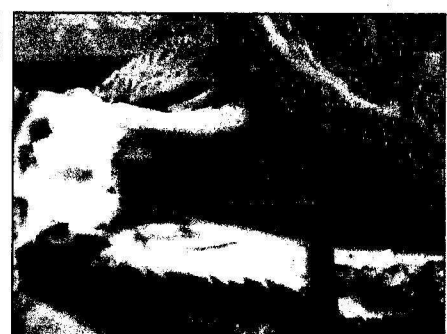

Figure 10. The mylohyoid nerve and sublingual branch of the lingual nerve in the bottom of an animal's mouth.

Innervation

Dissection also revealed the structure of the „incisive canal” of the mandible, which is a continuation of the mandibular canal. Removal of the cortical bone beginning from the mental foramen to the midline of the mandible revealed that the intraosseous portion of the mental nerve descends from the mental foramen; it is then directed upwards and goes around the „proper chin region,” heading for the anterior teeth of the mandible (Figure 8). This course suggests the possibility of different methods of development in the mandibular body and chin.

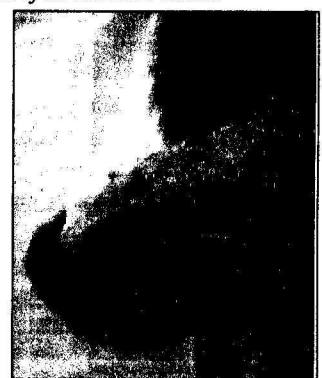

Figure 11 a, b. Sensitive "pad" with sensory tactile hair in a calf.

DISCUSSION

Development of the chin

The chin is a relatively new evolutionary formation. The presence of a chin protuberance – a thickening along the lower edge of the mandible – belongs to humans only. All animals, including Neanderthals, the immediate predecessors of humans, did not have such a structure in the mandible (10). However, the Cro-Magnons possessed all the features of modern humans, including a prominent chin (11). Various causes of the chin appearance in humans, including the reduction and straightening of the alveolar process, the unequal growth of the alveolar and basal portions of the mandible during changes in the dentition, the divergence of the mandibular ramuses resulting in the need to strengthen the frontal component, and the appearance of speech, as well as the others (10) have been discussed. However, in our opinion, the formation of the chin is primarily associated with the appearance of an upright posture, speech, and the necessity for a stronger fixation of the mento-hyoid-pharynx-laryngeal complex.

Also, there are peculiarities of the formation and ossification of the chin. In the embryonic period, this part of the mandible consists of small chin bones, which are specific for humans only. They appear at the end of the embryonic period (7-8 weeks) in the symphysis and then fuse with each other and with the body of the mandible (10). The fusion of these bones begins at 3 months of foetal life and ends at the age of 2 years (12). In an adult human, the crest of the symphysis in the midline passes into the triangular chin elevation, which is characteristic of modern humans (13). The genial tubercles exist on the sides of the vertical symphysis crest (14).

Data on the involvement of Meckel's cartilage in the development of different parts of the mandible are controversial. It is well known that the mandible develops from several ossification points in the membrane adjacent to Meckel's cartilage (15). They are the cartilaginous basis for the formation of the mandibular arch, although, according to some authors, Meckel's cartilages themselves are not directly involved in the formation of the mandibular bone (16), or are involved in the formation of only its posterior parts (15, 17). Other authors are of the opinion that endochondral bone formation occurs in the area of the midline, which means that this part of the mandible is the primary jaw that develops from Meckel's cartilage (18). The germs of Meckel's cartilages can be identified at the end of the 5th week of embryogenesis (19), and the formation of the mandible begins on the cartilages after approximately 8-9 weeks of foetal development (20). During foetal development, the mandible becomes bony, but its development is not yet complete. The two halves begin to grow together at the 3rd month and fuse until the 2nd year of life into the unpaired bone, keeping the mark of fusion in the midline (21). During the examination of the juncture, the mandibular plates were observed to touch at the level of the alveolus, and when closer to the base of the mandible, they diverge 1-4 mm. Between the borders of the mandibular components, there is a triangular fissure (22). In our study of foetal anatomical specimens, it was found that the triangular fissure on the junction of the mandibular halves is covered by the "proper

chin bone." The younger the age of the foetus, the less this bone is connected to the bone of the mandibular body, and at 10-12 weeks of development, it lies freely in the soft tissues of the chin area. Previous researchers likely removed it unintentionally together with the soft tissues and did not identify it on the mandible specimens. That bone could be compared and referred to the so-called sutural bones, which may be permanent or non-permanent (23). Such wedge-shaped sutural bones of the skull are also called intercalary or Wormian bones, and as a rule, they are located symmetrically (14). Thus, the chin has its own special process of ossification – the separate zone located between the two halves of the mandible develops irrespective of Meckel's cartilage, while the mandibular body and the alveolar portion are formed from its membrane.

Blood supply of the chin area

The blood supply of the mandible and surrounding soft tissues has been well studied. However, the data on both the anatomical peculiarities and the sources of the blood supply of the chin are incomplete. It is known that there is a system of extra- and intraosseous blood circulation of mandible, and except the inferior alveolar artery, there are also 7 small extraosseous vessels that supply the mandible, mainly from the lingual side (24). The lingual artery was mentioned as a source of blood supply for the lower margin and the internal plate of the chin, although this artery itself is unlikely to reach the centre of the chin.

Reports of significant bleeding during operations in this area indicate the presence of large blood vessels located on the lingual side of the mandible (25, 26, 27). Krenkel et al. describe 6 cases of excessive bleeding during the placement of implants in the anterior mandible and consider the branches of the sublingual artery to be the source of the bleeding. According to these data, as well as the reference of Tsusaki (28), the sublingual artery has a large terminal branch, which is divided into several branches: the ascending medial and lateral and the descending superior and inferior sublingual arteries. These arteries enter the mandibular bone on the lingual side through the corresponding openings.

As for the nutritional foramina for the named vessels, we did not find the requisite information in anatomy textbooks. Studies in Ukraine and Russia have published data about additional nutritional foramina in the mandibular ramuses (29, 30), but not in the chin.

Some studies describe the foramina on the lingual surface of the mandible with no specific anatomical names, and the different authors named them in different ways.

McDonnel et al. (31) investigated dry specimens of mandibles and found lingual foramina in 99.04 % of cases. Only the single foramina in the midline above or on the genial tubercle were taken into account. On wet specimens, one artery entered the lingual foramen, but it was an anastomosis of the arteries of the right and left side (an unusual phenomenon – the anastomosis in one median vessel) and not a neurovascular bundle. The radiographs revealed the presence of the foramen in 49 % of patients. It appeared as a rounded portion of radiolucency, surrounded on the periphery with a radiopaque area, not associated with the roots of the central incisors. Radiopacity was considered to indicate

the genial tubercles or the cortical wall of the canal. On the radiographs, the lingual foramen could be seen only when the beam was parallel to the canal, and if the orientation of the beam was changed horizontally or vertically, the foramen was not visible⁽³¹⁾. Panoramic radiographs also provided little information because of the overlay of the cervical vertebrae in the area of the foramen⁽³²⁾.

According to Vasconsellos et al.⁽³³⁾, vessels and sometimes small nerves enter the mandibular lingual bone through the foramen. The authors identified 1-3 foramina. Most often, one canal was found, rarely a canal with a bifurcation⁽³³⁾. Nagar et al.⁽³⁴⁾ considered the single foramina in the midline above the genial tubercle. The foramen in the midline was found in 72.45 % of the mandibular specimens, and in 55.5 % of cadavers, it included a thin artery - the branch of the left sublingual artery that also provided a branch to the alveolar part. In 5.98 % of cases, the foramen was located below the genial tubercle; in 1.6 %, on the right or the left side of it; and in 10 %, it was not in the area of the tubercle⁽³⁴⁾. The foramina may include nerve fibres that are necessary for the additional innervation of the anterior teeth⁽³⁵⁾. Wire 0.2 - 1.8 mm in diameter was used to determine the diameter of the foramina. The diameter of the lingual foramina reached 0.4-1.6 mm, and 32 % of the foramina were located between the anterior teeth. In 98 % of cases, they were located symmetrically between the medial and lateral incisors, and in other cases, one foramen was present in the midline, or 3-4 foramina were found; they were also localised between the lateral incisors and canines⁽³⁵⁾. Singh et al.⁽³⁶⁾ grouped all the foramina related to the mental spines into three groups: supraspinous, interspinous and infraspinous. The supraspinous foramen was the largest and the most frequent, present in 88.08 % of cases. In our anatomical studies, we also identified the branches of the sublingual arteries that entered the chin.

Computed tomography can be used for the effective detection of the lingual foramina on the mandible⁽³²⁾. The authors found lingual foramina in 100 % of cases during computed tomography analysis for implant placement in the anterior portion of the mandible. One to four foramina and canals with clear radiopaque walls were observed. The canals' diameter reached 0.52 to 1.74 mm. The depth of the canals' disposition and direction were different. The arteries entering the canal were the branches of the sublingual or submental arteries⁽³²⁾. Dental 3D cone beam computed tomography allows the examiner to determine the different structures of the mandibular symphysis: the incisive canal, the lingual canal, the foramina for the submental and mylohyoid arteries, and a bifurcated mental foramen⁽³⁷⁾. The computed tomograms of our study also revealed clearly visible channels.

Innervations of the chin area and the surrounding soft tissues

It is important to consider the location of the nerve structures in the region for successful surgery in the frontal part of the mandible and the surrounding soft tissues.

The mental nerve has extra osseous and intraosseous portions; the latter starts from the mental foramen and continues to the mandible syphilis. The intraosseous portion of the nerve lies inside the incisive channel, which brings ves-

sels and nerves to the roots of the lower incisors and passes around the „proper chin bone,” but does not penetrate it.

We found a peculiarity of the soft tissues innervation of the chin with the mylohyoid nerve and the sublingual branch of the lingual nerve. The mylohyoid nerve is considered by most authors to be a motor nerve, but like any motor nerve it can also carry sensory innervation. The mylohyoid nerve carries sensation from the skin of the chin, anterior mandibular teeth and medial portions of submandibular triangle^(38, 39, 40). Some mandibular foramina are closely associated with the mylohyoid groove and may be related to the nerve entry into the mandible for additional sensory innervation of the mandibular teeth⁽³⁹⁾. Przystańska and Bruska⁽⁴⁰⁾ identified the branches of the mylohyoid nerve entering the lingual foramen together with the sublingual artery and accompanying veins.

CONCLUSIONS

„The proper chin” should refer to a small triangular-shaped area of the bone in the frontal part of the mandible. In the embryo, this area consists of small chin bones; in the foetus, they form a “proper chin”, which exists separately from the mandible until 7-9 month of foetal life. This feature is specific for humans. The chin area of the mandible exhibits its own special method of ossification, development and blood supply. The innervation and blood supply of the chin protuberance are provided primarily by the sublingual arteries and nerves that have special foramina on the lingual surface of the mandible. In animals, the sublingual artery and nerve and the mylohyoid nerve supply blood and innervate the sensitive „pad” in the submental area, which senses the ground surface and presents as an oval area of innervation of the chin skin in humans.

These data should be considered during a variety of manipulations in the chin area, such as local anaesthesia, implant placement, and genioplasty. Additionally, the mentioned peculiarities may be important in the healing of bones after the surgery, fractures of the mental area and the formation of specific planes of fracture.

Ethics

This study has been approved by the appropriate ethical committees.

Funding source

No sponsors were involved in the study.

Conflict of interest

None

Acknowledgements: We thank the Department of Anatomy of Bukovina State Medical University (Head of the Department - Prof. Makar B.G.) and the Department of Anatomy of Vinnitsa National Medical University named after N. I. Pirogov (head of the Department - Prof. Guminski I.I.), for help with the anatomical part of this study.

Sažetak

Ova studija je istraživala specifičnosti anatomije, vaskularizacije i inervacije kosti u mentalnoj regiji i okolnim mekim tkivima, kao i razvoj brade tokom filogenetskog i ontogenetskog razvoja. Pored toga je sprovedena i uporedna anatomsko studija inervacije i snabdevanja krvlju kosti i okolnih mekih tkiva kod ljudi i životinja.

Zaključci ovog istraživanja su sledeći: brada sama po sebi se može smatrati malim delom kosti, trouglastog oblika u prednjem delu donje vilice. Njeno postojanje kod ljudi se može pripisati uspravnom položaju. Inervaciju i snabdevanje krvlju obezbeđuju pre svega podjezična arterija i živac, za koje postoji poseban otvor na površini donje vilice okrenute ka jeziku. Poznavanje ovih specifičnosti je neophodno za davanje lokalne anestezije, postavljanja implantata, genioplastici i lečenju preloma u mentalnoj regiji donje vilice.

REFERENCES

- Mommaerts MY, Van Hemelen G, Sanders K, Vander Sloten J, Van Brussel K, Abeloos JV, De Clercq CA, Neyt LF. High labial incisions for genioplasty. *Br J Oral Maxillofac Surg* 1997; 35 (6): 398-400.
- Mommaerts MY, Abeloos JV, De Clercq CA, Neyt LF: Intraoral transmental suction lipectomy. *Int J Oral Maxillofac Surg* 2002; 31 (4): 364-6.
- Гулюк АГ, Лепский ВВ, Гулюк СА: Использование костных аутоблоков ментального отдела нижней челюсти при аугментации локальных дефектов фронтального отдела верхней челюсти. *Дентаклуб 7-8: 46-50, 2012.*
- Боровицкая НН, Тополюницкий ОЗ, Васильев А, Першина МА, Петровская ВВ, Федотов РН, Дьяконова СА. Повторная и отсроченная костная пластика расщелины альвеолярного отростка. Материалы IV Всероссийской научно-практической конференции Врожденная и наследственная патология головы, лица и шеи у детей: актуальные вопросы комплексного лечения, М.: МГМСУ 2012; 40-50.
- Mommaerts MY, Polsbroek R, Santler G, Correia PE, Abeloos JV, Ali N. Anterior transmandibular osteodistraction: clinical and model observations. *J Craniomaxillofac Surg* 2005; 33 (5): 318-25.
- Рауер А. Переломы челюстей и повреждения мягких тканей лица. Москва: Медгиз 1947; 300 с.
- Habal MB, Ariyan S. Facial fractures. Toronto, Philadelphia: B.C. Decker Inc. 1989; 183-94.
- Мальшев ВА, Кабаков БД. Переломы челюстей. *Спедлит* 2005; 224 с.
- Clark S, Reader A, Beck M, Meyers WJ: Anesthetic efficacy of the mylohyoid nerve block and combination inferior alveolar nerve block/mylohyoid nerve block. *Oral Surg Oral Med Oral Pathol Oral Radiol Endod* 1999; 87(5): 557-63.
- Лойт АА, Каюков АВ: Хирургическая анатомия головы и шеи. Москва: МЕДпрессинформ 2006; 128 с.
- Томас Г: Древний человек; пер. с фр. А. Мединской. Москва: ООО Издательство Астрель: Издательство АСТ 2002; 160 с.
- Каламкаргов ХА, Рабухина НА, Безруков ВМ: Деформации лицевого черепа. Москва: Медицина 1981; 125 с.
- Рабинович СА, Васильев Л: Анатомио-топографические и инструментальные аспекты местного обезболивания в стоматологии. Москва 2011; 144 с.
- Rauber's Lehrbuch der Anamie des Menschen von prof. Dr. Fr. Kopsch. Zehnte vermehrte und verbesserte Auflage. Abteilung 2: Knochen, Baender. Leipzig: Verlag von Georg Thieme 1947; 116-8.
- Колесов АА, Каспарова НН, Жилина ВВ: Стоматология детского возраста. Москва: Медицина 1991; 464 с.
- Фалин ЛИ: Эмбриология человека. Атлас. Москва: Медицина, 543 с., 1976.
- Хомутов АЕ: Антропология, изд. 3-е Ростов н/Д: Феникс 2004; 384 с.
- Головкин НВ: Ортодонтия. Развитие прикуса, диагностика зубо-щелпных аномалий, ортодонтический диагноз. Полтава: УМСА 2003; 170 с.
- Rodríguez-Vázquez JF, Sakiyama K, Verdugo-López S, Amano O, Murakami G, Abe S. Origin of the torus mandibularis: An embryological hypothesis. *Clin Anat*. 2013 Jun 27. doi: 10.1002/ca.22275.
- Барсуков АН, Шаповалова Е, Юнси ГА, Апухтин ЮП: Цито- и гистологическая характеристика структурных компонентов, формирующих жаберный аппарат человека в конце 4-ой недели эмбриогенеза. *Таврический медико-биологический вестник* 2011; 53 (1): 11-4.
- Гузік НМ: Розвиток і становлення топографії структур ротової ділянки в ранньому періоді онтогенезу людини: дис. на здобуття наук. ступ. канд. мед. наук.: 14.01.03 Нормальна анатомія. Чернівці 2006; 156 с.
- Смирнов ВГ, Персин ЛС: Клиническая анатомия скелета лица. Москва: Медицина 2007; 223 с.
- Radlanski RJ, Heikinheimo K, Gruda A. Cephalometric assessment of human fetal head specimens. *J Orofac Orthop*. 2013; 74(4): 332-48.
- Сперанский ВС, Зайченко АИ: Форма и конструкция черепа. Москва: Медицина 1980; 280 с.
- Уваров ВМ: Одонтогенные воспалительные процессы. Клиника, диагностика и лечение. Из-во Медицина, Ленингр. отд. 1971; 214 с.
- Krenkel C, Holzner K, Poisel S: Mundbodenhaematome nach oralchirurgischen Eingriffen und ihre anatomischen Besonderheiten. *Dtsch Z Mund Kiefer Gesichts Chir* 1985; 9: 448-51.
- Krenkel C, Holzner K: Die linguale Knochenperforation als Kausalfaktor einer bedrohlichen Mundbodenblutung bei einem Einzelzahnimplantat der Eckzahnregion. *Die Quintessenz* 1986; 6: 1003-8.
- Kalpidis CDR, Setayesh RM: Hemorrhaging associated with endosseous implant placement in the anterior mandible: A review of the literature. *J Periodontol* 2004; 75 (5): 631-45.
- Tsasaki T, Eida T, Shirai M. A contribution to the development of the mandibular canal in the rabbit. *Yokohama Med Bull*. 1951; 2(6): 352-9.
- Маланчук ВА, Черкасов ВГ, Бобрік ІІІ, Воловар ОС, Чумак МН, Ігнатішів МР: Особливості топографії питательних отворів ветви нижньої щелепної. *Вісник стоматології* 2006; 4: 52-5.
- Кузин А, Дадькин С: Внутрикостная анестезия ретромолярной области нижней челюсти. *Cathedra* 2013; 43: 22-5.
- McDonnell D, Reza Nouri M, Todd ME: The mandibular lingual foramen: a consistent arterial foramen in the middle of the mandible. *J Anat* 1994; 184: 363-9.
- Babiuc I, Tărlungeanu I, Păuna M: Cone beam computed tomography observations of the lingual foramina and their bony canals in the median region of the mandible. *Rom J Morphol Embryol* 2011; 52 (3): 827-9.
- Vasconcellos HA, Siqueira Campos AE, Almeida GH, Tan Maia ML, Vasconcellos PHB. The anatomy of the lingual foramen canal and its related to the mandibular symphysis. *Rev Chil anat* 2000; 18 (1): 47-51.
- Nagar M, Bhardwaj R, Prakash R: Accessory lingual foramen in adult Indian mandibles. *Journal of the Anatomical Society of India* 2001; 50 (1): 13-4.
- Przystańska A, Bruska M: Foramina on the internal aspect of the alveolar part of the mandible. *Folia Morphol* 2005; 64 (2): 89-91.
- Singh V, Anand MK, Dinesh K: Variations in the pattern of mental spines and spinous mental foramina in dry adult human mandibles. *Surg Radiol Anat* 2000; 22: 169-73.
- Miller RJ, Edwards WC, Boudet C, Cohen JH: Maxillofacial anatomy: the mandibular symphysis. *J Oral Implantol* 2011; 37 (6): 745-53.
- Desantis JL, Liebow C: Four common mandibular nerve anomalies that lead to local anesthesia failures. *JADA* 1996; 127 (7): 1081-6.
- Stein P, Brueckner J, Milliner M: Sensory innervation of mandibular teeth by the nerve to the mylohyoid: Implications in local anesthesia. *Clin Anat* 2007; 20: 591-5.
- Przystańska A, Bruska M: Accessory mandibular foramina: Histological and immunohistochemical studies of their contents. *Arch Oral Biol* 2010; 55: 77-80.

■ The paper was received on 10.07.2013. Accepted on 12.07.2013.