

See discussions, stats, and author profiles for this publication at: <https://www.researchgate.net/publication/357535095>

# Effectiveness of Perioperative Local Use of Anesthetics and Antiseptics in Patients with Purulent–necrotic Lesions of Lower Extremities in Diabetes Mellitus

Article in *Journal of Pharmaceutical Research International* · December 2021

DOI: 10.9734/JPRI/2021/v33i58B34212

CITATIONS

0

READS

64

5 authors, including:



**Yuliana Babina**

34 PUBLICATIONS 76 CITATIONS

[SEE PROFILE](#)



**Dmytro Dmytriiev**

National Pirogov Memorial Medical University, Vinnytsya

186 PUBLICATIONS 903 CITATIONS

[SEE PROFILE](#)



**Oleksandr Nazarchuk**

National Pirogov Memorial Medical University, Vinnytsya, Ukraine

145 PUBLICATIONS 285 CITATIONS

[SEE PROFILE](#)



# Effectiveness of Perioperative Local Use of Anesthetics and Antiseptics in Patients with Purulent-necrotic Lesions of Lower Extremities in Diabetes Mellitus

**Yuliana Babina <sup>a\*</sup>, Dmytro Dmyrtriiev <sup>a</sup>, Oleksandr Nazarchuk <sup>b</sup>,  
Pavlo Hormash <sup>c</sup> and Serhii Vernyhorodskyi <sup>d</sup>**

<sup>a</sup> Department of Anesthesiology, Intensive care and Emergency Medicine, National Pirogov Memorial Medical University, Vinnytsya, Ukraine.

<sup>b</sup> Department of Microbiology, National Pirogov Memorial Medical University, Vinnytsya, Ukraine.

<sup>c</sup> Vinnytsia Regional Pathological and Anatomical Bureau, Vinnytsya, Ukraine.

<sup>d</sup> Department of Pathological Anatomy, National Pirogov Memorial Medical University, Vinnytsya, Ukraine.

## **Authors' contributions**

*This work was carried out in collaboration among all authors. All authors read and approved the final manuscript.*

## **Article Information**

DOI: 10.9734/JPRI/2021/v33i58B34212

## **Open Peer Review History:**

This journal follows the Advanced Open Peer Review policy. Identity of the Reviewers, Editor(s) and additional Reviewers, peer review comments, different versions of the manuscript, comments of the editors, etc are available here: <https://www.sdiarticle5.com/review-history/79077>

**Short Research Article**

**Received 10 October 2021**  
**Accepted 14 December 2021**  
**Published 15 December 2021**

## **ABSTRACT**

**Background:** Every second patient with the diabetes mellitus (DM) needs surgery due to purulent-necrotic changes in the feet.

The aim of the study was comparative morphological examination of the course of the wound process in purulent-necrotic lesions of the lower extremities of patients with DM with different approaches to local treatment in the perioperative period.

**Materials and Methods:** We investigated changes in the histological structure and the nature of the reactions of skin tissues, muscles and fascia during the healing of an ulcer in patients with the diabetes mellitus after various types of local treatment. Then the specimens were photographed and analyzed using the OLIMPUS BX 41 light microscope.

**Results:** In the first comparison group, which used standard anesthesia techniques and locally antiseptic povidon-iodine - granulation tissue was characterized by the complete absence of fibrous

\*Corresponding author: E-mail: [ulianababina1989@gmail.com](mailto:ulianababina1989@gmail.com), [yulianochka-1989@ukr.net](mailto:yulianochka-1989@ukr.net);

structures and the presence of a small number of small-sized neoplastic vessels with swollen endothelium. And in patients of the II observation group who received locally decamethoxin and infiltration anesthesia with a 2% solution of lidocaine after surgery during the study of histological preparations of the affected tissues, a significant decrease in signs of pathological vascular reaction was established compared with the comparison group.

**Conclusions:** In group 1 (control) healing of wounds on the third-seventh day is characterized by somewhat slow regeneration. Wound healing was most favorable in patients of the second group, where infiltration anesthesia was used by local anesthetic and antiseptic decamethoxin.

**Keywords:** *Anesthetics; antiseptics; diabetes mellitus; inflammation; wounds.*

## 1. INTRODUCTION

Diabetes mellitus (DM) is one of the common long-term diseases worldwide. According to the International Federation of Diabetes (IDF) today 387 million people in the world suffer from DM, which is 8.3% of patients [1-3]. In addition, according to IDF estimates, among the diabetic population of the world, the disease is not diagnosed in about 46%, who are more likely to live in low and middle income countries [1]. Limited access to help with diabetes mellitus leads to an increased risk of developing vascular and neuropathic complications of diabetes, including foot disease caused by neuropathy or ischemia.

Prevention, early detection and a multidisciplinary approach to rapid comprehensive treatment can save lives and reduce lower limb amputation worldwide.

Diabetic foot syndrome (DFS) is defined as infection, ulcer, or destruction of deep foot tissues (including bones) in a diabetic patient, which occurs in almost 6% of cases. Approximately 0.5% to 1.5% of patients with diabetic foot syndrome need amputation. Most amputations associated with progression and infectious complications of ulcers [4,5].

The study of the peculiarities of the wound process is one of the main directions to the solution of the problem of treatment of purulent-necrotic complications of diabetic foot syndrome. Every second patient with diabetes mellitus needs surgery due to purulent-necrotic changes in the feet. Diabetes mellitus negatively affects the course of the wound process, slowing the healing of wounds that acquire a long, relapsing character [6]. Wound healing is a complex process that takes place at different levels (molecular, subcellular, cellular, tissue and organ), the ultimate goal of which is to eliminate

damage with maximum restoration of anatomical structure, provided minimal functional losses [6].

### 1.1 Objective

Comparative research of changes in histological structure and the nature of reactions of skin tissues, muscles and fascias in the healing of ulcerative defect in patients with diabetes depending on the local antimicrobial therapy with antiseptics povidone iodine in patients with perioperative narcotic analgesia and antiseptic decamethoxin with local lidocaine analgesia.

## 2. MATERIALS AND METHODS

Under our examination and treatment from 2020 to 2021 there were 86 patients with complicated DFS, who were in Vinnytsia Regional Clinical Highly Specialized Endocrinology Center of the Vinnytsia Regional Council of the Ministry of Healthcare of Ukraine"). From these patients assessed for eligibility, 20 were finally randomised. Criteria for inclusion in the study: type 2 diabetes, the presence of complicated DFS with purulent-necrotic processes of the tissues of the foot. Exclusion criteria: type 1 diabetes, DFS with intact skin (stage 0 according to the Wagner classification), patients on hemodialysis. Among the operatives 13 men (65.0%) predominated. The age of patients was in the range from 58 to 86 years. Elderly patients (60-74 years) there were 14 (70.0%) elderly patients (75 years and older) - 6 (30.0%) patients). A random sequence generator was used to determine the distribution of patients into groups. For participant allocation, permuted block randomisation was carried out by an institutional statistician using a computer-generated list of random numbers and sealed envelopes. Surgeons and nurses involved in patient care were aware that the study was being conducted but were blinded to the details of the study protocols. The surgical procedure was performed

by one surgeon and surgical team using the same method.

We investigated changes in histological structure and the nature of reactions of skin tissues, muscles and fascias in the healing of ulcerative defect in patients with diabetes. Morphological and histochemical studies were carried out on the 1st day after surgical intervention (material intake - intraoperative), 3 days and 7 days after surgery. The study was conducted in 2020-2021, according to the Helsinki Declaration [7]. Each subject of the study was given all the details of medical procedures, given the opportunity to discuss any issues with medical workers, and then signed a detailed form of informed consent to conduct the study.

All patients were divided into 2 groups (10 patients in each group): 1) The first group (comparison) included patients who had general standard anesthesia (non-narcotic analgesics (paracetamol, NSAID) and, if necessary, narcotic analgesics (morphine) and local antimicrobial therapy with povidone iodine. 2) II group of observation – patients had local analgesia (anesthetic 2% lidocaine 2mg/kg) + local antimicrobial therapy with antiseptic (decamethoxin).

In the above terms, patients were excision of ulcers - performed sampling of skin fragments with subordinate tissues from the location of the ulcerative defect, departing from their edges by 0.5 cm, as well as fragments of affected muscle tissue and fascias measuring 1 - 1.5 cm.

The studied material was fixed with 10% aqueous solution of neutral formalin for at least 48 hours, followed by washing with running water, dehydration in the system of multi-atom alcohols and pouring into paraffin according to the standard scheme. Prepared slices with a thickness of 7-8  $\mu\text{m}$  were colored with hematoxylin and eosine.

Microscopy of histological preparations was carried out using the OLIMPUS BX 41 light microscope (Ministry of Health of Ukraine Certificate of State Registration № 8120/2008, code 9011800000) with the use of increases of 40, 100, 200 and 400 times. Image and morphometry visualization was carried out using the morphometric program Quickphoto micro 2.3 (license agreement № 925113924). During microscopy, an assessment of the morphological

state and composition of skin tissues in the edges and days of the ulcerative defect, the presence of pathological and reparative changes, their character, as well as the nature of pathological changes in muscle tissue and fascia in diabetes mellitus was carried out.

The obtained data was processed statistically using a package of applied statistical programs SPSS for Windows 10 and STATISTICA 5.5. The difference was considered reliable when the p value was less than 0.05.

### 3. RESULTS

During the study we researched the following morphometric parameters of affected tissues in ulcerative defects of the skin, muscle tissue and fascia of patients of different groups: relative area of stromal edema, relative area of granulation tissue vessels, diameter of granulation tissue vessels, number of vessels in 1 mm<sup>2</sup>, density of inflammatory cell infiltrate of granulation tissue (segmentonuclear leukocytes, plasma cells, macrophagic elements) in 1 mm<sup>2</sup>, number of fibroblasts in 1 mm<sup>2</sup> (Table 1).

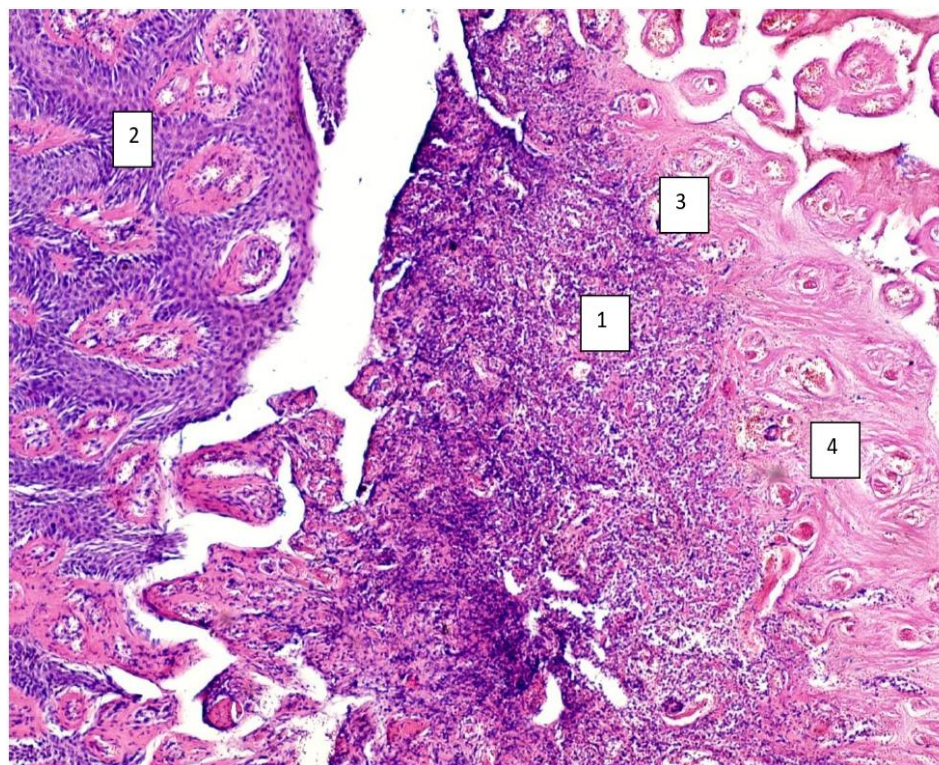
At the 1st day of observation, the edges and bottom of the ulcerative defect were characterized by the complete absence of newly formed fibrous structures (collagen fibers). Granulation tissue in this term was not defined. In tissues that formed the bottom and edges of the ulcerative defect, common areas of necrosis and diffuse polymorphic cell infiltration were determined, which was represented mainly by segmentonuclear leukocytes. The newly formed vessels were absent during this period, which indicated the absence of a vascular reaction in the affected tissue (Table 1). Young fibroblasts were also not determined. The vessels of the tissues of the edges and the bottom of the ulcerative defect were dilated, full-blooded, and some blood clots, the walls of blood vessels and endothelium were swollen, sometimes necrotized, there was a significant perivascular edema, which indicated significant disorders of microhemocirculation in the affected tissues (Table 1). Thus, in the samples studied, the remains of necrotic tissues were determined, the absence of granulations, a large number of inflammatory cell elements, a pronounced pathological vascular reaction, morphometric indicators practically didn't differ in groups ( $p = 0.05$ ) (Fig. 1).

**Table 1. Comparison of morphometric parameters in study groups**

Indicators	I study group		I study group	II study group	II study group
	1 - day	3 - day	7 - day	3 - day	7- day
The relative area of the vascular bed of the microcirculatory tract,%	-	12, 68 ± 2,8*	10,06± 2,5**	22,42 ± 2,5	8,12± 1,7
The average diameter of the vessels of the granulation tissue, μm	-	16,14 ± 1,6*	13,26 ± 5,8**	22,08 ±	10,14± 0,56
The relative area of stromal edema,%	-	25,12 ± 3,4*	22,42± 5,8**	16,48 ± 3,56	13,23± 2,3
Density of inflammatory cell infiltrate	566,18±28	512,1 ± 58,7*	284±12,5**	160,23 ± 34,7	179± 21,7
The number of segmental leukocytes in 1 mm <sup>2</sup>	328,16±56	304,12±25*	125,12± 12,5**	98,24 ± 12,4	82,21± 3,5
The number of plasma cells in 1 mm <sup>2</sup>	132, 39±23	122,6±40,3*	107,06± 20,1**	86,34±7,9	63,11±2,67
The number of lymphohistiocytic elements in 1 mm <sup>2</sup>	106,13±26	86,12±12,6*	52,12± 3,89**	56,26±3,6	34,2±1,7
The number of fibroblasts in 1 mm <sup>2</sup>	-	-	24,2±1,6**	22±1,67	49,05±3,5

Notes: \* in the first group  $p < 0.05$  compared with the results of group 2 on the 3rd day

\*\*in the first group  $p < 0.05$  compared with the results of group 2 on the 7th day



**Fig. 1. Edges of ulcerative defect on the first day: diffuse inflammatory polymorphonuclear infiltration (1), pseudoepitheliomatous hyperplasia of the epidermis (2), common necrosis of the dermis (3) with stagnant full blood vessels (4). Hematoxylin-eosine, × 100 [8]**

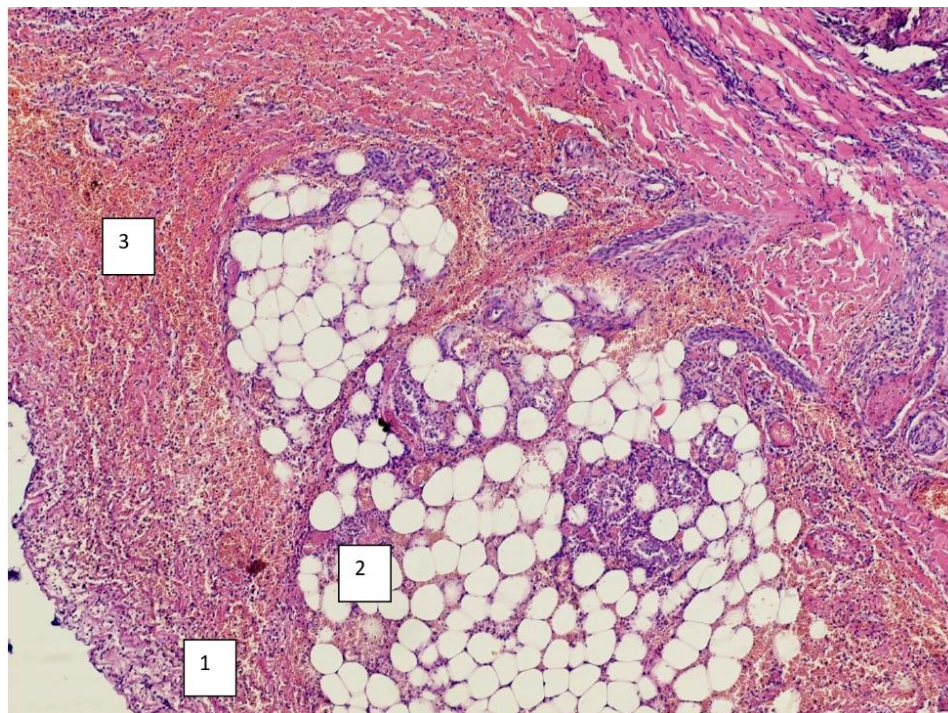


On the 3rd day of observation in patients, the comparison group in granulation tissue revealed the complete absence of fibrous structures (collagen fibers) and the presence of a small number of small-caliber neoplastic vessels with swollen endothelium (Table 1). In the amorphous intermediate, different forms of inflammatory cell elements of granulation tissue (segmentonuclear leukocytes, plasma cells, cells of the macrophage series) were determined (Table 1). In the vessels there are signs of significant disorders of microhemocirculation in the affected tissues: the vessels of young granulation tissue were dilated, full-blooded, the endothelium was swollen, there was a significant perivascular edema. In some vessels there was a sludge phenomenon of red blood cells (Fig. 2).

Patients of the II group of observation (main) on the 3 day after surgical intervention in the study of histological preparations of the affected tissues showed significantly smaller signs of pathological vascular reaction compared with the comparison group ( $p < 0.05$ ), as evidenced by a decrease in perivascular and stromal edema, the relative area of which was  $16,48 \pm 3,56\%$ . At the

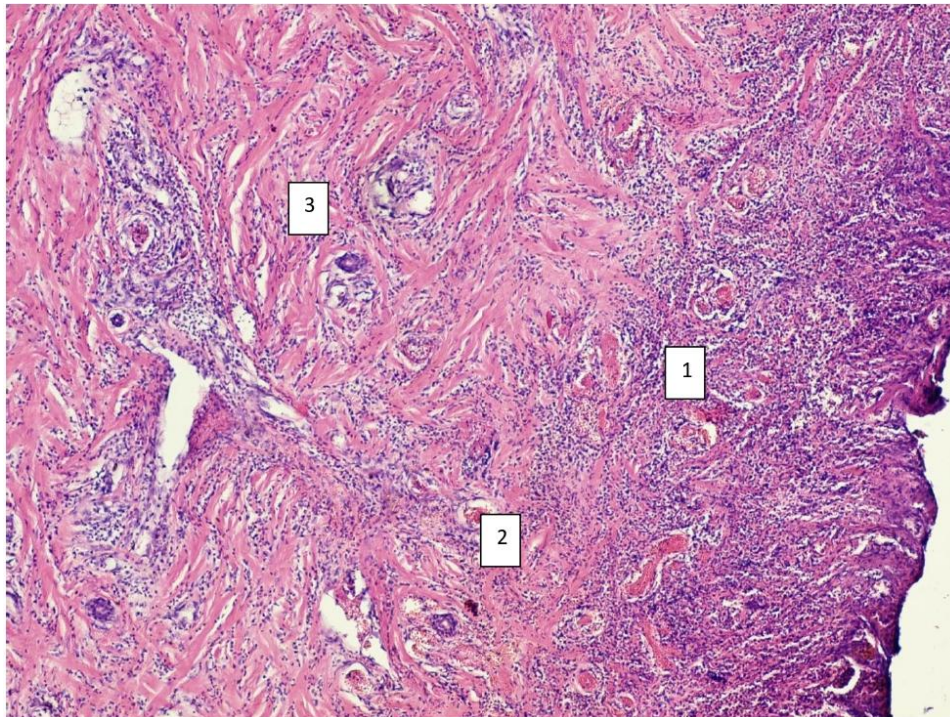
same time, there were still signs of full blood flow, erythrocytosis in some vessels, microthrombosis were absent. Histologically, the vascular bed was represented by vessels of small caliber (capillaries, venules, arterioles), some of which were already reduced. The main substance of granulation tissue was represented by amorphous eosinophil mass with the presence of parallel oriented fiber structures - collagen fibers, which are produced by fibrocytes, with a small number of inflammatory cell elements (Table 1). Such changes contributed to the formation of full scar tissue and further reduction of inflammatory changes.

The patients of the comparison group (I group) on the seventh day showed signs of incomplete inflammatory changes with a completely unformed full-fledged scar coarse-fiber tissue with a large number of fibrocytes and collagen fibers, reduced by slit-like non-functional vessels. Stromal edema and other signs of a pathological vascular reaction were poorly expressed (Table 1). Part of the vessels was in a state of reduction (Fig. 3).

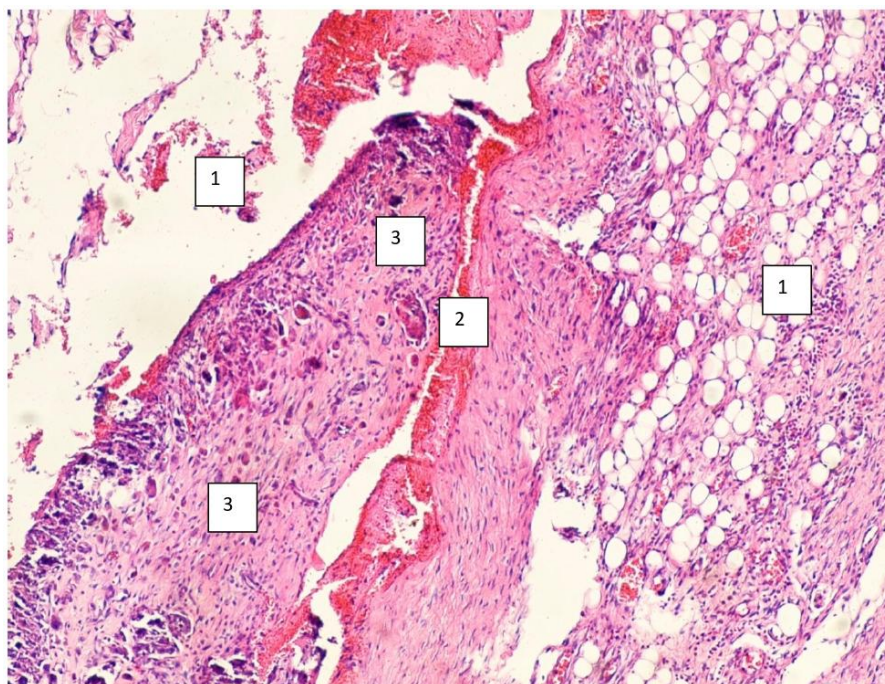


**Fig. 2. Skin area with ulcerative defect 3 days after treatment, I group of patients. Significant infiltration by segmental neutrophilic white blood cells of the dermis at the edges of the ulcerative defect with lymphocytes present (1), stagnant full blood vessels with erythrocytosis (2), moderate edema of the fibrous tissue of the dermis (3). Hematoxylin-eosine.  $\times 100$  [8]**





**Fig. 3.** The bottom, the edges of the ulcerative defect on the 7th day (first group, comparison): proliferation of the epithelium (1) at the edges of the ulcerative defect, granulation tissue rich in vessels with inflammation (2), in the deep layers the granulation tissue is replaced by a young scar (3). Hematoxylin-eosine.  $\times 100$  [8]



**Fig. 4.** The bottom, the edges of the ulcerative defect after 7 days after treatment (second group): in the deep layers of the bottom and edges of the ulcerative defect, the granulation tissue is replaced with a young scar (1), a slight lymphohistiocytic infiltration (2), preserved skin (3). Hematoxylin-eosine.  $\times 100$

Patients of the II observation group on the 7th day, unlike previous studies, identified signs of an almost complete reduction of inflammatory changes with the formation of full-fledged scar coarse-fiber tissue with a large number of fibrocytes and collagen fibers, reduced slit-like non-functional vessels, with less pronounced inflammatory cell infiltration (Table 1). Stromal edema and other pathological vascular reactions in histological samples were not expressed (Fig. 4).

#### 4. DISCUSSION

In this study, the morphological indicators of skin fragments were compared during ulceration and at the stage of healing of ulcers after various methods of local treatment. Thus, before surgical intervention, the remains of necrotic tissues, absence of granulations, a large number of inflammatory cell elements, a pronounced pathological vascular reaction, morphometric parameters were practically indistinguishable in groups ( $p = 0.05$ ) (Fig. 1) were determined in all the samples studied.

In the first comparison group, which used standard anesthesia techniques and locally only antiseptic povidon-iodine - granulation tissue was characterized by the complete absence of fibrous structures (collagen fibers) and the presence of a small number of small-sized neoplastic vessels with swollen endothelium. The vessels of the young granulation tissue were dilated, full-blooded, the endothelium was swollen, there was a significant perivascular edema. Some vessels have observed the sludge phenomenon of red blood cells. These changes in the vessels indicated significant disorders of microhemocirculation in the affected tissues.

And in patients of the II observation group who received locally decamethoxin and infiltration anesthesia with a 2% solution of lidocaine after surgery during the study of histological preparations of the affected tissues, a significant decrease in signs of pathological vascular reaction was established compared with the comparison group, as evidenced by a decrease in perivascular and stromal edema.

One of the main components of effective treatment of trophic ulcers is adequate wound disinfection. In this experiment, we studied povidon-iodine antiseptic. According to domestic and foreign studies in vitro - povidon-iodine has a wide range of actions against gram-positive

(including methicillin-resistant *Staphylococcus aureus* [MRSA]) and gram-negative bacteria, fungi, viruses, simplest and bacterial spores [9,10]. At the same time, another serious problem for effective healing of trophic ulcers today is the formation of bacterial biofilms, which ensure the resistance of microorganisms to antibacterial therapy, which slows down the process of wound healing, especially with chronic ulcers [11-13]. That is why, the great advantage of povidon-iodine preparations is their high efficiency even in the presence of biofilms, which has been proven in a number of studies [6,9,11,12].

According to our morphological data, the best result of local treatment of trophic ulcers was after the use of infiltration anesthesia 2% lidocaine. Thus, according to international and domestic data, today a good practice is the infiltration of local anesthetics along the cut to prevent postoperative pain. This reduces the use of opioids, reducing their side effects. However, local anesthetics have in addition to the main analgesic effect also antimicrobial and anti-inflammatory action [14]. Antimicrobial action of local anesthetics is proven in vitro and described in experimental studies. It was reported that lidocaine 1-3% showed antimicrobial action on *S. aureus* [15-17].

A comprehensive search of literature using MEDLINE 1950 - for studies in vitro and in vivo concerning antimicrobial activity of various local anesthetics in a wide range of bacterial and fungal pathogens [18]. According to various studies, local anesthetics, as a class, have antimicrobial properties against a wide range of human pathogens. Several local anesthetics at concentrations commonly used in clinical conditions (e.g., bupivacaine 0.125-0.75%; lidocaine 1-3%), inhibit the growth of numerous bacteria and fungi [19].

Microbiological efficacy in the use of surface-active antiseptic decamethoxin (which was used for local therapy in patients 2 group of observation) is based on the proof of its high efficiency in a wide range of gram-positive, gram-negative microorganisms [20]. Thus, as a result of the studies, a high bactericidal effect of decamethoxin has been proven against the clinical strains of *S. aureus*, *Enterococcus* spp., and it has been shown that the decamethoxin doesn't have cytotoxic action [21,7]. The advantages of antimicrobial efficiency against these gram-positive bacteria in an antiseptic



based on decamethoxin compared to 10% povidone iodine ( $P < 0.001$ ) have been established.

When evaluating morphological data on the use of decamethoxin and povidone-iodine, it was noted that wound healing processes using decamethoxin were more intense, side effects and allergic reactions were not observed, which can be explained by the lack of toxic action of decamethoxin in the clinical concentration [21].

According to the literature, the absorption of decamethoxin by intact skin and wound surface is very low and the likelihood of overdose is extremely unlikely [21]. With the joint use of decamethoxin and antibacterial drugs during treatment, the sensitivity of antibiotic-resistant microorganisms to antibiotics increases. It should be noted that decamethoxin resistant forms, even with its prolonged use, are formed slowly and do not exceed the effective concentrations of the drug [21].

## 5. CONCLUSION

The healing of postoperative wounds in patients with diabetic foot ulcers using different methods of postoperative local treatment occurs through a natural wound process with the presence of mandatory stages: damage, inflammation and regeneration. The use of various methods of perioperative anesthesia and local antimicrobial treatment affects the second stage of healing - inflammation. When used in the postoperative period of standard anesthesia and local antimicrobial therapy, povidon iodine healing of wounds on the third-seventh day is characterized by somewhat slow regeneration. Wound healing was most favorable in patients of the second group, where infiltration anesthesia was used by local anesthetic and antiseptic decamethoxin. Local anesthetics provide effective anesthesia in the postoperative period, in particular when used for the purpose of wound analgesia in the acute period and to reduce stress when changing the ligaments. That the surgical benefits of local anesthesia can go beyond its analgesic properties and can play an antimicrobial role in the prevention and treatment of surgical wound infection. The obtained data give reason to conclude that the use of decamethoxin solution effectively prevents the development of wound infection and inflammation in the local treatment of trophic ulcers. Along with these antimicrobial properties, no undesirable side effects of the use of decamethoxin in the form of a local or general

allergic reaction or cross-reaction with local anesthetics have been reported in any observation. This opens up further prospects for in-depth clinical monitoring of the effectiveness of the combined use of local anesthetics and antiseptics for local treatment of infected wounds and lesions.

Recommendations on the basis of this study are further study of local anesthetics as antimicrobial drugs in monotherapy and combination with antiseptics in laboratory conditions and in the clinic, in order to develop alternative methods of prevention and treatment of infectious perioperative complications in surgery.

## CONSENT

As per international standard or university standard, respondents' written consent has been collected and preserved by the author(s).

## ETHICAL APPROVAL

As per international standard or university standard written ethical approval has been collected and preserved by the author(s).

## COMPETING INTERESTS

Authors have declared that no competing interests exist.

## REFERENCES

1. Armstrong DG, Mills JL. Juggling risk to reduce amputations: the three-ring circus of infection, ischemia and tissue loss-dominant conditions. *Wound Medicine*. 2013;1:13-14
2. Frykberg RG, Zgonis T, Armstrong DG, Driver VR, Giurini JM, Kravitz SR, Vanore JV. Diabetic foot disorders: A clinical practice guideline (2006 revision). *The Journal of Foot and Ankle Surgery*. 2006; 45(5):1-66.
3. Bus SA, Valk GD, Van Deursen RW, Armstrong DG, Caravaggi C, Hlaváček P, Cavanagh PR. The effectiveness of footwear and offloading interventions to prevent and heal foot ulcers and reduce plantar pressure in diabetes: A systematic review. *Diabetes/metabolism Research and Reviews*. 2008;24(S1):162-180.
4. Rodríguez-Gutiérrez R, Quintanilla-Flores DL, Soto-Garcia AJ, Gonzalez-Gonzalez

- JG, Sieradzki J, Płaczekiewicz-Jankowska E. Diabetic foot syndrome. McMaster Textbook of Internal Medicine. Kraków: Medycyna Praktyczna; 2021.  
Available: <https://empendium.com/mcmttextbook/chapter/B31.II.13.4.4>  
Accessed July 06
5. Briskin BS, Dibirov MD, Khamitov FF, Proshin AV, Yakobishvili YAI. Khirurgiya. 2007;1:49–55 [in Russian]
6. Wingfield C. Diagnosing and managing lower limb cellulitis. Nurs Times. 2012; 108(27):18-21.
7. Nazarchuk OA, Chereshniuk IL, Nazarchuk HH. The research of antimicrobial efficacy of antiseptics decamethoxin, miramistin and their effect on nuclear DNA fragmentation and epithelial cell cycle. Wiadomosci Lekarskie (Warsaw, Poland: 1960). 2019;72(3):374-380.
8. Babina YM, Dmyrtiiiev DV, Nazarchuk OA, Hormash PP. Morphological research of the effectiveness of perioperative local use of anesthetics and antiseptics in patients with purulent-necrotic lesions of lower extremities in diabetes mellitus. Reports of Morphology. 2021;27(3):22-8.
9. Hoekstra MJ, Westgate SJ, Mueller S. Povidone-iodine ointment demonstrates in vitro efficacy against biofilm formation. International Wound Journal. 2017;14(1): 172-179.
10. Parr AM, Zoutman DE, Davidson JS. Antimicrobial activity of lidocaine against bacteria associated with nosocomial wound infection. Annals of Plastic Surgery. 1999;43(3):239-245.  
DOI: 10.1097/0000637-199909000-00003  
PMID: 10490173
11. Drosou A, Falabella A, Kirsner RS. Antiseptics on wounds: An area of controversy. Wounds. 2003;15(5):149-166.
12. Sibbald RG, Woo KY, Queen D. Wound bed preparation and oxygen balance—a new component? International Wound Journal. 2007;4:9-17.
13. Beukelman CJ, Van Den Berg AJJ, Hoekstra MJ, Uhl R, Reimer K, Mueller S. Anti-inflammatory properties of a liposomal hydrogel with povidone-iodine (Repithel®) for wound healing in vitro. Burns. 2008; 34(6):845-855.
14. Lu CW, Lin TY, Shieh JS, Wang MJ, Chiu KM. Antimicrobial effect of continuous lidocaine infusion in a *Staphylococcus aureus*-induced wound infection in a mouse model. Annals of Plastic Surgery. 2014;73(5):598-601.
15. Stratford AF, Zoutman DE, Davidson JS. Effect of lidocaine and epinephrine on *Staphylococcus aureus* in a guinea pig model of surgical wound infection. Plastic and Reconstructive Surgery. 2002;110(5): 1275-1279.
16. Kose AA, Karabağlı Y, Kiremitci A, Kocman E, Cetin C. Do local anesthetics have antibacterial effect on *Staphylococcus aureus* under in vivo conditions? An experimental study. Dermatologic Surgery. 2010;36(6):848-852.
17. Parr AM, Zoutman DE, Davidson JS. Antimicrobial activity of lidocaine against bacteria associated with nosocomial wound infection. Annals of Plastic Surgery. 1999;43(3):239-245.
18. Johnson SM, Saint John BE, Dine AP. Local anesthetics as antimicrobial agents: A review. Surgical infections. 2008;9(2): 205-213.
19. Nazarchuk OA. Antiseptics: Modern strategy of struggle with causing agents of the infection complications. Klinichna khirurgiia. 2016;9:59-61.
20. World Medical Association. Helsinki declaration of the world medical association" Ethical Principles of Medical Research with the Involvement of Human Rights as Research Objective", 01.06. 1964; 1964.
21. Olga K, Elena Y, Sviatoslav K, Dmytro D, Kostiantyn D. Dynamics of the microbiological scope and antibiotic susceptibility in intensive care unit patients. Biomedical Research and Therapy. 2020; 7(7):3860-3864.

© 2021 Babina et al.; This is an Open Access article distributed under the terms of the Creative Commons Attribution License (<http://creativecommons.org/licenses/by/4.0>), which permits unrestricted use, distribution, and reproduction in any medium, provided the original work is properly cited.

Peer-review history:  
The peer review history for this paper can be accessed here:  
<https://www.sdiarticle5.com/review-history/79077>