




REPORTS OF MORPHOLOGY

*Official Journal of the Scientific Society of Anatomists,
Histologists, Embryologists and Topographic Anatomists
of Ukraine*

journal homepage: <https://morphology-journal.com>



Microscopic and histochemical changes in the liver of adult rats with hyperhomocysteinemia

Maievskiy O. Ye.¹, Halahan Yu. V.²

¹"Institute of Biology and Medicine" of Taras Shevchenko National University, Kyiv, Ukraine

²National Pirogov Memorial Medical University, Vinnytsya, Ukraine

ARTICLE INFO

Received: 10 November 2022

Accepted: 12 December 2022

UDC: 616-001.17:615.451.3

CORRESPONDING AUTHOR

e-mail: maevskyalex8@gmail.com

Maievskiy O. Ye.

CONFLICT OF INTEREST

The authors have no conflicts of interest to declare.

FUNDING

Not applicable.

Violation of amino acids metabolism in the human body is the cause of changes in the structure and functions of almost all vital organs and systems. During the last tens of years, significant efforts of scientists have been directed to the in-depth study of such compound as homocysteine (Hcys), which is a thiol-containing amino acid and is produced endogenously during the exchange of methionine and cysteine. Under the conditions of its normal concentration (5-15 µmol/l), it does not pose a threat to the life and health of living organisms. However, in a number of pathological conditions, a pronounced increase of Hcys in blood plasma and inside cells is registered, which leads to the appearance or progression of diseases, including damage of liver tissue. The aim of the research is to study the microscopic and histochemical changes in the liver of adult rats with hyperhomocysteinemia (HHcys). The experiment was conducted on 22 white non-linear adult male rats aged 6-8 months. During the study, the animals were divided into two groups - control and experimental. Chronic resistance to HHcys was modeled by administering thiolactone Hcys in a dose of 200 mg/kg of body weight intragastrically for 60 days to the rats of the experimental group. Histological preparations were studied using a SEO SCAN light microscope and photo-documented using a Vision CCD Camera with a system of image output from histological preparations. Succinate dehydrogenase was detected histochemically according to the Nakhlash method. These studies were carried out on sections made in a cryostat microtome from unfixed tissue using nitro blue tetrazole. To study the specifics of glycogen accumulation in hepatocytes, sections were stained using Schiff's reagent, after preliminary treatment with iodic acid (PAS reaction) in the Shabadash modification. It was established that the administration of thiolactone Hcys to young rats at a dose of 200 mg/kg led to an increase in the volume of connective tissue elements around the lobules and in the portal tracts of the liver. Thus, it was established that in the liver of adult rats with HHcys, there is a noticeable thickening of the fibrous connective tissue around the lobules and in the portal tracts, trabeculae dissociation, and the appearance of foci of necrosis of the parenchyma of the organ. Hypertrophy and hyperplasia of smooth myocytes in the middle layer and fibrosis of the outer layer of the wall of interlobular arteries, leukocyte infiltration in the portal tracts are observed. A significant decrease in succinate dehydrogenase activity was established histochemically.

Keywords: hyperhomocysteinemia, liver, liver plates, fatty dystrophy, succinate dehydrogenase, rats.

Introduction

Violation of amino acids metabolism in the human body, as established, is the cause of changes in the structure and functions of almost all vital organs and systems. For tens of years, significant efforts of scientists have been directed to the in-depth study of such a compound as Hcys, which is a thiol-containing amino acid and is produced endogenously during the exchange of methionine and

cysteine. Hcys in blood plasma is able to be in protein-bound (99 %) and free (1 %) forms. Under the conditions of its normal concentration (5-15 µmol/l), it does not pose a threat to the life and health of living organisms. However, in a number of pathological conditions, a pronounced increase of Hcys is registered in blood plasma and inside cells. This condition is called HHcys and is often used as

a prognostic factor for the risk of cardiovascular diseases, diseases of the respiratory, excretory, and digestive systems, as well as screening for congenital defects of methionine metabolism, miscarriage, vitamin deficiency [4, 8, 9, 18].

The liver and kidneys are the key organs where processes of Hcys metabolism take place. In the presence of any structural and functional changes in the specified organs, deficiency of enzymes of Hcys metabolism (congenital or acquired) or insufficiency of vitamins that play the role of cofactors in these biochemical transformations (B_6 , B_9 , B_{12}), the concentration of Hcys begins to increase [20, 21]. The negative effects of HHcys are now largely established. They consist in homocysteinilation of blood plasma proteins, disruption of methylation processes, stimulation of NMDA receptors, Toll-like receptors (mainly TLR_4), dysregulation of Ca^{2+} -channels, and increased activity of NADPH oxidase. The latter fact is associated with excessive production of reactive oxygen species (ROS). ROS, in turn, trigger signaling pathways and the production of pro-inflammatory mediators - IL-1, IL-6, TNF- α , etc. In addition, HHcys leads to impaired synthesis and reduced bioavailability of NO in endothelial cells of vessel walls [18, 22]. The result of the effect of Hcys on the body is the development of myocardial infarction, disorders of cerebral blood circulation, neurodegenerative diseases [6, 10, 12, 13].

Research conducted on animals, as well as clinical observations, indicate the fact that HHcys serves as the basis for the development of not only the above-mentioned diseases, but in one way or another is a trigger of pathological processes in other body systems. In particular, there is increasing evidence that Hcys disrupts intracellular lipid metabolism, leading to their accumulation in hepatocytes [18]. This leads to the appearance of fatty hepatosis and changes in the morpho-functional parameters of the organ. A change in the structure of the liver leads to disturbances in the mechanisms of utilization of Hcys, and, therefore, becomes the cause of an even greater increase of it in the blood plasma and the progression of existing diseases. Separate literature sources also demonstrate the participation of the specified amino acid in the occurrence of cirrhosis and liver fibrosis. Thus, an urgent task is to study the peculiarities of histological changes in the organ against the background of a long-term increase in the level of Hcys in the blood plasma [2, 16, 17, 19].

The aim of the research is to study of microscopic and histochemical changes in the liver of adult rats with HHcys.

Materials and methods

The study was carried out in compliance with international recommendations on conducting medical and biological research using animals (Kyiv, Ukraine, 2001) and agreed with the provisions of the "European Convention for the Protection of Vertebrate Animals Used for Experimental and Other Scientific Purposes" (Strasbourg, France, 1986) [3]. The experiment was conducted on 22

white non-linear adult male rats aged 6-8 months. During the study, the animals were divided into two groups - control and experimental. Chronic resistance HHcys was modeled by administering thiolactone Hcys in a dose of 200 mg/kg of body weight intragastrically for 60 days to the rats of the experimental group. Animals were anesthetized by decapitation using thiopental anesthesia. For histological examination, pieces of liver were taken from pre-weighed animals of all groups. The pieces were fixed in a 10 % formalin solution, not exceeding the exposure duration of 1-2 days. Next, the pieces were dehydrated in alcohols of increasing concentration and embedded in paraffin blocks. The prepared sections, 4-5 μ m thick, were stained with hematoxylin and eosin and methylene blue [1]. Histological preparations were studied using a SEO SCAN light microscope and photo-documented using a Vision CCD Camera with a system of image output from histological preparations.

To study the dynamics of compensatory and adaptive processes of the liver under conditions of HHcys, the study of the key enzyme of the tricarboxylic acid cycle - succinate dehydrogenase - is of particular interest. This mitochondrial enzyme was detected histochemically by the method of Nakhlas [5]. These studies were carried out on sections made in a cryostat microtome from unfixed tissue using nitro blue tetrazole. The sediment in the form of blue granules of diformazan testified to the presence and localization of the enzyme.

To study the specifics of glycogen accumulation in hepatocytes, sections were stained using Schiff's reagent, after pre-treatment with iodic acid (PAS reaction) in Shabadash's modification [5].

Results

Studies of the microscopic organization of the liver of mature animals with hyperhomocysteinemia revealed more pronounced structural changes in the organ compared to young animals. A noticeable thickening of the fibrous connective tissue around the lobules and in the portal tracts was established. Dyscompletion of liver plates was revealed. In hepatocytes, the nuclei were hyperchromic, pyknotically altered. Signs of hydropic and fatty dystrophy were observed in the cytoplasm of hepatocytes. In some places, foci of necrosis of the liver parenchyma were found. Significant changes are also present in the vascular bed of the liver of mature animals. In the vast majority of central, sublobular and interlobular veins, full blood was found, their walls were expanded and thinned (Fig.1).

The thickness of the wall of interlobular arteries increased due to hypertrophy and hyperplasia of smooth myocytes in the tunica media and fibrosis of the tunica adventitia. There is leukocyte infiltration in the portal tracts. Significant changes were found in the microcirculatory bed of the liver. The lumens of the sinusoids were expanded, often filled with formal elements. Endothelial cells were

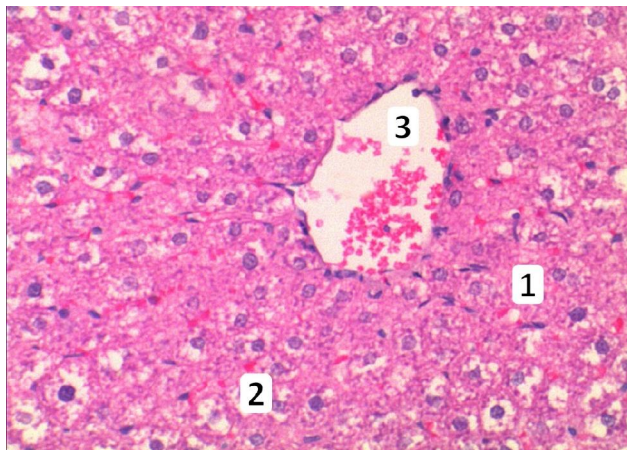


Fig. 1. Histological changes in the liver of mature animal after simulated hyperhomocysteinemia. 1 - violation of the hepatocyte plates organization of the organ, 2 - dystrophically changed hepatocytes, 3 - enlarged central vein. Staining with hematoxylin and eosin. x200.

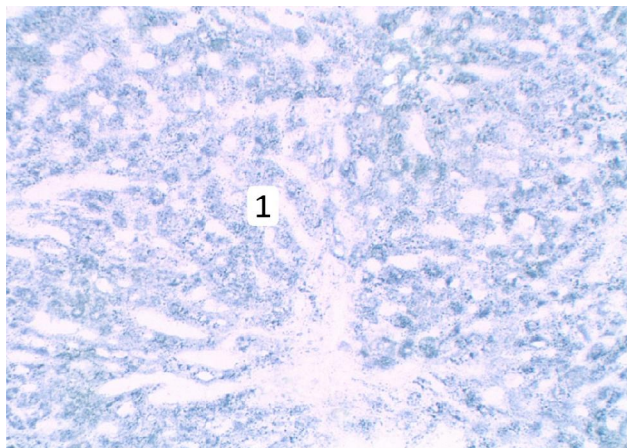


Fig. 2. Low activity of succinate dehydrogenase in the liver of a mature animal under conditions of simulated hyperhomocysteinemia. 1 - in the cytoplasm of most hepatocytes, there were few clumps of diformazan. Nakhlash method. x 200.

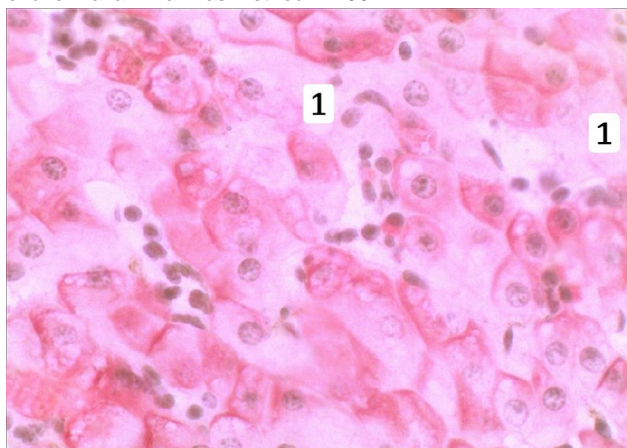


Fig. 3. The presence of glycogen in the liver of a mature animal under conditions of simulated hyperhomocysteinemia. 1 - low content of glycogen lumps in the cytoplasm of hepatocytes. Shabadash method. x400.

partially damaged, their nuclei were hyperchromic, pyknotically altered, and the cytoplasm was swollen and uneven. Perisinusoidal spaces are expanded, infiltrated by leukocytes and macrophages.

A significant decrease in succinate dehydrogenase activity was established histochemically. There were few lumps of diformazan in hepatocytes, they were weakly basophilic (Fig. 2).

Histochemical study of the presence of glycogen in the hepatocytes of the liver of mature animals under the conditions of simulated hyperhomocysteinemia showed a decrease in the content of the indicated trophic compound in the cytoplasm of cells, in some cells the cytoplasm is practically devoid of this trophic compound (Fig. 3).

Discussion

Related studies conducted on experimental animals accompanied by simulation of chronic HHcys showed a negative effect of this amino acid on the structural and functional indicators of various body systems.

It was established that in adult rats with persistent HHcys, the organs of the respiratory system underwent changes in the form of the development of dyscirculatory disorders, remodeling of bronchiole walls, and inflammatory processes. The lumens of the bronchi were narrowed, spasmodic, filled with serous-mucous contents. Desquamation of the epithelial lining in their lumen was found in some places. The bronchial walls were swollen, infiltrated with histiocytic cells, neutrophils, and lymphocytes. Zones of dysatelectases and atelectasis in the respiratory department were a characteristic finding. Zones of emphysematous-changed areas of lung tissue were also detected. Under these conditions, HHcys was associated with an increase in the activity of fibroblasts and thickening of the walls of the alveoli, which led to a violation of normal gas exchange. This process was complicated by damage of the vessel walls, and, therefore, to the components of the air-blood barrier [15].

R. F. Kaminsky et al. [7] studying the structure of the heart of laboratory animals under conditions of HHcys at the submicroscopic level revealed damage of the organ in the form of its dystrophic and destructive changes. Endocardium and myocardium were involved in the pathological process. The first was characterized by thickening of collagen fibers and significant swelling of the components of the main substance. In the myocardium, cardiomyocytes underwent pronounced changes. They lost myofibrils, sarcomeres were disorganized. Mitochondria of the cells were swollen, their matrix was illuminated, and the crystals showed signs of destruction. The tubules of smooth ER expanded significantly. The components of the connective tissue also actively increased their volume in the myocardium, in particular, the thickening of collagen fibers was recorded. Violation of the structural organization of vessels of the microcirculatory bed of the myocardium was observed.

Recent studies [14] have shown the presence of a relationship between biochemical changes in thyroid tissue and the level of Hcys in the blood plasma of experimental rats. HHcys in animals was accompanied by the development of catabolic processes, which were characterized by the accumulation of low-molecular-weight compounds in the blood and homogenates of the thyroid gland. Biochemical studies also revealed the activation of proteolytic processes in the organ, which was evidenced by an increase in the levels of matrix metalloproteinases (MMP-2). Also, proteolysis in the tissue of the thyroid gland was confirmed by a significant shift in the protein profile. The accumulation of proteins with a molecular weight <30 kDa and a decrease in high molecular weight proteins were recorded. The activation of inflammatory processes was characteristic and confirmed by the increase of the corresponding cytokines [14].

Ultramicroscopic studies of liver tissue under conditions of HHcys against the background of hypo- and hyperthyroidism demonstrated the presence of significant disturbances in microcirculation and transcapillary exchange in the organ. At the same time, hepatocytes were characterized by damage of the nuclei and cytoplasm

structure. Similar rearrangements were observed in the endotheliocytes of the blood vessels vascular walls of the liver. The authors note that compensatory and adaptive, destructive and necrotic changes developed in the organ. The components of the nuclei and organelles of hepatocytes underwent irreversible changes, which ultimately led to a violation of the synthetic and detoxification functions of the liver [10, 11].

Conclusion

1. In adult rats, the simulation of the HHcys state led to an increase in the volume of connective tissue elements around the lobules and in the portal tracts of the liver. Disassembly of the liver plates, changes in the nuclear apparatus of hepatocytes, the development of their hydropic and fatty dystrophy, areas of necrosis of the tissue of the organ, changes in the structure of vessels, and disruption of microcirculation processes were characteristic.

2. Histochemical studies under these conditions established a decrease in the activity of succinate dehydrogenase of mitochondria and the content of glycogen in the cytoplasm of hepatocytes.

References

- [1] Bahrii, M. M., Dibrova, V. A., Popadynets, O. H. & Hryshchuk, M. I. (2016). *Методику морфологічних досліджень [Methods of Morphological Research]*. Вінниця: Нова Книга - Vinnytsia: New Book.
- [2] Dai, Y., Zhu, J., Meng, D., Yu, C., & Li, Y. (2016). Association of homocysteine level with biopsy-proven non-alcoholic fatty liver disease: a meta-analysis. *J. Clin. Biochem. Nutr.*, 58(1), 76-83. doi: 10.3164/jcbn.15-54
- [3] Dobrelia, N. V., Boitsova, L. V. & Danova, I. V. (2015). Правова база для проведення етичної експертизи доклінічних досліджень лікарських засобів з використанням лабораторних тварин [Legal basis for ethical examination of preclinical studies of drugs using laboratory animals]. *Фармакологія та лікарська токсикологія - Pharmacology and Drug Toxicology*, (2), 95-100.
- [4] Familtseva, A., Jeremic, N., Kunkel, G. H., & Tyagi, S. C. (2017). Toll-like receptor 4 mediates vascular remodeling in hyperhomocysteinemia. *Mol. Cell. Biochem.*, 433(1-2), 177-194. doi: 10.1007/s11010-017-3026-9
- [5] Horalskyi, L. P., Khomych, V. T., & Kononskyi, O. I. (2011). *Основи гістологічної техніки і морфофункціональні методи досліджень у нормі та при патології [Fundamentals of histological technique and morphofunctional research methods in normal and pathology]*. Житомир: Полісся - Zhytomyr: Polissya.
- [6] Jakubowski, H. (2019). Homocysteine Modification in Protein Structure/Function and Human Disease. *Physiol. Rev.*, 99(1), 555-604. doi: 10.1152/physrev.00003.2018
- [7] Kaminsky, R. F., Dzevulska, I. V., Yanchyshyn, A. Ya., Matkivska, R. M., & Samborska, I. A. (2022). Submicroscopic changes in the heart of adult rats under conditions of persistent hyperhomocysteinemia. *Reports of Morphology*, 3(28), 21-25. doi: 10.31393/morphology-journal-2022-28(3)-03
- [8] Kaplan, P., Tatarkova, Z., Sivonova, M. K., Racay, P., & Lehotsky, J. (2020). Homocysteine and Mitochondria in Cardiovascular and Cerebrovascular Systems. *Int. J. Mol. Sci.*, 21(20), 7698. doi: 10.3390/ijms21207698
- [9] Kumar, A., Palfrey, H. A., Pathak, R., Kadowitz, P. J., Gettys, T. W., & Murthy, S. N. (2017). The metabolism and significance of homocysteine in nutrition and health. *Nutr. Metab. (Lond)*, 14, 78. doi: 10.1186/s12986-017-0233-z
- [10] Leach, N. V., Dronca, E., Vesa, S. C., Sampelean, D. P., Craciun, E. C., Lupsor, M. ... Grigorescu, M. (2014). Serum homocysteine levels, oxidative stress and cardiovascular risk in non-alcoholic steatohepatitis. *Eur. J. Intern. Med.*, 25(8), 762-767. doi: 10.1016/j.ejim.2014.09.007
- [11] Nechiporuk, V. M., Nebesna, Z. M., Kovalchuk, O. V., Pentiuik, L. O., & Korda, M. M. (2021). Ультраструктурні зміни печінки при експериментальній гіпергомоцистеїнемії на тлі гіпота гіпертиреозу [Ultrastructural changes in the liver in experimental hyperhomocysteinemia on the background of hypo- and hyperthyroidism]. *Вісник медичних і біологічних досліджень - Bulletin of Medical and Biological Research*, 2(8), 51-60. doi: 10.11603/bmbr.2706-6290.2021.2.12339
- [12] Pi, T., Liu, B., & Shi, J. (2020). Abnormal Homocysteine Metabolism: An Insight of Alzheimer's Disease from DNA Methylation. *Behav. Neurol.*, 2020, 8438602. doi: 10.1155/2020/8438602
- [13] Poddar, R. (2021). Hyperhomocysteinemia is an emerging comorbidity in ischemic stroke. *Exp. Neurol.*, 336, 113541. doi: 10.1016/j.expneurol.2020.113541
- [14] Raksha, N., Halenova, T., Maievsyi, O., Dzevulska, I., Kaminsky, R., Yanchyshyn, A. ... Kovalchuk, O. (2022). Biochemical disorders in the thyroid gland in rats with hyperhomocysteinemia. *Biomedical Research and Therapy*, 9(5), 5065-5074. doi: 10.15419/bmrat.v9i5.740
- [15] Samborska, I. A. (2019). Features of histological changes in the lungs of mature animals under conditions of hyperhomocysteinemia. *Biomedical and Biosocial Anthropology*, 37, 32-37. doi: 10.31393/bba37-2019-05

- [16] Samborska, I., Kovalchuk, O., Fagoonee, S., Falalyeyeva, T., & Maievskiy, O. (2020). The role of hyperhomocysteinemia in the development of changes in the lungs. *Reviews on Recent Clinical Trials*, 15(1), 48-59. doi: 10.2174/1574887114666191114152235
- [17] Visram, M., Radulovic, M., Steiner, S., Malanovic, N., Eichmann, T. O., Wolinski, H. ... Tehlivets, O. (2018). Homocysteine regulates fatty acid and lipid metabolism in yeast. *J. Biol. Chem.*, 293(15), 5544-5555. doi: 10.1074/jbc.M117.809236
- [18] Yang, F., Qi, X., Gao, Z., Yang, X., Zheng, X., Duan, C. ... Zheng, J. (2016). Homocysteine injures endothelial cells by inhibiting mitochondrial activity. *Exp. Ther. Med.*, 12(4), 2247-2252. doi: 10.3892/etm.2016.3564
- [19] Yang, A., Jiao, Y., Yang, S., Deng, M., Yang, X., Mao, C. ... Jiang, Y. (2018). Homocysteine activates autophagy by inhibition of CFTR expression via interaction between DNA methylation and H3K27me3 in mouse liver. *Cell Death and Disease*, 9(2), 169. doi: 10.1038/s41419-017-0216-z
- [20] Yuan, S., Mason, A. M., Carter, P., Burgess, S., & Larsson, S. C. (2021). Homocysteine, B vitamins, and cardiovascular disease: a Mendelian randomization study. *BMC Med.*, 19(1), 97. doi: 10.1186/s12916-021-01977-8
- [21] Zaric, B. L., Obradovic, M., Bajic, V., Haidara, M. A., Jovanovic, M., & Isenovic, E. R. (2018). Homocysteine and Hyperhomocysteinemia. *Curr. Med. Chem.*, 26(16), 2948-2961. doi: 10.2174/092986732666180313105949
- [22] Zbidi, H., Redondo, P. C., Lopez, J. J., Bartegi, A., Salido, G. M., & Rosado, J. A. (2010). Homocysteine induces caspase activation by endoplasmic reticulum stress in platelets from 2 diabetics and healthy donors. *Thromb. Haemost.*, 103(5), 1022-1032. doi: 10.1160/TH09-08-0552

МІКРОСКОПІЧНІ ТА ГІСТОХІМІЧНІ ЗМІНИ ПЕЧІНКИ ДОРΟΣЛИХ ЩУРІВ З ГІПЕРГОМОЦИСТЕЇНЕМІЄЮ

Маєвський О. Є., Галаган Ю. В.

Порушення метаболізму амінокислот в організмі людини є причиною зміни структури та функцій майже всіх вітальних органів і систем. Впродовж останніх десятиріч років значні зусилля науковців спрямовані на поглиблене вивчення такої сполуки як гомоцистеїн (Гц), що є тіополімерною амінокислотою та продукується ендогенно в ході обміну метіоніну й цистеїну. За умов його нормальної концентрації (5-15 мкмоль/л) він не становить загрози для життя та здоров'я живих організмів. Однак, за умови виникнення низки патологічних станів реєструють вірогідне збільшення концентрації Гц у плазмі крові та всередині клітин, що призводить до появи чи прогресування хвороб, в тому числі ураження тканини печінки. Метою дослідження стало встановлення мікроскопічних та гістохімічних змін печінки дорослих щурів з гіпергомоцистеїнемією (ГГц). Експеримент проведений на 22 білих нелінійних дорослих щурах-самцях, віком 6-8 місяців. При дослідженні тварин розподіляли на дві групи - контрольну і дослідну. Хронічну стійку ГГц моделювали введенням щурам дослідної групи тіоплактону Гц в дозі 200 мг/кг маси тіла інтрагастрально впродовж 60 діб. Гістологічні препарати вивчали за допомогою світлового мікроскопа SEO SCAN та фотодокументували за допомогою відеокамери Vision CCD Camera з системою виводу зображення з гістологічних препаратів. Гістохімічно виявляли сукцинатдегідрогеназу за методом Нахласа. Ці дослідження здійснювали на зрізах, виготовлених в мікромом-кріостаті з нефіксованої тканини з використанням нітро-синього тетразолу. Для дослідження особливостей накопичення глікогену в гепатоцитах проводили забарвлення зрізів за допомогою реактиву Шиффа, після попередньої обробки йодною кислотою (PAS-реакція) в модифікації Шабадаша. Введення тіоплактону Гц молодим щурам в дозі 200 мг/кг призводило до збільшення об'єму елементів сполучної тканини навколо часточок та в портальних трактах печінки. Таким чином, встановлено, що у печінці дорослих щурів з гіпергомоцистеїнемією відбувається помітне потовщення волокнистої сполучної тканини навколо часточок та у складі портальних трактів, дисконплектація печінкових балок, поява осередків некрозу паренхіми органу. Спостерігаються гіпертрофія та гіперплазія гладких м'язів у середній оболонці та фіброз зовнішньої оболонки стінки міжчасточкових артерій, лейкоцитарна інфільтрація в портальних трактах. Гістохімічно встановлене значне зниження активності сукцинатдегідрогенази.

Ключові слова: гіпергомоцистеїнемія, печінка, печінкові пластинки, жирова дистрофія, сукцинатдегідрогеназа, щури.