




REPORTS OF MORPHOLOGY

Official Journal of the Scientific Society of Anatomists,
Histologists, Embryologists and Topographic Anatomists
of Ukraine

journal homepage: <https://morphology-journal.com>



The influence of chronic hyperhomocysteinemia on the structure and immune processes of the spleen in young rats

Dzevulska I. V.¹, Gritsenko A. S.², Tymoshenko I. O.¹, Zakalata T. R.², Lavrinenko V. Y.³, Smolko D. G.², Gunas I. V.²

¹Bogomolets National Medical University, Kyiv, Ukraine

²National Pirogov Memorial Medical University, Vinnytsya, Ukraine

³Educational and Scientific Center "Institute of Biology and Medicine", Taras Shevchenko National University of Kyiv, Kyiv, Ukraine

ARTICLE INFO

Received: 07 December 2023

Accepted: 12 January 2024

UDC: 61:615.9/616:616-005/616.4

CORRESPONDING AUTHOR

e-mail: grytsenko.antonina@gmail.com
Gritsenko A. S.

CONFLICT OF INTEREST

The authors have no conflicts of interest to declare.

FUNDING

Not applicable.

DATA SHARING

Data are available upon reasonable request to corresponding author.

Homocysteine is a sulfur-containing amino acid that is an intermediate product of methionine metabolism. Entering the body with products of animal origin, methionine undergoes a number of biochemical transformations. Hyperhomocysteinemia has a negative effect on the body, causing damage to all organs and systems and leading to disruption of homeostasis. The study aims to study the characteristics of changes in the structure and immune processes of the spleen of young rats with chronic hyperhomocysteinemia. Experiments were performed on 22 white male rats. The animals were divided into control and experimental groups (11 individuals in each group) during the experiment. Chronic hyperhomocysteinemia was achieved by administering D, L-thiolactone homocysteine hydrochloride to experimental group animals at a dose of 200 mg/kg of body weight intragastrically in a 1 % starch gel solution once a day for eight weeks. After the end of the experimental simulation of chronic hyperhomocysteinemia, the animals were removed from the experiment by anaesthetising by decapitation and using thiopental anaesthesia. Histological preparations were studied using an SEO SCAN light microscope. Experimental modelling of chronic hyperhomocysteinemia in young rats was not accompanied by significant morphological changes in the stroma and red pulp of the spleen. T-cell periaarterial sheaths and B-cell nodules in animals from the experimental group underwent changes. B-cell proliferation leads to growth within the white pulp, expansion of the marginal zones, which become more blurred and infiltration of these cells into the red pulp. Evaluation of the red pulp in the spleen of young rats from the experimental group showed a particular expansion in the venous sinuses, which may be a sign of reaction to the influence of homocysteine and slight swelling of these vessels. The number of T-cells in young animals in the periaarterial cuffs is slightly reduced, which can be explained by the increasing activity of macrophages. However, T-cells also infiltrated the red pulp. Such penetration of white blood cells into the red pulp is accompanied by the expansion and "washing out" of the marginal zones of lymph nodes. Thus, the increased homocysteine level significantly potentiated proliferation and partially inhibited apoptosis in T-lymphocytes but did not directly affect dormant T-cells.

Keywords: homocysteine, spleen, lymphocytes, macrophages, rats.

Introduction

Homocysteine is a sulfur-containing amino acid that is an intermediate product of methionine metabolism. Entering the body with products of animal origin, methionine undergoes some biochemical transformations. Normally, homocysteine is utilised in the body in remethylation, transsulfation, and desulfation reactions [25]. The transsulfonation pathway begins by condensing two

molecules of homocysteine and serine, forming cystathionine. This reaction is catalysed by the pyridoxal phosphate-dependent enzyme cystathionine- β -synthase [29]. Subsequently, cysteine, ammonia and α -ketobutyrate are formed from cystathionine under the influence of cystathionine- γ -lyase. During remethylation processes, methionine is resynthesised from homocysteine with the

help of cobalamin-dependent methionine synthase. There is also another path of remethylation involving the enzyme betaine-homocysteine-S-methyltransferase. Both enzymes are cytosolic and characterised as zinc-dependent methyltransferases. Methionine synthase is present in all body tissues and uses N-5-methyltetrahydrofolate as a metal group. Betaine-homocysteine-S-methyltransferase uses an endogenous derivative of choline-betaine and is present to a greater extent in the liver, adrenal cortex, brain tissue, skeletal muscles, and placenta. When utilising homocysteine by desulfation, it turns into hydrogen sulfide [18].

In blood plasma, homocysteine is present in four forms: homocysteine bound to proteins, the disulfide form of homocysteine, free homocysteine, and the thiol form of homocysteine [31]. According to most authors, its normal level in the body is within 5-15 $\mu\text{mol/l}$. It has been established that homocysteine concentration varies with age and gender [16, 17]. Compared to children, its content is 2 times higher in adults. During life, the level of homocysteine in the blood increases, correlating with the concentration of vitamin B12 and folate. Normally, it is important for the body, as it maintains the essential amino acid methionine content constantly [26, 27]. However, a significant increase in its concentration has some negative effects [12, 19]. Hyperhomocysteinemia is diagnosed when the homocysteine content is above 15 $\mu\text{mol/l}$. Scientists distinguish its following degrees: mild, in which homocysteine ranges between 15-30 $\mu\text{mol/l}$, moderate - 30-100 $\mu\text{mol/l}$, severe - 100 $\mu\text{mol/l}$ and more [33].

Genetic causes of hyperhomocysteinemia are relatively rare but cause the development of severe pathologies and even death in childhood. Congenital defects of the methylenetetrahydrofolate reductase, cystathionine- β -synthase and methionine synthase genes are studied. Mutations of methylenetetrahydrofolate reductase are the most studied. Those associated with replacing one nucleotide in the gene encoding this enzyme (C677T and A1298 C) are more common. In the first case, valine is replaced by alanine, which leads to the synthesis of a thermolabile enzyme characterised by a decrease in its activity in heterozygotes and homozygotes by 35-50 % and 70 %, respectively. Another defect causes glutamate substitution for alanine in the C-terminal regulatory domain of methylenetetrahydrofolate reductase and is accompanied by moderate hyperhomocysteinemia. Mutations of cystathionine- β -synthase are characterised by a significant increase in the concentration of homocysteine in the blood plasma, in some cases by 80%, and the appearance of homocysteinuria, which is a missense mutation and deletion of alleles. A mutation of the A2756G gene encoding methionine synthase is also known, accompanied by decreased enzyme activity and moderate hyperhomocysteinemia [2].

Experimental studies on animals made it possible to establish the main causes of homocysteine toxicity in the

body [22, 28]. To date, scientists have singled out the main ones, namely: homocysteine activation of oxidative stress and endoplasmic reticulum stress, disruption of gene expression, protein homocysteine, stimulation of the production of inflammatory mediators and fibrosis [4, 11, 30].

Hyperhomocysteinemia has a negative effect on the body, causing damage to all organs and systems and leading to a violation of homeostasis due to the impossibility of maintaining their functions at the proper level [21]. The scientific community is actively studying the role of homocysteine in the pathogenesis of numerous diseases [14, 23, 24]. However, in the domestic literature, there is only insignificant data on its influence on the structure and functions of immune defence organs.

The study aims to study the characteristics of changes in the structure and immune processes of the spleen of young rats with chronic hyperhomocysteinemia.

Materials and methods

Modelling of chronic hyperhomocysteinemia was carried out through experimental studies on laboratory rats in compliance with international recommendations on the performance of medical and biological research using animals by the "General Principles of Work on Animals" approved by the 1st National Congress on Bioethics (Kyiv, Ukraine, 2001) and agreed with the provisions "European Convention for the Protection of Vertebrate Animals Used for Experimental and Other Scientific Purposes" (Strasbourg, France, 1986) [7]. Bioethics Committee of National Pirogov Memorial Medical University confirmed that the work complied with ethical principles (protocol No. 3 from 17.10.2019).

Experiments were performed on 22 white male rats obtained from the vivarium of the National Pirogov Memorial Medical University, Vinnytsya. Rats were kept under normal laboratory conditions with a 12-hour day/night regime; water and balanced pelleted feed were received ad libitum by established norms.

The animals were divided into control and experimental groups (11 individuals in each group) during the experiment. Chronic hyperhomocysteinemia was achieved by administering D, L-thiolactone homocysteine hydrochloride (Acros Organics, Italy) to animals of the experimental group at a dose of 200 mg/kg of body weight intragastrically in a 1 % solution of starch gel (1 ml/100 g of rat weight) once a day for 8 weeks. After the end of the experimental simulation of chronic hyperhomocysteinemia, the animals were removed from the experiment by decapitation and using thiopental anaesthesia (thiopental sodium 100 mg/kg).

For microscopic examination, pieces of spleen were taken from prematurely weighed animals of all groups. The selected samples were fixed in a 10 % formalin solution. The next stage was the dehydration of samples in alcohols of increasing concentration and pouring them into paraffin blocks. Sections with a thickness of 3 μm were

made from paraffin blocks and stained with hematoxylin and eosin [10]. Histological preparations were studied using an SEO SCAN light microscope and photo-documented by a Vision CCD Camera with a system of image output from histological preparations.

Results

When assessing the state of the spleen of rats subjected to the simulation of chronic persistent hyperhomocysteinemia, we focused our attention primarily on the elements of the white pulp of this hematopoietic organ because exactly lymphocytes are most sensitive to high levels of homocysteine. In turn, substances that fight free radicals reduce the proliferation of lymphocytes caused by hyperhomocysteinemia.

The stroma of the spleen of young animals from the experimental group did not undergo significant changes - the dense connective tissue of the capsule and trabeculae

does not show signs of stratification or morphological changes in cells, the nuclei of single fibroblasts are spread between wavy eosinophilic collagen fibres (Fig. 1 A). This group's spleen's blood vessels also show no signs of pathological changes. We can observe the nuclei of smooth myocytes and endothelial cells without pathology (Fig. 1 B).

In the experimental groups, changes are most likely localised within the white pulp. T-lymphocytes, located in the sheath around the central arteries, practically do not show changes in morphology. However, the cells do not form such dense dark clusters, which is probably explained by the presence of a greater number of macrophages, which, on the one hand, destroy damaged and defective cells, reducing the number of their populations, on the other hand, have a lower nuclear-cytoplasmic ratio and therefore form a lighter overall background of the periarterial sheath (see Fig. 1 B, Fig. 1 C, D).

Elevated levels of homocysteine and related compounds

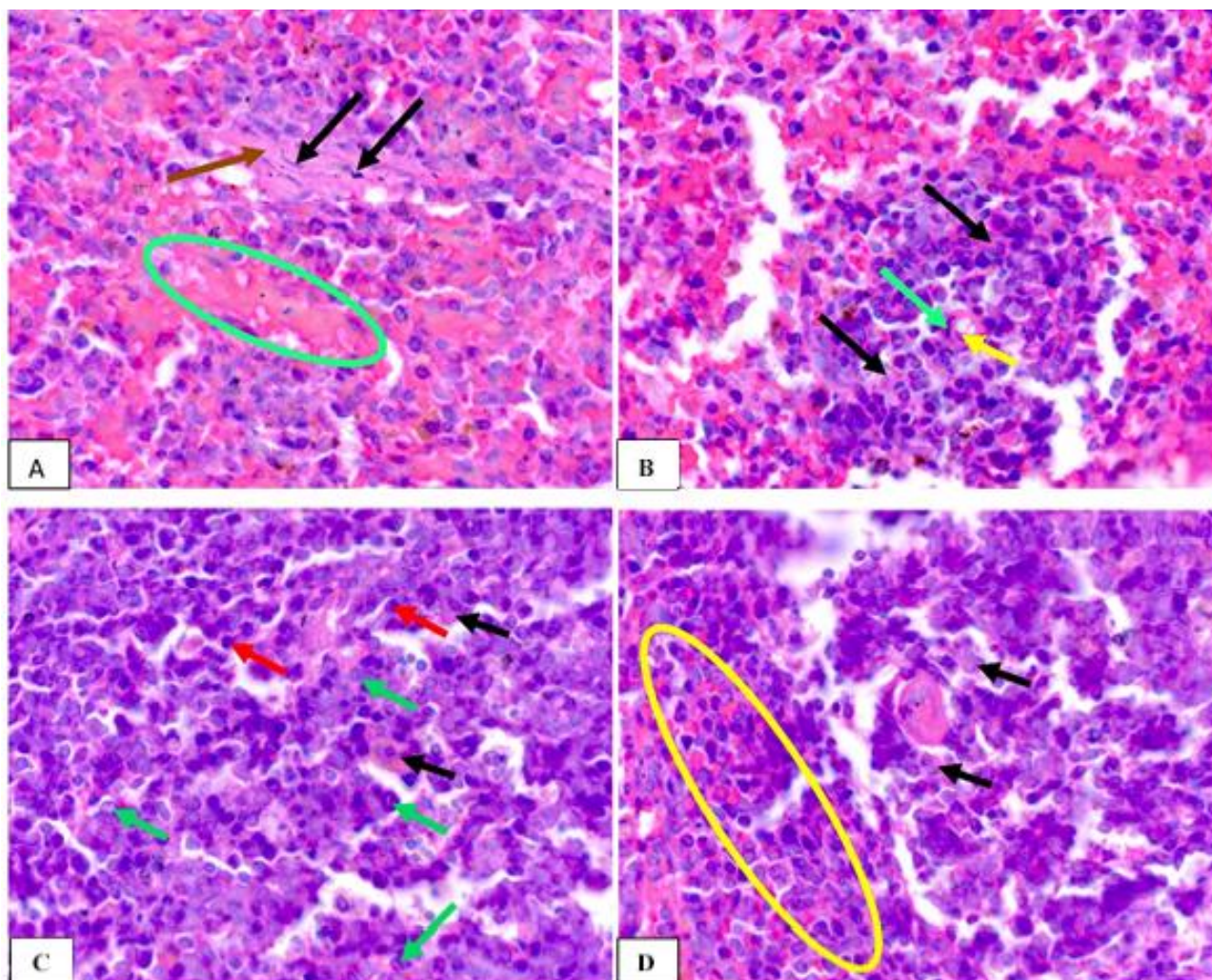


Fig. 1. Stroma and parenchyma of the spleen of young rats of the experimental group. **A:** nuclei of fibroblasts (black arrows), collagen fibres of the capsule (brown arrow), venous sinus (green oval); **B:** nucleus of a smooth myocyte (green arrow), endotheliocyte nucleus (yellow arrow); **C:** B-lymphocytes (red arrows), plasma cells (green arrows); **D:** marginal zone (yellow oval); B, C, D: macrophages (black arrows). Staining with hematoxylin and eosin. x1000.

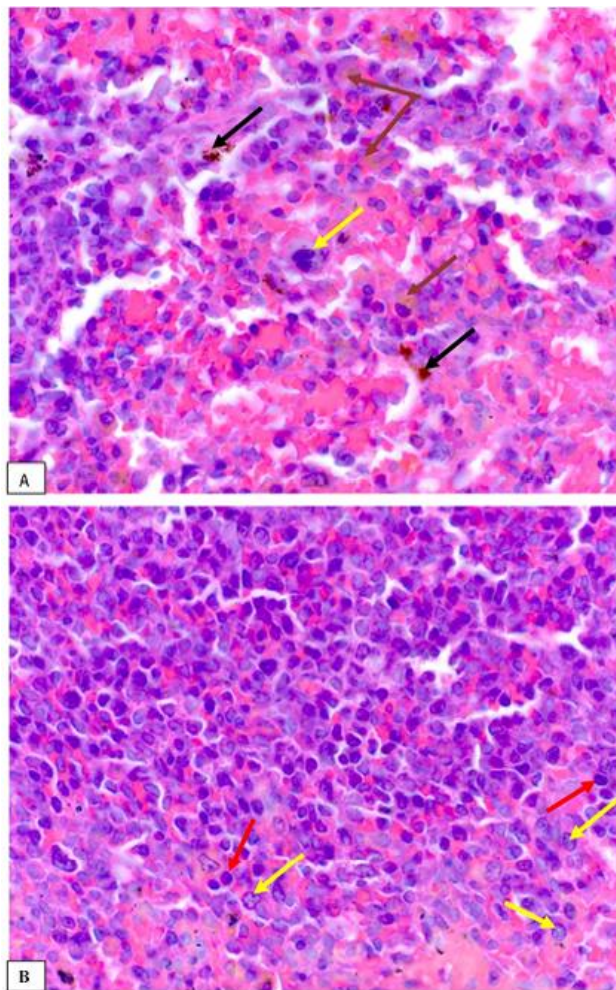


Fig. 2. Red and white pulp of young rats with chronic hyperhomocysteinemia. **A:** megakaryocyte (yellow arrow), macrophages with hemosiderin (black arrows), macrophages with lipofuscin (brown arrows); **B:** infiltration of plasma cells into the red pulp (yellow arrows), lymphocytes (red arrows). Staining with hematoxylin and eosin. x1000.

such as cysteine and glutathione significantly potentiated proliferation and partially inhibited apoptosis in T-lymphocytes but didn't directly affect latent T-cells.

B-lymphocytes and their derivatives (plasma cells), in turn, increase in number, which can be judged by the density of the location of these cells in the lymphoid nodes of the spleen of experimental animals (see Fig. 1 C). Numerous proliferating B-lymphoblasts are accompanied by macrophages, which carry out antigen-dependent B-cell differentiation before transforming into plasma cells. Plasma cells are fairly easily differentiated by their rounded or oval shape and a large amount of dark blue cytoplasm with a pale perinuclear region corresponding to the Golgi apparatus. These cells have a round, eccentrically located nucleus with heterochromatin arranged in a dial (wheel spokes).

The assessment of the state of red pulp in the spleen of

young experimental rats showed a certain expansion in the venous sinuses, which may be a sign of reaction to external influences in the slight swelling of these vessels (see Fig. 1 A). In the red pulp of young animals, the hematopoietic processes continue, so detecting megakaryocytes among erythrocytes is not a deviation from the norm (Fig. 2 A). These cells, as known, are the precursors of platelets and, reaching large sizes, later disintegrate into single blood platelets.

Also very interesting is the presence in both white and red pulp macrophages of not only dark brown inclusions of hemosiderin, which is a physiological consequence of the breakdown of erythrocytes phagocytosed by them, but also lipofuscin (see Fig. 2 A). It is known that lipofuscin is the pigment inclusion which characterises the intensity of lipid oxidation processes in the spleen, which most likely leads to an increase in the concentration of free oxygen radicals in this organ and is typical for chronic hyperhomocysteinemia.

As already mentioned, when assessing the condition of the spleen under the influence of chronic hyperhomocysteinemia, it is necessary to pay attention to the lymphocytic component, not only of the white but also of the red pulp. It is interesting to note the infiltration of these cells into the red pulp, which is a characteristic sign of their proliferation in response to oxidative stress (Fig. 2 B). The number of small cells with dark nuclei (T-lymphocytes) and plasma cells, which can be recognised by the characteristic pattern of heterochromatin in the nucleus, indicates an increase in the percentage of lymphocytes in the red pulp in response to stimulation of chronic hyperhomocysteinemia in animals. Such penetration of white blood cells into the red pulp is accompanied by expansion and "blurring" of the marginal zones of lymph nodes, which are not as clearly defined as in the control group (see Fig. 1 D).

Discussion

Thus, homocysteine can disrupt the functioning of individual parts of the immune system through the death of cells or their excessive hyperstimulation, which in turn leads to exhaustion of the system as a whole. However, to this day, there is no data on changes in the structure of hematopoietic organs and immune protection, mainly the spleen, under conditions of hyperhomocysteinemia.

Experiments on rats proved that lymphocytes express NMDA receptors on their surface, capable of interacting with homocysteine. Under its influence, the amount of ROS and the content of Ca²⁺ and ATP in cells increases. In addition, hyperhomocysteinemia stimulates the production of IFN- γ and TNF- α by lymphocytes, involving protein kinase, NADPH-oxidase and NO-synthase. The consequence of such exposure is the death of lymphocytes by apoptosis. Constant stimulation of immune system cells under these conditions leads to its exhaustion [5, 20].

According to the literature, homocysteine interacts with inotropic glutamate receptors activated by NMDA. Activation of these receptors leads to an increase in the entry of Ca²⁺ ions into the cell and an increase in the level of reactive

oxygen species, activation of the lipid peroxidation processes and apoptosis of lymphocytes. It should be noted that the blockade of NMDA receptors of T cells with homocysteine inhibits mRNA synthesis and increases the secretion of INF- γ , TNF- α , and IL-10. Its single administration is accompanied by a pronounced decrease in T-lymphocytes and their subpopulations [15]. According to the authors, this is due to an increase in the expression of adhesion molecules to both endothelial cells and lymphocytes, which ensures the adhesion of lymphocytes to the vascular wall and, thereby, a reduction in the pool of circulating lymphocytes. Some may be eliminated due to the activation of NMDA receptors with the subsequent development of apoptosis. However, under conditions of chronic hyperhomocysteinemia in animals, on the contrary, an increase in the number of T-lymphocytes at the expense of T-cytotoxic ones was registered. When homocysteine is administered 1 time per day for a week in animals, apparently, adaptation mechanisms are activated, which allows the inactivation of aminothiols as a xenobiotic. High doses of homocysteine damage the tissue structures of the spleen, which is accompanied by the development of autoimmune reactions, evidenced by a sharp increase in the concentration of all cytokines and especially IL-17A [1, 9].

Reviews of the literature show that, in many cases, pathologies associated with the accumulation of homocysteine are accompanied by a malfunction of the immune system. On the other hand, intensive immunocompetent cell proliferation can lead to homocysteine accumulation. For example, sources report that a Th1-type immune response promotes the development of B cells and may be a major determinant of the progression of disorders associated with hyperhomocysteinemia. Other studies also demonstrate that reactive oxygen species formed due to autooxidation of homocysteine participate in the induction of B-lymphocyte proliferation [6].

The study of the effect of homocysteine on lymphocytes in patients with coronary heart disease showed that Fas-receptors of T-helpers and their ligand CD178 were activated in the culture of peripheral blood cells during its growth. An early marker of apoptosis was the expression of APO 2.7. Subsequently, negatively charged phospholipids, mainly phosphatidylserine, appeared on the cell membrane. At the same time, the concentration of Bcl-2, which normally protects cells from apoptosis, decreased, leading to their death [13, 32].

In the model of folate-induced hyperhomocysteinemia, the instability of the genomic DNA of the rat spleen was

revealed, which is expressed by a decrease in elastic viscosity and molecular weight, as well as an increase in its availability for hydrolysis by DNase I and EcoRI restriction enzyme [19].

It is known that homocysteine can be involved in the metabolic processes of cell mitochondria, increasing the production of reactive oxygen species and the level of Ca²⁺ ions, which leads to disorders of tissue respiration and an increase in the membrane potential of organelles. Being involved in the mitochondrial metabolism of T-lymphocytes causes their reprogramming. The specified changes in T-cells trigger the mechanisms of endoplasmic reticulum stress development, which in the spleen is manifested by an increase in their markers - p-eIF2 α , p-PERK, IRE-1 α , XBP-1 [8].

D. Zhang and others. [33] proved that severe hyperhomocysteinemia causes inflammatory differentiation of monocytes in the red bone marrow and increases blood plasma levels of TNF- α , IL-6, and production of superoxide anion, IFN- γ . The author notes that similar processes under these conditions are also observed in primary splenocytes of rats, and the cause is the activation of oxidative stress by homocysteine.

B. Cai and others. [3] demonstrated in their experimental studies that elevated levels of homocysteine cause apoptosis of red bone marrow stem cells by activating JNK1 (N-terminal kinase of the myogen-activated protein kinase family).

In the literature, there are also references to the fact that homocysteine significantly increases B-lymphocyte proliferation in the spleen. Researchers associate the cause of this phenomenon with the activation of protein kinase C and nuclear factor kappa B (NF- κ B) [34, 35].

Conclusions

1. Experimental modelling of chronic hyperhomocysteinemia in young rats was not accompanied by significant morphological changes in the stroma and red pulp of the spleen.

2. T-cell periarterial sheaths and B-cell nodules in animals from the experimental group underwent changes. B-cell proliferation leads to growth within the white pulp, expansion of the marginal zones, which become more blurred and infiltration of these cells into the red pulp.

3. The number of T-cells in young animals in the periarterial sheaths is slightly reduced, which can be explained by the increasing activity of macrophages. However, T-cells also infiltrated into the red pulp.

References

- [1] Abe, I., Shirato, K., Hashizume, Y., Mitsuhashi, R., Kobayashi, F., Shiono, C., ... & Imaizumi, R. (2013). Folate-deficiency induced cell-specific changes in the distribution of lymphocytes and granulocytes in rats. *Environ. Health Prev. Med.*, 18(1), 78-84. doi: 10.1007/s12199-012-0286-6
- [2] An, H., Fan, C. Q., Duan, J. G., Ren, Y., Dong, K., Zhang, Q., ... & Huang, X. Q. (2018). Severe Hyperhomocysteinemia with

- Two Novel Mutations of c.154T > C and c.4576G > A in Cystathionine Beta-Synthase Gene. *Chin. Med. J. (Engl)*, 131(19), 2368-2370. doi: 10.4103/0366-6999.241801
- [3] Cai, B., Li, X., Wang, Y., Liu, Y., Yang, F., Chen, H., ... & Lu, Y. (2013). Apoptosis of bone marrow mesenchymal stem cells caused by homocysteine via activating JNK signal. *PLoS ONE*, 8(5), e63561. doi: 10.1371/journal.pone.0063561

- [4] Cheng, Z., Jiang, X., Fang, P., Kishore, R., & Kevil, C. (2015). Hyperhomocysteinemia Potentiated the Impairment of Hydrogen Sulfide-Induced Endothelium-Derived Hyperpolarization-Mediated Vascular Relaxation in Diabetic Db/db Mice. *Circ. Res.*, 117(1), 272-276. doi: 10.1161/res.117.suppl_1.272
- [5] Deep, S. N., Mitra, S., Rajagopal, S., Paul, S., & Poddar, R. (2019). GluN2A-NMDA receptor-mediated sustained Ca²⁺ influx leads to homocysteine-induced neuronal cell death. *J. Biol. Chem.*, 294(29), 11154-11165. doi: 10.1074/jbc.RA119.008820
- [6] Deng, J., L, S., Liu, H., Liu, B., Jiang, C., Xu, Q., ... & Wang, X. (2017). Homocysteine Activates B Cells via Regulating PKM2-Dependent Metabolic Reprogramming. *J. Immunol.*, 198(1), 170-183. doi: 10.4049/jimmunol.1600613
- [7] Dobrelia, N. V., Voitsova, L. V. & Danova, I. V. (2015). Правова база для проведення етичної експертизи доклінічних досліджень лікарських засобів з використанням лабораторних тварин [Legal basis for ethical examination of preclinical studies of drugs using laboratory animals]. *Фармакологія та лікарська токсикологія - Pharmacology and drug toxicology*, (2), 95-100.
- [8] Feng, J., Lu, S., Ding, Y., Zheng, M., & Wang, X. (2016). Homocysteine activates T cells by enhancing endoplasmic reticulum-mitochondria coupling and increasing mitochondria respiration. *Protein Cell*, 7(6), 391-402. doi: 10.1007/s12328-016-0245-x
- [9] Gao, X., Li, J., & Chen, M. (2018). Effect of Homocysteine on the Differentiation of CD4+ T Cells into Th17 Cells. *Dig. Dis. Sci.*, 63(12), 3339-3347. doi: 10.1007/s10620-018-5177-2
- [10] Horalskyi, L. P., Khomych, V. T., & Kononskyi, O. I. (2011). Основи гістологічної техніки і морфофункціональні методи досліджень у нормі та при патології [Fundamentals of histological technique and morphofunctional research methods in normal and pathology]. Житомир, Полісся - Zhytomyr: Polissya.
- [11] Jakubowski, H. (2019). Homocysteine Modification in Protein Structure / Function and Human Disease. *Physiol. Rev.*, 99(1), 555-604. doi: 10.1152/physrev.00003.2018
- [12] Kim, J., Kim, H., Roh, H., & Kwon, Y. (2018). Causes of hyperhomocysteinemia and its pathological significance. *Arch. Pharm. Res.*, 41(4), 372-383. doi: 10.1007/s12272-018-1016-4
- [13] Li, T., Chen, Y., Li, J., Yang, X., Zhang, H., Qin, X., ... & Mo, Z. (2015). Serum Homocysteine Concentration Is Significantly Associated with Inflammatory/Immune Factors. *PLoS One*, 10(9): e0138099. doi: 10.1371/journal.pone.0138099
- [14] Lu, S., Deng, J., Liu, H., Liu, B., Yang, J., Miao, Y., ... & Feng, J. (2018). PKM2-dependent metabolic reprogramming in CD4+ T cells is crucial for hyperhomocysteinemia-accelerated atherosclerosis. *J. Mol. Med. (Berl)*, 96(6), 585-600. doi: 10.1007/s00109-018-1645-6
- [15] McCully, K. S. (2019). Chemical Pathology of Homocysteine VII. Cholesterol, Thioretinaco Ozonide, Mitochondrial Dysfunction, and Prevention of Mortality. *Ann. Clin. Lab. Sci.*, 49(4), 425-438. PMID: 31471331
- [16] Pentyuk, O. O., Lutsyuk, M. B., Andrushko, I. I., & Postovitenko, K. P. (2003). Метаболізм гомоцистеїну та його роль у патології [Homocysteine metabolism and its role in pathology]. *Український біохімічний журнал - The Ukrainian Biochemical Journal*, 1, 5-17.
- [17] Pentyuk, O. O., Lutsyuk, M. B., Postovitenko, K. P., Artemchuk, M. A., Asachova, O. S., & Pryzymirska, T. V. (2004). Гіпергомоцистеїнемія: моделювання та вплив на стан судинної системи в експерименті [Hyperhomocysteinemia: experimental modeling and influence on vascular system state]. *Досягнення біології та медицини - Achievements of Biology and Medicine*, 1(3), 35-38.
- [18] Perez-Miguelsauz, J., Vallecillo, N., Carrido, F., Reytor, E., Perez-Sala, D., & Pajares, M. A. (2017). Betaine homocysteine S-methyltransferase emerges as a new player of the nuclear methionine cycle. *Biochim. Biophys. Acta Mol. Cell Res.*, 1864(7), 1165-1182. doi: 10.1016/j.bbamcr.2017.03.004
- [19] Pizzolo, F., Blom, H. J., Choi, S. W., Girelli, D., Guarini, P., Martinelli, N., ... & Friso, S. (2011). Folic acid effects on s-adenosylmethionine, s-adenosylhomocysteine, and DNA methylation in patients with intermediate hyperhomocysteinemia. *J. Am. Coll. Nutr.*, 30(1), 11-18. doi: 10.1080/07315724.2011.10719939
- [20] Poddar, R., Chen, A., Winter, L., Rajagopal, S., & Paul, S. (2017). Role of AMPA receptors in homocysteine-NMDA receptor-induced crosstalk between ERK and p38 MAPK. *J. Neurochem*, 142(4), 560-573. doi: 10.1111/jnc.14078
- [21] Raksha, N., Halenova, T., Vovk, T., Kharchenko, O., Savchuk, O., Samborska, I., ... & Maievskiy, O. (2021). Protein-peptide composition in the lungs of rats with hyperhomocysteinemia. *J. of Biological Research*, 94(2), 9858. doi: 10.4081/jbr.2021.9858
- [22] Sakowicz-Burkiewicz, M., & Pawelczyk, T. (2014). Recent advances in understanding the relationship between adenosine metabolism and the function of T and B lymphocytes in diabetes. *J. Physiol. Pharmacol.*, 62(5), 505-512. PMID: 22204797
- [23] Samborska, I. A. (2020). Changes in the histostructure of the lungs of old rats under conditions of persistent hyperhomocysteinemia. *Biomedical and Biosocial Anthropology*, 41, 41-45. doi: 10.31393/bba41-2020-07
- [24] Samborska, I., Kovalchuk, O., Fagoonee, S., Falalyeyeva, T., & Maievskiy, O. (2020). The Role of Hyperhomocysteinemia in the Development of Changes in the Lungs. *Reviews on Recent Clinical Trials*, 15(1), 48-59. doi: 10.2174/1574887114666191114152235
- [25] Silla, Y., Varshney, S., Ray, A., Basak, T., Zinelly, A., Sabaresh, V., ... & Sengupta, S. (2019). Hydrolysis of homocysteine thiolactone results in the formation of protein-cys-S-S-homocysteinylation. *Proteins*, 87(8), 625-634. doi: 10.1002/prot.25681
- [26] Skovierova, H., Vidomanova, E., Mahmood, S., Sopkova, J., Drgova, A., Cervenova, T., ... & Lehotsky, J. (2016). The molecular and cellular effect of homocysteine metabolism imbalance on human health. *Int. J. Mol. Sci.*, 17(10), 1733. doi: 10.3390/ijms17101733
- [27] Sorensen, J. T., Gaustadnes, M., Stabler, S. P., Allen, R. H., Mudd, S. H., & Hvas, A. M. (2016). Molecular and biochemical investigations of patients with intermediate or severe hyperhomocysteinemia. *Mol. Genet. Metab.*, 117(3), 344-350. doi: 10.1016/j.ymgme.2015.12.010
- [28] Tripathi, M., Zhang, C. W., Singh, B. K., Sinha, R. A., Moe, K. T., DeSilva, D. F., ... & Yen, P. M. (2016). Hyperhomocysteinemia causes ER stress and impaired autophagy that is reversed by vitamin B supplementation. *Cell Death and Disease*, 7(12), 1-14. doi: 10.1038/cddis.2016.374
- [29] Wang, H., Sun, Q., Zhou, Y., Zhang, H., Luo, C., Xu, J., ... & Wang, W. (2017). Nitration-mediated deficiency of cystathione β-synthase activity accelerates the progression of hyperhomocysteinemia. *Free Radical Biology and Medicine*, 113, 519-529. doi: 10.1016/j.freeradbiomed.2017.10.389

- [30] Wang, N., Tang, H., Wang, X., Wang, W., & Feng, J. (2017). Homocysteine upregulates interleukin-17A expression via NSun2-mediated RNA methylation in T lymphocytes. *Biochem. Biophys. Res. Commun.*, 493(1), 94-99. doi: 10.1016/j.bbrc.2017.09.069
- [31] Yang, A., Jiao, Y., Yang, S., Deng, M., Yang, X., Mao, C., ... & Jiang, Y. (2018). Homocysteine activates autophagy by inhibition of CFTR expression via interaction between DNA methylation and H3K27me3 in mouse liver. *Cell Death and Disease*, 9(2), 169. doi: 10.1038/s41419-017-0216-z
- [32] Zaric, B. L., Obradovic, M., Bajic, V., Haidara, M. A., Jovanovic, M., & Isenovic, E. R. (2019). Homocysteine and Hyperhomocysteinemia. *Curr. Med. Chem.*, 29(16), 2948-2961. doi: 10.2174/0929867325666180313105949
- [33] Zhang, D., Fang, P., Jiang, X., Nelson, J., Moore, J. K., Kruger, W. D., ... & Wang, H. (2012). Severe hyperhomocysteinemia promotes bone marrow-derived and resident inflammatory monocyte differentiation and atherosclerosis in LDLr/CBS-deficient mice. *Circ. Res.*, 111(1), 37-49. doi: 10.1161/CIRCRESAHA.112.269472
- [34] Zhang, J., Liu, T. T., Zhang, W., Li, Y., Niu, X. Y., Fang, Y. L., ... & Li, C. X. (2016). Hyperhomocysteinemia Is Associated with Vitamin B12 Deficiency: A Cross-Sectional Study in a Rural, Elderly Population of Shanxi China. *J. Nutr. Health Aging*, 20(6), 594-601. doi: 10.1007/s12603-015-0650-5
- [35] Zhang, Q., Li, Q., Chen, Y., Huang, X., Yang, I. H., Cao, L., ... & Tan, H. (2012). Homocysteine-impaired angiogenesis is associated with VEGF/VEGFR inhibition. *Front Biosci.*, 4(7), 2525-2535. doi: 10.2741/e563

ВПЛИВ ХРОНІЧНОЇ ГІПЕРГОМОЦИСТЕЇНЕМІЇ НА СТРУКТУРУ ТА ІМУННІ ПРОЦЕСИ СЕЛЕЗІНКИ МОЛОДИХ ЩУРІВ

Дзевульська І. В., Гриценко А. С., Тимошенко І. О., Закалата Т. Р., Лавриненко В. Є., Смолко Д. Г., Гунас І. В.

Гомоцистеїн - сірковмісна амінокислота, що є проміжним продуктом обміну метіоніну. Потрапляючи до організму з продуктами тваринного походження, метіонін піддається низці біохімічних перетворень. Гіпергомоцистеїнемія чинить негативний вплив на організм, зумовлюючи ураження всіх органів та систем і призводить до порушення гомеостазу. Метою дослідження є вивчення особливостей змін структури та імунних процесів селезінки молодих щурів при хронічній гіпергомоцистеїнемії. Досліди виконано на 22 білих щурах-самцях. Під час експерименту тварин розподілили на контрольну і дослідну групи (по 11 особин в кожній групі). Хронічну гіпергомоцистеїнемію досягали введенням D,L-тіолактон гомоцистеїну гідрохлориду тваринам дослідної групи в дозі 200 мг/кг маси тіла внутрішньошлунково на 1 % розчині крохмального гелю 1 раз на добу впродовж 8 тижнів. Після закінчення термінів експериментального моделювання хронічної гіпергомоцистеїнемії, тварин виводили з експерименту, знеживлюючи методом декапітації та використанням тіопенталового наркозу. Гістологічні препарати вивчали за допомогою світлового мікроскопа SEO SCAN. Експериментальне моделювання хронічної гіпергомоцистеїнемії у молодих щурів не супроводжувалось відчутними морфологічними зрушеннями стромы та червоної пульпи селезінки. Т-клітинні периартеріальні піхви і В-клітинні вузлики у тварин з експериментальної групи зазнавали змін. Проліферація В-клітин призводить до розростань в межах білої пульпи, розширення маргінальних зон, що стають більш розмитими, та інфільтрації цих клітин у червону пульпу. Оцінка стану червоної пульпи у селезінці молодих щурів експериментальної групи показала певне розширення у венозних синусах, що може бути ознакою реакції на вплив гомоцистеїну і незначного набрякання цих судин. Чисельність Т-клітин у молодих тварин в периартеріальних муфтах дещо знижується, що можна пояснити зростаючою активністю макрофагів. Тим не менш, Т-клітини також інфільтрували у червону пульпу. Подібне проникнення білих клітин крові у червону пульпу супроводжується розширенням і "розмиванням" маргінальних зон лімфатичних вузликів. Таким чином, підвищений рівень гомоцистеїну значно потенціював проліферацію і частково інгібував апоптоз у Т-лімфоцитах, але не мав прямого впливу на сплячі Т-клітини.

Ключові слова: гомоцистеїн, селезінка, лімфоцити, макрофаги, щури.

Author's contribution

Dzevulska I. V. - conceptualization, review writing and editing.

Gritsenko A. S. - research, methodology and writing of the original draft, formal analysis and validation.

Tymoshenko I. O. - software, resources.

Zakalata T. R. - review writing and editing.

Lavrinenko V. Y. - project administration.

Smolko D. G. - software, resources.

Gunas I. V. - conceptualization.