




## REPORTS OF MORPHOLOGY

Official Journal of the Scientific Society of Anatomists,  
Histologists, Embryologists and Topographic Anatomists  
of Ukraine

journal homepage: <https://morphology-journal.com>



# Pathomorphological features of confirmed bronchogenic cyst with atypical localization

Khoroshun E. M.<sup>1</sup>, Nehoduiko V. V.<sup>1</sup>, Vorovskyi O. O.<sup>2</sup>, Makarov V. V.<sup>3</sup>, Bunin Yu. V.<sup>1</sup>, Smolyannik K. M.<sup>3</sup>

<sup>1</sup>Military Medical Clinical Center of the Northern Region of the Command of the Medical Forces of the Armed Forces of Ukraine, Kharkiv, Ukraine

<sup>2</sup>National Pirogov Memorial Medical University, Vinnytsya

<sup>3</sup>Kharkiv National Medical University, Kharkiv, Ukraine

### ARTICLE INFO

Received: 07 February 2024

Accepted: 03 April 2024

UDC: 616.233:575.113.1:618.11-006.2-089:616-073.75:611.018

### CORRESPONDING AUTHOR

e-mail: vorovskisurgery@ukr.net  
Vorovskyi O. O.

### CONFLICT OF INTEREST

The authors have no conflicts of interest to declare.

### FUNDING

Not applicable.

### DATA SHARING

Data are available upon reasonable request to corresponding author.

*Among all formations of the mediastinum in the adult population, cysts make up about 20 %, of which more than 60 % are bronchogenic cysts, where up to 50% have an asymptomatic course, and therefore in most cases are detected accidentally. Regardless of the course and origin, cysts are subject to complete surgical removal. In connection with the clinical and radiological polymorphism of bronchogenic cysts, histological confirmation of the origin of the cysts does not lose its relevance. The purpose of the work is to study and highlight the pathomorphological characteristics of a cyst localized in the pericardium. Using video-assisted thoracic surgery (VATS) and thoracotomy approaches, 16 people aged 28 to 62 with cystic lesions of the mediastinum were operated on. The patients underwent radiographic examination, computed tomography with intravenous contrast injection and, in 2 cases, magnetic resonance imaging. Ultrasound examination was performed on 6 patients in whom cystic lesions were a diagnostic finding. The location of the cyst, maximum diameter, density, and calcification were evaluated. Clinically and radiologically, asymptomatic pericardial (coelomic) cysts were detected in 2 persons in the prevascular department. In the visceral part of the mediastinum, 3 patients had a pericardial cyst, 10 patients were diagnosed with 10 bronchial cysts with parenchymal and perihilar localization, among which one patient was diagnosed with an asymptomatic bronchial cyst with an atypical localization in the pericardium. In the paravertebral part of the mediastinum, 1 paraesophageal cyst was established, which was intimately connected with the lower third of the thoracic part of the esophagus. All types of cysts were histologically confirmed. Statistical processing of the obtained results was carried out using the Excel program. After a clinical examination of a patient with a pericardial cyst of the visceral mediastinum, right VATS surgery and removal of the cyst was performed. Histological examination of fragments of the cyst wall showed the presence of multi-rowed ciliated cylindrical epithelium, pronounced infiltration by lymphoid elements with hemorrhages and foci of fibrotization in separate areas. The histological structure of the removed pericardial cyst confirmed its bronchogenic origin. So, we discovered a rare form of abnormality of embryonic growth of the ventral part of the foregut with localization of a bronchogenic cyst in the anterior-inferior mediastinum on the right, which significantly expanded the understanding of the disease.*

**Keywords:** bronchogenic cyst, radiography, video-assisted thoracic surgery, histology.

### Introduction

The mediastinum is a rather complex anatomical space, where accurate diagnosis of the localization of any lesion remains quite problematic today, which cannot but affect the results of treatment. Previous anatomical classifications of the mediastinum and their definitions do not always coincide with the conclusions of modern

instrumental diagnostic methods. Therefore, on the basis of cross-sectional imaging of the mediastinum, the International Thymic Malignancy Interest Group (ITMIG) developed and adopted a new clinical classification that divides the mediastinum into three sections: prevascular (anterior), visceral (middle) and paravertebral (posterior)

sections [1, 27].

The frequency of detection of cysts in the adult population is about 20 % of the total number of detected neoplasms of the mediastinum. Often they arise as a result of disorders of embryonic development. And depending on the morphological component, the following types of cysts are distinguished:

1) bronchial cysts - capsular one-chamber formations, which are filled with liquid content and are most often located in the visceral (middle) and paravertebral parts of the mediastinum;

2) cysts of the digestive tract - capsular one- and two-chamber, oval, can connect with the esophagus [3], forming a fistula; usually located in the paravertebral section of the mediastinum;

3) pericardial cysts - thin-walled oval or pear-shaped formations connected by a stalk to the pericardial cavity. They are located mainly in the right phrenic-cardiac angle (as a coelomic cyst). It is believed that a third of mediastinal cysts are pericardial cysts. They are usually asymptomatic and appear accidentally, most often in people aged 40-50 [2].

Cysts are divided into congenital cysts, including bronchogenic cysts, esophageal cysts, gastrointestinal cysts, coelomic cysts (pericardial and mesothelial), thymic cysts, and acquired cysts, which are less common and are represented mainly by thoracic duct cysts and lymphangiomas. Bronchogenic cysts are congenital cystic malformations of the respiratory tract that arise as a result of abnormal budding of the bronchial tree during embryogenesis and account for 50-60 % of the total number of mediastinal cysts. It should be noted that bronchogenic cysts are quite rare, their frequency is 1 case per 42,000-68,000 [9, 19]. They can be diagnosed at any age, but are more often reported in young people and adolescents than in adults [17, 23].

In most patients, the presence of cysts is asymptomatic, sometimes symptoms associated with compression of mediastinal structures appear. Cysts are single-chambered and, rarely, multi-chambered. Typically, the cyst wall is a thin fibrous capsule with few smooth muscle cells, which is lined by secretory respiratory epithelium (columnar or cuboidal ciliated epithelium) and may contain cartilage, glandular tissue, and smooth muscle fibers. This epithelium can be metaplastic [23]. Bronchogenic cysts are characterized by a parenchymal (intrapulmonary) or perihilar location. However, rare localizations were observed, including the neck [23], pericardium [8], esophagus [5].

Less than 6 % of all neoplasms of the mediastinum are pericardial cysts [6], which can be detected accidentally during radiography, sometimes they can disappear spontaneously [18]. A pericardial cyst develops as a result of violations of the embryogenesis of the pericardial leaves and the impossibility of fusion of the mesenchymal lacuna, which forms the pericardial sac.

This leads to metamorphosis in the cyst wall, consisting of a thin layer of fibrous tissue lined by a single layer of mesothelial cells. Most pericardial cysts are found in the right anterior costo-diaphragmatic angle (70 %), but it can be located in any part of the mediastinum near the heart. The incidence is reported to be 1:100,000 patients, although this is probably an underestimate, as more than 50 % remain clinically "silent" and are usually discovered incidentally. Pericardial cysts are usually less than 5.0 cm in diameter. Differential diagnosis should be carried out with any bronchogenic neoplasm, pericardial lipoma, thymoma, mediastinal teratoma, Morgani hernia, cyst-duplication of the gastrointestinal tract, cystic sequestration of the lungs, mesothelium-lined cyst, post-traumatic cyst and hydatid cyst, and other cystic formations of the mediastinum [6, 22, 26].

Taking into account the fact that mediastinal formations in most cases have an asymptomatic course, they are most often detected accidentally, during a chest X-ray, which must be performed in two projections.

A mediastinal cyst can be diagnosed accidentally during echocardiography of intracardiac hemodynamic disorders. Computed tomography is a method with which it is often possible to predetermine the nature of the lesion. Single cases of malignancy of bronchogenic cysts are described in the scientific literature. J. Whooley et al. [29] first reported a squamous cell carcinoma arising in the paratracheal region from a bronchogenic cyst. Computed tomography provides the fastest results regarding the presence of signs of malignancy. Cysts have low density, thin (imperceptible) walls, little or no septa, and no contrast enhancement. Cystic lesions (proteinaceous, infected, or hemorrhagic) may be misinterpreted as solid due to tissue areas or blood clots. Dual-energy computed tomography with intravenous contrast can help distinguish cystic from solid lesions using digital iodine subtraction techniques (intravenous contrast). This allows differentiation of tissue enhancement from hemorrhagic/proteinaceous fluid, as well as differentiation of calcium due to different intensity of contrast accumulation [24].

For the diagnosis of hypermetabolic lesions of cysts, a number of scientists promote the use of a fairly modern study, such as fluorodeoxyglucose-positron emission tomography/computed tomography (FDG-PET/CT) with individualized radioactive indicators, which can be used in each specific case for the diagnosis of metastatic lesions. neuroendocrine lesions and other suspected malignant neoplasms [24].

Magnetic resonance imaging can be used as a means of solving problems, especially when it is difficult to distinguish cystic from solid lesions on a computer tomography and characterize complex cystic lesions, more clearly determine the presence of infiltrative disease [24].

Most authors consider operative removal of cysts of any type as the "gold standard" instead of a therapeutic approach, according to their observations of patients with

cystic lesions who underwent radical surgery, had excellent results [26].

As for the approach to the choice of the method and accesses of surgical intervention, at the current stage we are observing a transition from highly traumatic thoracotomy (anterolateral or lateral) to minimally invasive surgery (MIS). The possibilities of MIS application are directly related to the progress of development of medical technology and corresponding surgical instruments. MIS became possible with the introduction of video-assisted thoracic surgery (VATS) [4] or robotic assisted thoracic surgery (RATS), and the development of endoscopic instruments expanded the indications for the use of MIS and became the "gold" standard. In particular, RATS not only improved the quality of life of patients, but also the ergonomic indicators of the professional activity of doctors [9, 12].

*The purpose of the work* is to study and highlight the pathomorphological characteristics of a cyst localized in the pericardium.

### Materials and methods

During the period January 2010 - December 2023, 16 (100 %) people aged 28 to 62 with cystic lesions of the mediastinum were diagnosed and treated in the conditions of the Military Medical Clinical Center of the Northern Region of the Command of the Medical Forces of the Armed Forces of Ukraine. The average age of the patients was  $42.5 \pm 0.5$  years. There were 12 (75.0 %) men, 4 (25.0 %) women. There was no significant difference in the average age between men and women ( $p > 0.5$ ).

All patients were informed about the nature of the study and signed an informed consent for the diagnostic examination and the type of surgical intervention using personal data. The patient could refuse to participate in the study or stop participating at any time. The research was conducted confidentially, only the patients were informed about their results. In scientific publications, only generalized data without personalized information were presented. Only the operator had access to the information. No harm was caused to the patients from the conducted research. The study was approved by the ethics committee of the Military Medical Clinical Center of the Northern Region of the Command of the Medical Forces (Protocol No. 1 dated January 26, 2024).

In 10 (62.5 %) patients, the clinical course was asymptomatic, and the mediastinal cyst was detected during the examination of the chest X-ray. Other 6 patients (37.5 %) had specific symptoms. The location and type of mediastinal cysts were determined with the help of appropriate instrumental diagnostic methods. The diameter of the cysts was  $4.0 \pm 1.0$  cm on average. The average size of bronchogenic cysts was  $4.5 \pm 0.5$  cm, and  $3.7 \pm 0.5$  cm in pericardial cysts.

Thus, in the *prevascular* department, clinical and radiological signs indicated the presence of asymptomatic

pericardial (coelomic) cysts in 2 persons (12.5 %), the sizes of which in diameter were 3.5 cm and 4.5 cm. Cysts of the thymus gland were not detected during the study.

In the *visceral* part of the mediastinum, 3 patients (18.75 %) had a pericardial cyst, of which 2 (12.5 %) asymptomatic cysts were located in the left cardiophrenic angle, and 1 (6.25 %) - above the left ventricle with signs of clinical compression. Also, in the visceral part of the mediastinum, 10 patients (62.5 %) had 10 (62.5 %) bronchial cysts with a diameter of 4.0 to 6.5 cm, of which in 4 patients (25.0 %) they were localized intrapulmonary (parenchymal), 5 (31.25 %) - perihilar, and in 1 patient (6.25 %) was diagnosed with an asymptomatic bronchial cyst with atypical localization in the pericardium.

In the *paravertebral* part of the mediastinum, 1 (6.25 %) paraesophageal cyst with a diameter of 4.4 cm was found, which was intimately connected to the lower third of the thoracic part of the esophagus.

In all patients (100 %), according to the examination protocol, in order to clarify the type of vascularization of the formation, radiography of the chest organs was combined with computer tomography with intravenous injection of contrast. Ultrasound examination was performed in 6 (37.5 %) patients, where cystic lesions were a diagnostic finding. FDG-PET/CT was not used in these studies.

Magnetic resonance imaging was used in 2 (12.5 %) patients with a bronchial cyst with perihilar localization and 1 (6.25 %) with a paraesophageal cyst in order to rule out an infiltrative process. With the help of the above studies, it was established that there was no significant difference in size between the types of cysts.

In 10 (62.5 %) cases, the contents of the cyst were mucoid, in 5 (31.25 %) - serous, and in 1 (6.25 %) - blood clots. Membranes were present in 2 (12.50 %) cysts, and cartilage (bronchogenic cysts) in 1 (6.25 %).

"Open" surgical approaches included lateral thoracotomy in 5 (31.25%) cases. VATS was performed in 11 (68.75 %) cases.

In one case, an *atypical location of a bronchial cyst was established (Report of an atypical case)*. The sick serviceman Ye., 38 years old, was hospitalized in the surgical department of the surgical clinic of the Military Medical Clinical Center of the Northern Region of the Command of the Medical Forces due to a pericardial cyst for further examination and operative treatment. Clinically and laboratory examined. Survey radiography of the chest organs was performed with the help of the radiographic diagnostic KRD-50 complex "INDIASCOP-01" (Ukraine). Multispiral computed tomography (MSCT) of the chest organs was performed on the "Revolution EVO" machine with a tomograph step of 0.5 mm. Surgery performed: VATS on the right, revision, cyst removal of the visceral mediastinum, sanitation and drainage of the right pleural cavity according to Bülow under general anesthesia with one-lung intubation (left) and artificial lung ventilation.

Video thoracoscopy was performed on the OLYMPUS VISERA 4K UHD OTV-S400, 2021 video endoscopic stand. Pericardial cyst tissue fragments were taken for histological examination, for which the excised samples were fixed in 40 % neutral formalin and embedded in paraffin according to generally accepted methods [11]. After paraffin fixation, sections with a thickness of 5-6  $\mu\text{m}$  were made, which were stained with hematoxylin and eosin. Complex pathomorphological studies were performed on a Primo Star microscope (Carl Zeiss) with a magnification of x280. An AxioCam (ERc 5s) high-resolution 8-bit digitizing digital camera with a pixel size of 2.2  $\mu\text{m}$  and Carl Zeiss AxioCam (ERc5s) Configuration Tool software were used for image documentation. In the postoperative period, before and after the removal of pleural drainage, control X-rays of the chest organs were performed. The lungs were expanded, fluid and air in the pleural cavity on the right were not determined.

Statistical processing of the obtained results was carried out using the Excel program (Microsoft Office, USA).

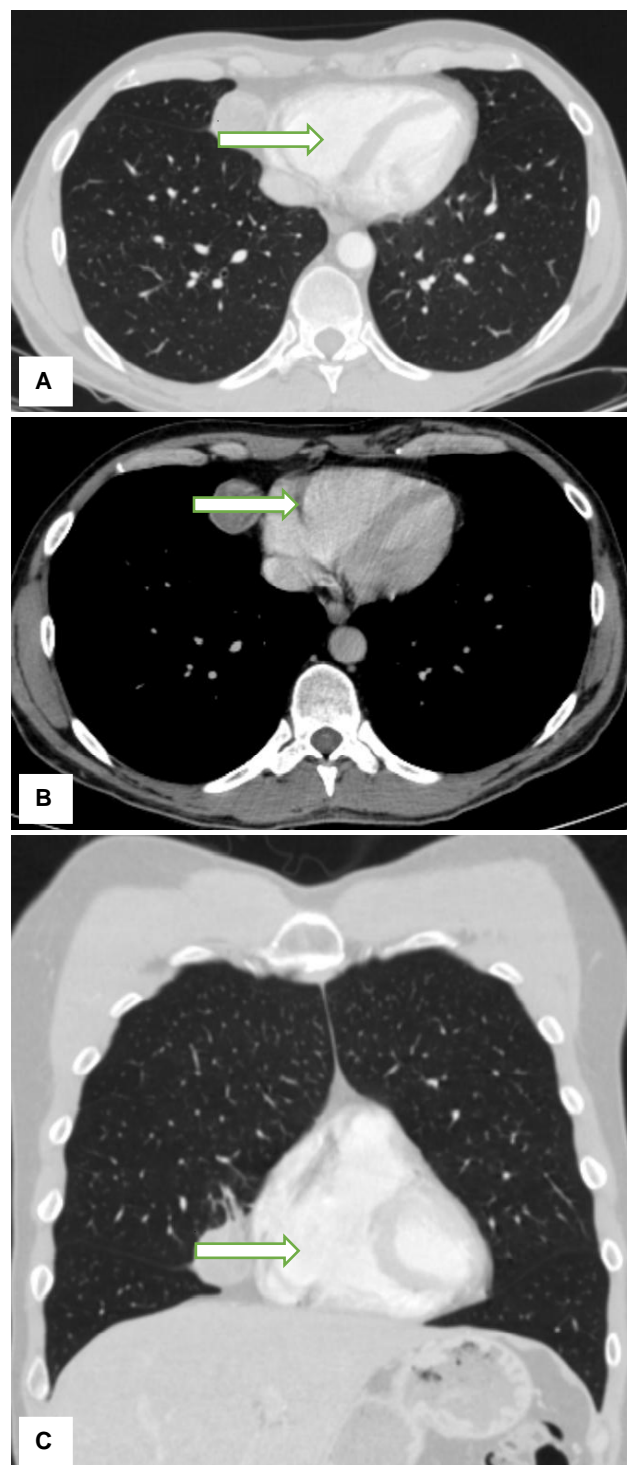
### Results

All 16 patients underwent surgical removal of the cyst. In 14 (87.5 %) cases, complete removal of the cyst was performed, and in 2 (12.5 %) cases - partial removal (due to intimate fusion with the aorta).

All types of cysts were histologically confirmed. Bronchogenic cysts were characterized by a cystic wall with a mucous membrane, which was lined with respiratory epithelium, where metaplastic dysplasia was observed in 4 (25.0 %) cases, the presence of bronchial glands was established, and in 1 (6.25 %) case - 2 areas of cartilage. The paraesophageal cyst was characterized by the presence of a mucous membrane lined with ciliated columnar epithelium characteristic of the gastrointestinal tract, with areas of nonkeratinizing squamous epithelium and the presence of a smooth muscle layer with moderate degenerative changes.

Patient E., 38 years old, underwent a multispiral computed tomography of the chest organs (Fig. 1). During the examination, a neoplasm of a rounded shape, size 33.00 x 30.00 mm, of inhomogeneous structure with a liquid component and clear contours, without signs of invasion into adjacent anatomical structures, was found in the area of the anterior mediastinum on the right.

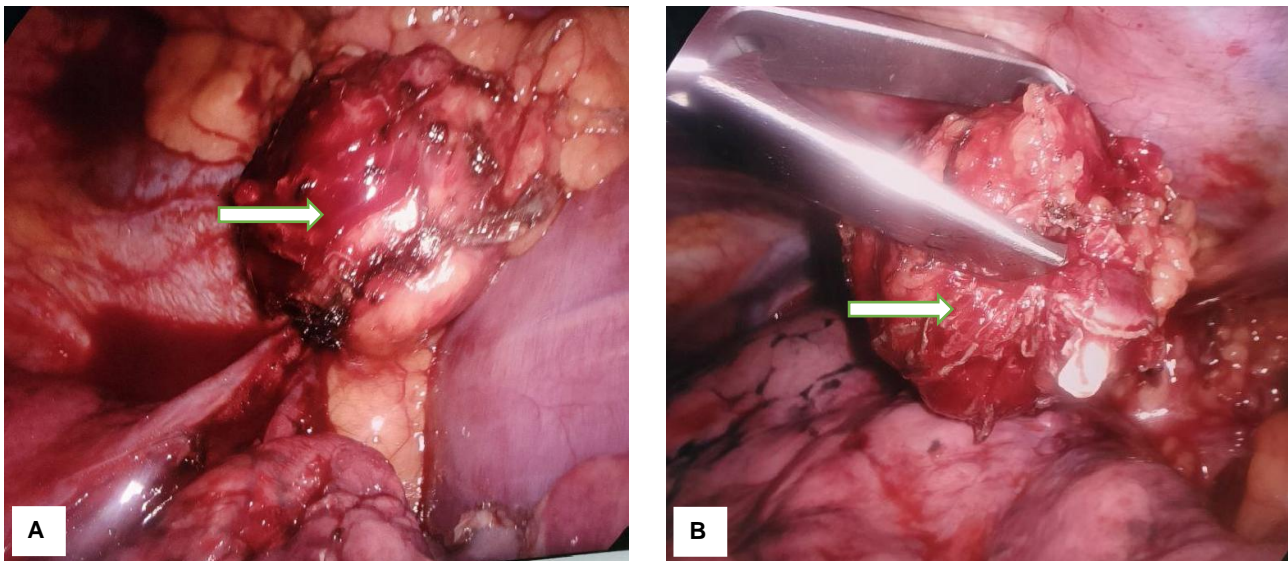
During the operation, a revision of the thoracic cavity was carried out and in the projection of the anterior-inferior mediastinum on the right, the presence of interpleural adhesions and a rounded neoplasm measuring 33.00 x 30.00 mm, which was dense and limited in mobility, was established. With the help of the Covidien LigaSure Maryland device, the neoplasm was gradually isolated from the surrounding tissues and removed from the pleural cavity. Figure 2 shows the thoracoscopic visualization of the cyst and the stage of separation of the cyst after cutting it off from the pericardium.



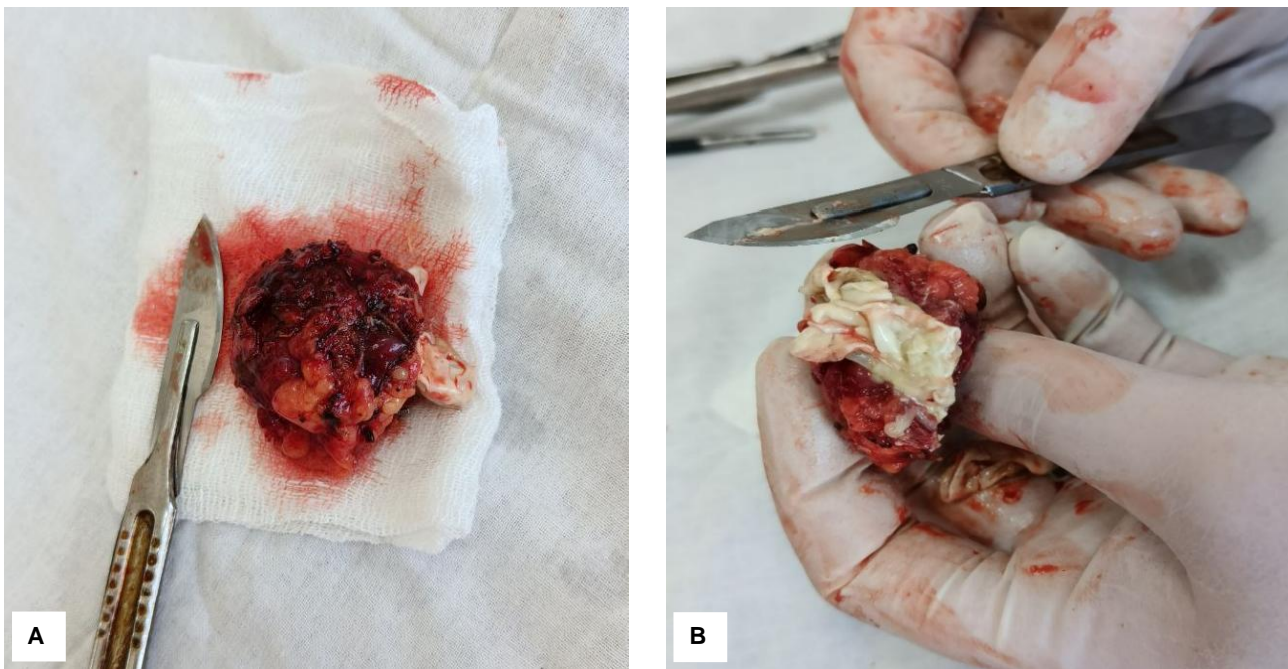
**Fig. 1.** Primary computer tomography of patient E., 38 years old. Right anterior mediastinum. A rounded neoplasm with clear contours without signs of invasion into adjacent anatomical structures (white arrows). A, B - axial projection; C - coronal projection.

The external macroscopic view of the pericardial cyst after removal from the pleural cavity is presented in Figure 3.

When the cyst was opened, up to 8 ml of cloudy liquid



**Fig. 2.** A - thoracoscopic visualization of a pericardial cyst (white arrow); B - cyst removal (white arrow) after cutting from the pericardium.



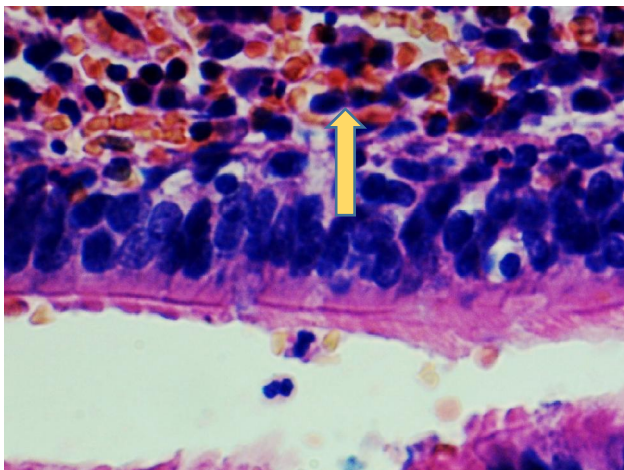
**Fig. 3.** Macropreparation. A - removed cyst. Macropreparation. B - cyst on autopsy.

was removed, the inner layer of the cyst was white. The cyst was soft to the touch.

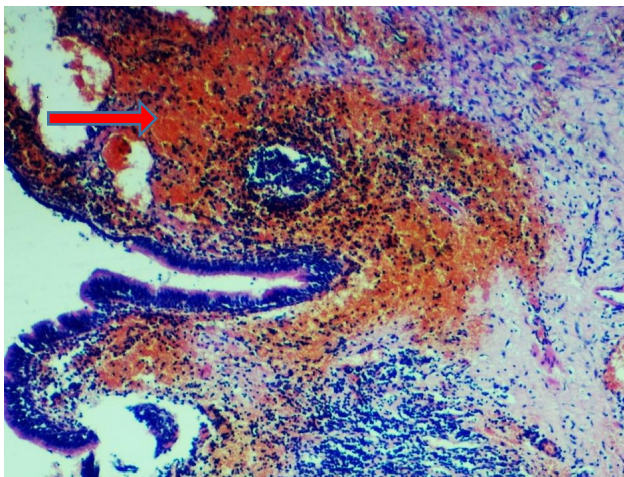
The microscopic structure of the removed cyst is shown in Figures 4 and 5. The wall of the cyst was lined with multi-row ciliated cylindrical epithelium, marked infiltration by lymphoid elements with multiple hemorrhages was observed. In some areas, dilated venous vessels with foci of fibrotization were visualized. The histological structure of the removed pericardial cyst confirmed by us its bronchogenic origin.

The microscopic picture of the cyst is characterized by one or several tissues that are characteristic of the trachea

or bronchi. Characteristically, they are lined, usually, with ciliated, multi-layered columnar epithelium, which was determined during histological examination. In the absence of ciliated epithelium, squamous cell metaplasia may occur, which should always be emphasized and the drugs should be examined histologically. The patient's absence in the anamnesis of lung disease and accompanying parenchymal and bronchial inflammation, together with the histological examination, confirmed the presence of a bronchogenic cyst with a localization that is not characteristic of bronchogenic cysts.



**Fig. 4.** Section of the pericardial bronchogenic cyst wall. Multi-row ciliated cylindrical epithelium (black arrow). Lymphoid elements with multiple hemorrhages in the wall (yellow arrow). Hematoxylin-eosin. x280.



**Fig. 5.** Section of the pericardial bronchogenic cyst wall. Areas of fibrotization (red arrow). Hematoxylin-eosin. x56.

## Discussion

Mediastinal cysts can be of pericardial, intestinal or bronchogenic origin [30].

Since the article deals with bronchogenic cysts, we note that this is a congenital formation that arises from the respiratory epithelium [20]. Bronchogenic cysts were first described in 1859 [9].

Bronchogenic cysts are rare congenital anomalies of the foregut, usually localized in the mediastinum and lungs [14]. It is during the formation of the tracheobronchial tree from the embryonic ventral foregut, which forms the respiratory system, that aberrant budding and branching leads to the formation of bronchogenic cysts [19, 25]. The location of the bronchogenic cyst depends on the embryological stage of development at which the anomaly occurs. If malformations of the respiratory tract occur in the early stages of pregnancy, then bronchogenic cysts are usually localized in the mediastinum, if in later stages, then

in the lungs [15]. Bronchogenic cysts can usually form in the 6th week of pregnancy from abnormal growth of a tracheal diverticulum. They are characterized by the presence of respiratory (ciliated) epithelium. Histologically, they also contain cartilage, fibrous tissue, smooth muscle and mucous glands. These cysts are located near the trachea or main stem bronchi. Sometimes you can find a connection of the cyst with the tracheobronchial tree.

There are three types of bronchogenic cysts: mediastinal, intrapulmonary, and ectopic, and the mediastinal type predominates [10, 13].

From the point of view of the localization of bronchogenic cysts, according to many studies, they can be found in any organ, but most of them are found in the chest, or in the parenchyma of the lungs, or in the mediastinum, in addition, they occur in the cervical, diaphragmatic paravertebral, scapular, pericardial, retroperitoneal, omentum, perianal regions and thymus [15, 19, 20, 28]. In a recent study, Liu X. et al. [16], which is devoted to the study of ectopic double primary bronchogenic cysts, describes the case of Xinlong, and provides important evidence for the further determination of the pathogenesis of bronchial cysts.

It should be noted that from the point of view of differential diagnosis, bronchogenic cysts are a problem, because they are characterized by clinical and radiological polymorphism, they can be confused with echinococcosis. Histological differential diagnosis includes: cystic teratoma, bronchopulmonary sequestration, esophageal cyst, chronic abscess [15].

Bronchogenic cysts are subject to complete surgical excision, and the final diagnosis is established with the help of histopathological examination of the surgical specimen [7]. Histologically, one can find elements of normal bronchial structures with respiratory-type epithelium (ciliated pseudo-multilayered columnar epithelial goblet-shaped cells, often filled with mucin) in the composition of cysts. The wall of the cyst usually consists of fibrous connective tissue, which has serous-mucous bronchial glands (but not always), hyaline cartilage, smooth muscles, elastic fibers [9].

Previously, only symptomatic cysts were subject to surgical removal, later indications were extended to asymptomatic cysts due to the 25 % frequency of their complications, such as infection, development of clinical symptoms, and increase in cyst size [9, 12, 21].

In our case, a 38-year-old man was hospitalized with a suspected pericardial cyst for further examination and operative treatment. With the help of multispiral computed tomography of the chest organs, a dense neoplasm of a rounded shape, 3.3 x 3.0 cm in size, of an inhomogeneous structure with a liquid component and clear contours, without signs of invasion into adjacent anatomical structures, was revealed in the area of the anterior-inferior mediastinum on the right. Note that 70 % of pericardial cysts are located precisely in the right cardiaphragmatic angle [12].

That is, the age, sex of the patient, localization, size of the cyst (<5.0 cm) tended to assess the identified cyst as

pericardial. However, the histological examination of the tumor removed during the operation revealed a cystic lesion, the wall of which is lined with multi-row cylindrical ciliated epithelium with foci of infiltration by lymphoid elements with multiple hemorrhages, foci of fibrotization, but without signs of cytological atypia, which made it possible to make the final diagnosis - bronchogenic cyst and avoid misdiagnosis.

## References

- [1] Ahuja, J., Strange, C. D., Agrawal, R., Erasmus, L. T., & Truong, M. T. (2023). Approach to Imaging of Mediastinal Masses. *Diagnostics*, 13(20), 3171. doi: 10.3390/diagnostics13203171
- [2] Barrios, P., & Patino, D. A. (2022). Surgical indications for mediastinal cysts - a narrative review. *Mediastim*, 6, 31. doi: 10.21037/med-22-27
- [3] Benfaddoul, O., Hajjine, A., Bellasri, S., Slioui, B., Roukhsi, R., Hammoune, N. ... & Atmane, E. (2022). Paraesophageal Cyst: A Case Report. *Journal of Clinical Case Studies Reviews & Reports J Clin Stud Rev Rep*, 4(3), 1-2. doi: 10.47363/JCCSR/2022(4)210
- [4] Bertolaccini, L., & Rocco, G. (2019). History and development of minimally invasive surgery: VATS surgery. *Shanghai Chest*, 3, 16. doi: 10.21037/shc.2019.03.01
- [5] Cenicerros-Cabrales, A. P., & Sánchez-Fernández, P. (2018). Esophageal bronchogenic cyst: an uncommon cause of dysphagia in adults. Case report and literature review. *Cirugia y Cirujanos*, 86(2), 187-190. doi: 10.24875/CIRUE.M18000027
- [6] Collins, K., L., Zakhariou, F., Mandal, A. K. J., & Missouri, C. G. (2018). Pericardial Cyst: Never Too Late to Diagnose. *Journal of Clinical Medicine*, 7(11), E399. doi: 10.3390/jcm7110399
- [7] Erbenová, A., Placrová, B., Špürková, Z., & Horák, P. (2021). Bronchogenic cyst of gastric cardia - case report and literature review. *Rozhl Chir*, 100(10), 507-511. doi: 10.33699/PIS.2021.100.10.507-511
- [8] Escalante, J. M., Molina, G., Rincón, F. M., Acosta Buitrago, L. M., & Perez Rivera, C. J. (2021). Giant intrapericardial bronchogenic cyst associated with congestive heart failure and atrial fibrillation: a case report. *Journal of Cardiothoracic Surgery*, 16, 1-5. doi: 10.1186/s13019-021-01412-2
- [9] Gross, D. J., Briski, L. M., Wherley, E. M., & Nguyen, D. M. (2023). Bronchogenic cysts: a narrative review. *Mediastinum*, 7, 26. doi: 10.21037/med-22-46
- [10] Gu, X., Zhu, L., Li, Y., Yin, B., & Wang, Z. (2023). Imaging Findings and Misdiagnosis of Bronchogenic Cysts: A Study of 83 Cases. *J Belg Soc Radiol*, 107(1), 81. doi: 10.5334/jbsr.3214
- [11] Gutzwiller, L. G., & Crouch, C. (2023). *Methodology for Formalin Fixed Paraffin Embedded Cardiac Tissue Analysis*. Haslam Scholars Projects. 6 p. [https://trace.tennessee.edu/utk\\_haslamschol/25](https://trace.tennessee.edu/utk_haslamschol/25)
- [12] Hsu, D. S., Banks, K. C., & Velotta, J. B. (2022). Surgical approaches to mediastinal cysts: clinical practice review. *Mediastinum*, (6), 32. doi: 10.21037/med-22-20
- [13] Lau, C. L., & Davis, R. D. (2004). *The mediastinum*. In: *Sabiston's Textbook of Surgery*. (17th.) (Ch. 56). (pp. 1738-1739). Philadelphia, Pa, USA: Elsevier.
- [14] Limaïem, F., Ayadi-Kaddour, A., Djilani, H., Kilani, T., & El Mezni, F. (2008). Pulmonary and mediastinal bronchogenic cysts: a clinicopathologic study of 33 cases. *Lung*, 186(1), 55-61. doi: 10.1007/s00408-007-9056-4
- [15] Limaïem, F., & Mlika, M. (2023). *Bronchogenic Cyst*. In: StatPearls [Internet]. Treasure Island (FL): StatPearls Publishing; 2024 Jan. Available from: <https://www.ncbi.nlm.nih.gov/books/NBK536973/>
- [16] Liu, X., Sun, T., Hong, T., & Zhang, H. (2023). Ectopic double primary bronchogenic cysts: a case description Xinlong. *Quant Imaging Med Surg*, 13(9), 6310-6316. doi: 10.21037/qims-23-247
- [17] Mlika, M., Abdennadher, M., Ayadi, R., Braham, E., Ismail, O., Marghli, A., & Mezni, F. (2022). Mediastinal cysts: a 52-case retrospective study. *La Tunisie Medicale*, 100(1), 44-48. PMID: 35822331
- [18] Moffa, A. P., Stoppino, L. P., Loizzi, D., & Milillo, P. (2018). Spontaneous disappearance of a pericardial cyst: case report and literature review. *Korean J Thorac Cardiovasc Surg*, 51, 72-75. doi: 10.5090/kjtcs.2018.51.1.72
- [19] Mir, Z. M., Wang, A., Winthrop, A., & Kolar M. (2018). Scapular Bronchogenic Cyst in a Girl Presenting as Recurrent Cellulitis: A Case Report and Review of the Literature. *Case Rep Pediatr*, 2018, 7463724. doi: 10.1155/2018/7463724
- [20] Núñez-Rocha, R. E., Perez, V., Urango, M. L., Mejia, M., Palau, M., & Herrera-Almarino, G. (2023). Extrapulmonary bronchogenic cyst: A case report. *Int J Surg Case Rep*, 110, 108706. doi: 10.1016/j.ijscr.2023.108706
- [21] Osman, N. I., Bratt, D. G., Downey, A. P., Esperto, F., Inman, R. D., & Chapple, C. R. (2021). A systematic review of surgical interventions for the treatment of bladder pain syndrome/interstitial cystitis. *European Urology Focus*, 7(4), 877-885. doi: 10.1016/j.euf.2020.02.014
- [22] Ramireddy, K., Golamari, R. R., Minupuri, A., Zheng, S., & Menetrey, J. (2020). Bronchogenic Cyst Presenting as Acute Pericarditis. *Cureus*, 12(6), e8874. doi: 10.7759/cureus.8874
- [23] Santos, I., Barros, J., Lopes, T., Mesquita, M., Barroso, L., & Amado, I. (2019). Bronchogenic cyst of the neck in an elder patient: a case report. *International Journal of Surgery Case Reports*, 64, 128-132. doi: 10.1016/j.ijscr.2019.10.013
- [24] Shah, A., & Rojas, C. A. (2023). Imaging modalities (MRI, CT, PET/CT), indications, differential diagnosis and imaging characteristics of cystic mediastinal masses: a review. *Mediastinum*, 7(25), 3. doi: 10.21037/med-22-31
- [25] Schittny, J. (2017). Development of the lung. *Cell and Tissue Research*, 367(3), 427-444. doi: 10.1007/s00441-016-2545-0
- [26] Szolkowska, M., Szczepulska-Wojcik, E., Maksymiuk, B., Burakowska, B., Winiarski, S., Gatarek, J., ... & Langfort, R. (2019). Primary mediastinal neoplasms: a report of 1,005 cases from a single institution. *Journal of Thoracic Disease*, 11(6), 2498. doi: 10.21037/jtd.2019.05.42
- [27] Tomiyama, N. (2019). Approach to the prevascular mass. *Mediastinum*, 3, 17. doi: 10.21037/med.2019.04.05
- [28] Ugurlucan, M., Sayin, O. A., Felten, M., Oztas, D. M., Cakir, M. S., Barburoglu, M., ... & Dayioglul, E. (2014). Intrapericardial Bronchogenic Cyst: An Unusual Clinical Entity. *Case Rep Med*,

## Conclusions

1. The successful experience of detecting a bronchogenic cyst in an atypical location, which is confirmed histologically, allows you to avoid a false diagnosis.
2. The obtained results make it possible to significantly improve the understanding of the pathomorphological picture of bronchogenic cysts.

651683. doi: 10.1155/2014/651683

[29] Whooley, J., White, A., & Soo, A. (2022). Bronchogenic cyst: a rare case of malignant transformation. *BMJ Case Rep*, 15(4), e248916. doi: 10.1136/bcr-2022-248916

[30] Wychulis, A. R., Payne, W. S., Clagett, O. T., & Woolner, L. B. (1971). Surgical treatment of mediastinal tumors: a 40 year experience. *Journal of Thoracic and Cardiovascular Surgery*, 62(3), 379-392. doi: 10.1016/S0022-5223(19)42048-5

---

#### ПАТОМОРФОЛОГІЧНІ ОСОБЛИВОСТІ ПІДТВЕРДЖЕНОЇ БРОНХОГЕННОЇ КІСТИ З АТИПОВОЮ ЛОКАЛІЗАЦІЄЮ

**Хорошун Е. М., Негодуйко В. В., Воровський О. О., Макаров В. В., Бунін Ю. В., Смолянник К. М.**

Серед усіх утворень середостіння у дорослого населення кісти становлять близько 20 %, з яких понад 60 % припадає на бронхогенні кісти, де до 50 % мають безсимптомний перебіг, а тому в більшості випадків виявляються випадково. Незалежно від перебігу та походження, кісти підлягають повному хірургічному видаленню. У зв'язку з клінічним і радіологічним поліморфізмом бронхогенних кіст, гістологічне підтвердження походження кіст не втрачає актуальності. Мета роботи - вивчити та висвітлити патоморфологічну характеристику кісти з локалізацією в перикарді. Із застосуванням відеоасистентної торакальної хірургії (video-assisted thoracic surgery - VATS) і торакотомічних доступів були прооперовані 16 осіб у віці від 28 до 62 років з кістозними ураженнями середостіння. Пацієнти пройшли рентгенографічне обстеження, комп'ютерну томографію з внутрішньовенним введенням контрасту та у 2 випадках - магнітно-резонансну томографію. Ультразвукове дослідження виконали 6 пацієнтам, у котрих кістозні ураження були діагностично знахідкою. Оцінювали розташування кісти, максимальний діаметр, щільність, кальцифікацію. У передваскулярному відділі клінічно та рентгенологічно виявили безсимптомні перикардальні (целомічні) кісти у 2-х осіб. У вісцеральному відділі середостіння 3 пацієнти мали перикардальну кісту, у 10 пацієнтів діагностували 10 бронхіальних кіст з паренхіматозною та перигілярною локалізацією, серед яких в одного пацієнта діагностували безсимптомну бронхіальну кісту з атиповою локалізацією в перикарді. У паравертебральному відділі середостіння встановлена 1 параезофагеальна кіста, котра була інтимно злучена з нижньою третинною грудного відділу стравоходу. Всі види кіст були гістологічно підтверджені. Статистичну обробку отриманих результатів проводили за допомогою програми Excel. Після клінічного обстеження пацієнта з кістою перикарда вісцерального відділу середостіння виконана операція VATS справа та видалення кісти. Гістологічне дослідження фрагментів стінки кісти показало наявність багаторядного війчастого циліндричного епітелія, виражену інфільтрацію лімфоїдними елементами з геморагіями та осередками фібротизації на окремих ділянках. Гістологічна будова видаленої кісти перикарда підтвердила її бронхогенне походження. Отже, нами виявлена рідкісна форма аномалії ембріонального росту вентральної частини передньої кишки з локалізацією бронхогенної кісти в передньо-нижньому середостінні справа, що значно розширило розуміння хвороби.

**Ключові слова:** бронхогенна кіста, рентгенографія, відеоасистентна торакальна хірургія, гістологія.

---

#### Author's contribution

*Khoroshun E. M.* - project administration.

*Nehoduiko V. V.* - conceptualization, research, data visualization.

*Vorovskiy O. O.* - methodology and writing of the original draft, review writing and editing.

*Makarov V. V.* - supervision, formal analysis and validation.

*Bunin Yu. V.* - data visualization, resources.

*Smolyannik K. M.* - resources, software.