

See discussions, stats, and author profiles for this publication at: <https://www.researchgate.net/publication/339587138>

The use of CNFA lectin in the diagnosis of precancerous changes in the gastric mucosa in patients with *Helicobacter pylori*-associated chronic gastritis

Article · January 2020

CITATIONS

0

READS

193

5 authors, including:



[Sergii Vernygorodskiy](#)

National Pirogov Memorial Medical University, Vinnytsya

58 PUBLICATIONS 54 CITATIONS

[SEE PROFILE](#)



[Daryna Sukhan](#)

National Pirogov Memorial Medical University, Vinnytsya


5 PUBLICATIONS 4 CITATIONS

[SEE PROFILE](#)



Original Article

The use of CNFA lectin in the diagnosis of precancerous changes in the gastric mucosa in patients with *Helicobacter pylori*-associated chronic gastritis

Vernygorodskyi Sergii Viktorovych , Sukhan Daryna Serhiyivna, Berezovskyi Artur Mykolaiovych, Panasiuk Volodymyr Ivanovych

Department of Pathological Anatomy, Forensic Medicine and Law, National Pirogov Memorial Medical University, Vinnytsya, Ukraine

Received: 16 June 2019 / Accepted: 08 October 2019

Abstract

Background: This study aims to analyze the features of CNFA (*Clitocybe nebularis* fungus agglutinin labeled) lectin binding to glycoproteins of the gastric mucosa in patients with *Helicobacter pylori*-associated chronic gastritis with varying degrees of neoplasia.

Methods: Biopsies were performed during endoscopy, considering the requirements of the modified Sydney system. Biopsy material was obtained from 365 people who applied to a regional medical hospital and processed using conventional histological methods. Carbohydrate determinants were detected in accordance with the protocol of lectin-peroxidase-diaminobenzidine staining. The interpretation of the results of the study was carried out by an examination of four pathologists, independently of each other.

Results: Lectin-histochemical analysis of the distribution of carbohydrate determinants to N-acetylgalactosamine-specific lectin CNFA in *Helicobacter pylori* (+) (*H. pylori*) patients with chronic non-atrophic gastritis (CNG) and chronic atrophic gastritis (CAG) has established a moderate and diffuse strong CNFA depression in super nuclear zones of the mucous neck cells with a significant increase in the expression of CNFA ($p=0.001$) in CAG patients with high-grade of neoplasia. At the same time, in 70% and 95% of patients respectively, the expression of CNFA lectin was increased in places of accumulation of *Helicobacter* infection compared with 30% of *H. pylori* patients ($p=0.001$).

Conclusions: According to the results of our study, CNFA lectin may serve as an additional marker for assessing dysplastic changes in the gastric mucosa in patients with *Helicobacter pylori*-associated chronic gastritis.

Keywords: gastritis, *Helicobacter pylori*, lectins, neoplasia

Address for Correspondence: Vernygorodskyi Sergii Viktorovych, Department of Pathological Anatomy, Forensic Medicine and Law, National Pirogov Memorial Medical University, Pirogov Street, 56, Vinnytsia 21018, Ukraine. E-mail: vernsot@rambler.ru

DOI: 10.5455/im.52981

This is an Open Access article under the terms of the Creative Commons Attribution-NonCommercial 4.0 International License (<https://creativecommons.org/licenses/by-nc/4.0/>)

Introduction

The carbohydrate determinants of gastric mucosal glycoproteins and their participation in neoplastic transformation at atrophic and dysplastic changes remain insufficiently studied both by morphologists and clinicians. The hydrocarbon determinants of glycoconjugates of cells and intercellular matrix realize the fundamental processes of vital activity, namely, contact inhibition of proliferation, differentiation, initiation of apoptosis processes [1].

For qualitative morphological analysis of the mucous secretion, along with the commonly used histochemical methods, lectin histochemistry is also used, which enables the identification of individual carbohydrate determinants. The CNFA lectin from the fruiting bodies of the *Clitocybe nebularis* fungus agglutinin exhibits selective specificity to glycoconjugates with the Gal β 1-4Glc and DGalNAc carbohydrate determinants. According to Antonyuk and Lutsyk, it is established that CNFA expression is practically absent in epitheliocytes of normal mucosa of the large intestine, along with it CNFA has the ability to selectively interact with carbohydrate determinants in the tumors of the large intestine [2].

Taking into account the related paths for carcinogenesis in the gastrointestinal tract, we considered it necessary to apply this method for the early and differential diagnosis of dysplastic changes of the gastric mucosa (GM) in patients with *Helicobacter pylori*-associated gastritis.

Methods

The clinical examination was conducted in 365 people: 236 men, 129 women. The study group consisted of 325 people with a diagnosis of chronic gastritis: 111 women and 214 men. The control group included 40 persons (18 female and 22 male) without a history of gastroenterological pathology. In the study, the ethical principles of the World Medical Association Declaration of Helsinki (1964) were adhered to. The study protocol was reviewed and approved by the Bioethics Committee at Vinnytsia National Pirogov Memorial Medical University.

Biopsies were performed during endoscopy (two biopsies from the body and antrum of the stomach and one from the antrum area), considering the requirements of the modified Sydney system [3] and the subsequent histological study of the biopsy. The biopsy material was examined using conventional histological methods. The following methods were used to determine the dysplastic and atrophic changes in the gastric mucosa: staining with hematoxylin and eosin, alcian blue at pH 1.0 and 2.5 in combination with PAS reaction by Mowry [4].

The determination of the persistence of *H. pylori* in GM was performed by a rapid urease test [5,6], cytologically according to Papenheim [6,7] and histologically-stained by Giemsa, toluidine blue for Slater [8] and el-Zimaity et al [9]. The degree of colonization of GM was estimated by Aruin [10].

CNFA lectin of *Clitocybe nebularis* fungus agglutinin labeled with peroxidase of horseradish by Antonyuk method [11] obtained from the raw materials of the Carpathian region in the laboratory "Lectinotest" of the Lviv National Medical University named after Danilo Galitsky. The concentration of lectin in 1 ml of buffered saline 30 mg carbohydrate specificity of GalNAc β 1-4GlcNAc. The lectin-histochemical study was performed by the method of Lutsik et al [12]. Locations of peroxidase localization on sections of chromogen were detected (3,3-diaminobenzidine tetrahydrochloride). The results were evaluated in the presence of brown sieve in places of peroxidase localization. The microscopy was viewed and photographed using a video system and a licensed Olympus Quick Photo Micro 2.3. using the Olympus E-410 digital camera.

Student's t-test was used to determine the statistical significance of differences in the mean values. The number of subjects in each group (n_1 and n_2) was determined. Next, find the number of degrees of freedom f by the formula: $f = (n_1 + n_2) - 2$. Then, determine the critical value of the Student's t-test for the required level of significance (for example, $p = 0.05$) and given the number of degrees of freedom f by conventional tables. If the calculated value of the Student's t-test is equal to or more than the critical one found in the table, we conclude on the statistical significance of the differences between the compared values. If the value of the Student's t-test is less than the table value, then the differences of the compared values are not statistically significant.

Each case was assigned a code number, after which they were interpreted by an examination of four pathologists who act as authors of the publication independently. The results obtained were compared with the code number and decoded.

Results

In our work, we followed the Ethical Principles of the World Medical Association Declaration of Helsinki (1964). All patients were informed and signed informed consent, confirming their voluntary participation in the study.

In practically healthy patients, both 23 H. pylori-positive (H. pylori +) and 17 H. pylori-negative (H. pylori -) superficial and pit epithelium (SPE) GM had a typical histological structure formed by one layer of high columnar mucin-forming cells, which had basically located nucleus and cytoplasm with mainly neutral mucins.

In the group of practically healthy H. pylori (-) patients, the lectin-histochemical reaction showed a small affinity in the form of weak conjugation with isolated SPE cells, parietal exocrinocytes of the fundus and SPE of the antral part of GM. However, in H. pylori (+) patients, strengthening of CNFA lectin sensation to moderate expression in the SPE, weak in the mucous neck cells and the appearance of expression in the parietal exocrinocytes of the fundus of the stomach, weak conjugation in the SPE, and the appearance of a moderate CNFA exposure in the SPE, mucous neck cells and pyloric exocrinocytes of the antral part of GM [Table 1].

Table 1. Comparative assessment of the intensity of CNFA lectin-histochemical reactions in GM cells in practically healthy individuals

H. pylori	Fundus of the stomach				Antrum of the stomach		
	SPE	MNC	CE	PE	SPE	MNC	PIE
H. pylori (-)	+	-	-	+	+	-	-
H. pylori (+)	++	+	-	+	+	+	+

SPE: Superficial and pit epithelium, MNC: Mucous neck cells, CE: Chief exocrinocytes, PE: Parietal exocrinocytes, PIE: Pyloric exocrinocytes. + weak expression, ++ moderate expression, +++ strong expression, - absent expression.

Lectin-histochemical analysis of the distribution of carbohydrate determinants to N-acetylgalactosamine-specific lectin CNFA in H. pylori (+) patients with chronic non-atrophic gastritis (CNG) and chronic atrophic gastritis (CAG) observed a moderate and site-intensive CNFA expression in super nuclear zones of the mucous neck cells [Table 2] with a significant increase in expression of CNFA (p=0.001) in patients with CAG and high-grade neoplasia [Table 3]. In 70% and 95% of patients, respectively, especially in the places where the helicobacter infection is concentrated, that is, with high levels of contamination (more than 50 microbial bodies in the field of vision of x1000), compared with 30% of H. pylori patients (p=0.001). In addition, we have established an increase in the expression of this marker in the pylorization of the fundic glands in patients with a multifocal CAG in the spread of atrophy from the antral to the fundus part, both in H. pylori (+) and H. pylori (-) patients (p=0.003 and p=0.004 respectively).

Table 2. Comparative estimation of the intensity of CNFA lectin-histochemical reactions in GM cells in patients with chronic gastritis

Nosology	H. pylori (-)							H. pylori (+)						
	Fundus of the stomach				Antrum of stomach			Fundus of the stomach				Antrum of stomach		
	SPE	MNC	CE	PE	SPE	MNC	PIE	SPE	MNC	CE	PE	SPE	MNC	PIE
CNG without neoplasia	+	+	-	+	+	+	+	++	++	-	++	++	++	++
CNG with neoplasia	+	+	-	+	+	+	+	++	+++	-	++	++	+++	++
CAG without neoplasia	+	-	-	+	-	-	+	++	++	-	++	+	++	++
CAG with neoplasia	+	-	-	+	-	-	+	+++	+++	-	++	+++	+++	++

CNG: chronic non-atrophic gastritis, CAG: chronic atrophic gastritis, SPE: Superficial and pit epithelium, MNC: Mucous neck cells, CE: Chief exocrinocytes, PE: Parietal exocrinocytes, PIE: Pyloric exocrinocytes. + weak expression, ++ moderate expression, +++ strong expression, - absent expression.

It should be noted that the number of N, N'-diacetyl lactose diamine receptors in glycans was significantly increased (p=0.002) with the progression of dysplastic changes in GM in all of its structural components, and with severe neoplasia revealed strong expression of CNFA lectin, and with mild predominantly focal moderate in SPE and mucous neck cells [Figure 1, 2]. The indicated tendency can be

regarded as a manifestation of violations of the processes of finish glycosylation in the Golgi complex and the delay in the inclusion of glycopolymers in apical plasmalemma.

Table 3. Comparative assessment of the intensity of lectin-histochemical reactions in *H. pylori* (+) GM epithelial cells in patients with CAG

Lectin (carbohydrate specificity)	Neoplasia	
	Low	High
CNFA (GalNAcβ1-4GlcNAc)	+	+++

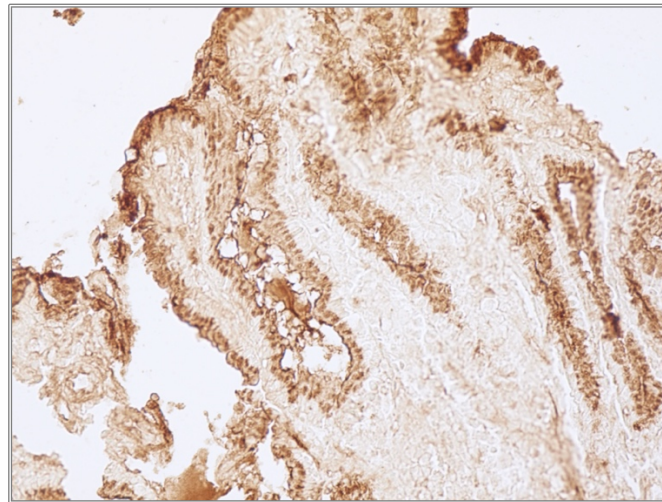


Figure 1. Focal moderate CNFA expression in SPE and CM in areas of foveolar hyperplasia and low-grade neoplasia in *H. pylori* (+) CAG patient, stage 2. Biopsy of the antral part of the stomach. CNFA-binding, x100.

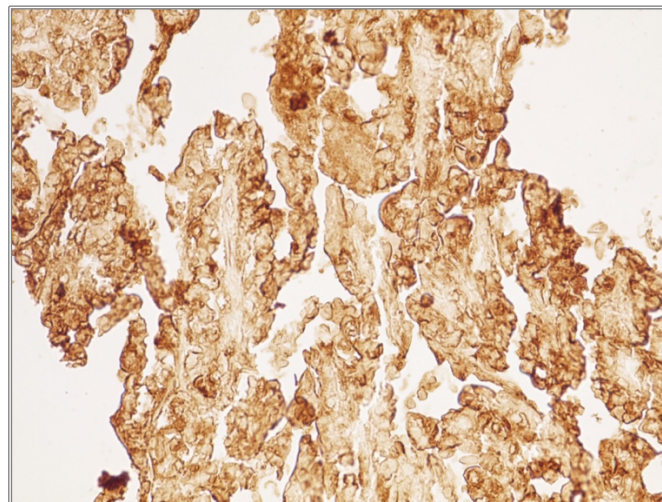


Figure 2. Strong expression of CNFA in SPE and CM in areas of high-grade neoplasia in *H. pylori* (+) CAG patient, stage 2. Biopsy of the antral part of the stomach. CNFA-binding, x400.

Discussion

It is known that lectin from the fruiting bodies of the fungus *Clitocybe nebularis* binds to leukemic cells and does not interact with normal, but with the cells of some tissues only interacts with their tumorigenicity [13-15]. Thus, Hirano and co-authors, show that the amount of N, N'-diacetyl lactose diamine receptors in glycans are significantly reduced in breast cancer and vice versa, these receptors may be markers for the progression of prostate, ovarian and pancreatic cancer [16]. Normally, these receptors are very rare in mammalian cells but appear in tumorigenesis of the aforementioned cells in humans. In our study, we observed a similar picture, but there were peculiarities, namely:

1. The presence of *Helicobacter* infection in patients significantly enhanced the expression of CNFA compared with practically healthy persons with *H. pylori* (-).
2. In patients with CNG and CAG in mild neoplasia, the mild-moderate expression of this lectin was detected in the epithelial cells and mucous neck cells, and in severe conditions.

However, Schur with co-authors found the ability of the GalNAc β 1-4GlcNAc-specific lectin receptors CNFA in the lacrimal gland of control animals to be identified in collagen fibers of the connective tissue capsule and stroma of the gland, indicating the phase of their secretory cycle [17].

Lutsyk points to the role of CNFA lectin receptors as a marker of morphogenesis of adrenal glycopolymers in the experiment in rats. Thus, it is possible to consider that receptors to CNFA are characteristic not only for neoplastic cell transformation but also for physiological processes in a healthy cell [2].

Yashchenko and others demonstrate selective binding of CNFA lectin to shoreline macrophages of rat lymph nodes. It has recently been shown that CNFA may be of some interest for the early histochemical diagnosis of human colon tumors, which increases the diagnostic value of this method [18].

Enhanced CNFA (LacdiNAc-GalNAc β 1-4GlcNAc) lectin-histochemical sensing has once again confirmed the acquisition of galactose binding directly with cells of the superficial epithelium of GM, which was a hallmark of *H. pylori* in infected patients and consistent with data of [19]. However, the polarity of the literature indicates that the properties of GalNAc β 1-4GlcNAc- are poorly understood.

Conclusion

Consequently, lectin from the fruiting bodies of *Clitocybe nebularis* fungus agglutinin may be recommended as an additional histochemical marker for *Helicobacter* infection, as well as for differential diagnosis of low and high-grade neoplasia of GM.

The data obtained by us deepen the existing ideas regarding the molecular mechanisms of the development of dysplastic changes of the gastric epithelium. In this paper, the use of CNFA lectin for selective histochemical detection of low and high-grade neoplasia of GM is shown. The results of the research can be used in practical gastroenterology to develop new approaches in the diagnosis and treatment of *Helicobacter pylori*-associated gastritis.

Conflict of interest

All authors declare that they have no conflict of interest.

Funding

There was no funding received for this article.

References

1. Lutsyk SA, Yashchenko AM. Application of lectin histochemistry methods for the investigation of influences of thyroid hormones imbalance on the organism. *Acta Medica Leopoliensia* 2018;24:64-8.
2. Antonyuk RV, Lutsik OD. Lectinohistochemical research of colon in humans at normal and at neoplastic process using lectins specific for T-antigen and N-acethylactosamine. *World of Medicine and Biology* 2015;49:73-8.
3. Dixon MF, Michael D, Path FR, Correa P. Classification and grading of gastritis: the updated Sydney system. *Am J Surg Pathol* 1996;20:1161-81.
4. Mowry RW. Alcian blue techniques for the histochemical study of acidic carbohydrates. *Histochem Cytochem* 1958;6:82.
5. Medvetsky EB, Viltsanyuk IO. Method of *Helicobacter pylori* staining in cytological preparations. *Herald of Morphology* 2001;7:154-5.
6. Zheleznyakova NM. Verification ways of *Helicobacter pylori* and evaluation of their informativeness in peptic ulcer and chronic gastritis. *Gastroenterology* 2004;4:46-8.
7. Asonuma S, Imatani A, Asano N, Oikawa T, Konishi H, Iijima K, et al. *Helicobacter pylori* induces gastric mucosal intestinal metaplasia through the inhibition of interleukin-4-mediated HMG box protein Sox2 expression. *Am J Physiol Gastrointest Liver Physiol* 2009;297:312-22.
8. Slater B. Superiorstain for *Helicobacter pylori* using toluidine. *J Clin Pathol* 1990;43:961.
9. El-Zimaity HMT, Jian W, Graham DY. Modified Genta triple stain for identifying *Helicobacter pylori*. *Clin Pathol* 1999;52:693-4.
10. Aruin LI, Isakov VA. Evaluation of the contamination of the gastric mucosa of *Helicobacter pylori* and the activity of chronic gastritis. *Arkh Patol* 1995;3:75-6.
11. Antonyuk VO. Lectins and their stock sources. Lviv: Kvant; 2005.
12. Lutsik MD, Panasyuk EN, Antonyuk, VA, Lutsik AD, Ladnaya LA. Methods for the study of carbohydrate specificity of lectins (guidelines). Lviv: Publishing house at Lviv; 1983.
13. Ambarov BT. Lectin of the fungus of the gumlika *dimchastogo* (*clitocybe nebularis* fr.). A new chemical reagent for the complete morphogenesis and nistopathology. *Holy Medicine and Biology* 2016;55:119-21.

14. Machado E, Kandzia S, Carilho R, Altevogt P, Conradt HS, Costa J. N-Glycosylation of total cellular glycoproteins from the human ovarian carcinoma SKOV3 cell line and of recombinantly expressed human erythropoietin. *Glycobiology* 2010;21:376–86.
15. Huang J, Liang JT, Huang HC, Shen TL, Chen HY, Lin NY, et al. 1,4-N-Acetylgalactosaminyltransferase III enhances malignant phenotypes of colon cancer cells. *Mol Cancer Res* 2007;5:543–52.
16. Hirano K, Matsuda A, Shirai T, Furukawa K. Expression of LacdiNAc groups on n-glycans among human tumors is complex. *Biomed Res Int* 2014;2014:981627.
17. Schur MB, Strus Kh. I, Lutsik MM, Yashchenko AM. Influence of experimental hypothyroidism, induced by thiamazole, on citotopography of cliticibe nebularis fungus lectin receptors in the structural components of rats lacrimal glands. *Bulletin of Problems in Biology and Medicine* 2019;2:265-9.
18. Yaschenko AM, Antonyuk VO, Nakonechna OV. Cytotopography of the lectins receptors in the structural components of immunogenesis organs. *Acta Medica Leopoliensia* 2005;9:96-100.
19. Rossez Y, Gosset P, Boneca IG, Magalhães A, Ecobichon C, Reis CA, et al. The lacdiNAc-specific adhesin LabA mediates adhesion of *Helicobacter pylori* to human gastric mucosa. *J Infect Dis* 2014;210:1286-95.