



JOURNAL OF SOCIAL SCIENCES, NURSING, PUBLIC HEALTH AND EDUCATION

SCIENTIFIC PEER-REVIEWED JOURNAL

I

ISSN 2644-6006

№ 1, 2021

JOURNAL OF SOCIAL SCIENCES, NURSING, PUBLIC HEALTH AND EDUCATION

№ 1, 2021

Editorial Board

Editor in Chief:

doc. PhDr. et Bc., Jaroslav Stančiak, PhD., MPH, UK, PdF

Editorial board:

prof. Andrzej Kryński, Ph.D.

prof. MUDr. Jozef Novotný, PhD.

prof. Piotr Lisowski, Ph.D.

prof. RNDr. Edita Partová, PhD, PdF, UK

prof. MUDr. Viktor Shatylo, PhD., Dr. h.c., UK

prof. PaedDr. Alica Vanchová, CSc. PdF, UK

prof. MUDr. Vitaliy Zabolotnov, PhD

doc. PhDr. Jana Boronova, PhD.

doc. Svitlana Gordiichuk, Ph.D.

doc. PhDr. et Bc., Jaroslav Stančiak, PhD., MPH, UK, PdF

doc. Natalia Shygonska, Ph.D.

PhDr. Ján Holonich, PhD. MBA, LL.M., UK, PdF

Ing. Marek Nickel, MBA, (EBG)

Mgr. Andrej Hutta, MBA

prof. Yuriy Andrashko, DrSc.

doc. Olena Yatsyna, CSc.

PhDr. Oleksandr Rishko, CSc.

prof. Evheny Kostenko, DrSc.

prof. Oksana Klitinska DrSc.

prof. Anatoly Potapchuk, DrSc.

prof. Ivan Myronyuk, DrSc.

prof. Hennadiy Slabkyi, DrSc.

PhDr. Svetlana Steblyuk, CSc.

Prof. Dr. Nick Palinchak, DrSc.

Prof. JUDr. Dmytry Byelov, DrSc.

JUDr. Myroslava Hromovchuk, CSc.

Prof. Dr. Andriy Rusyn, DrSc.

Quest editor:

doc. RNDr. Edita Partová, CSc.

prof. PaedDr. Bernhard Beckmann

ISSN 2644-6006



CONTENT

Belikov O., Sorokhan N., Belikova N., Roshchuk O., Vatamaniuk N. COMPARATIVE CHARACTERISTICS OF THE PHYSICOMECHANICAL PROPERTIES OF SELF-ETCHING SELF-ADHESIVE CEMENTS FOR INDIRECT RESTORATIONS	5
Byelov Dmytry, Holonich Ján THE PRINCIPLE OF HUMANISM IN THE STATE INDIVIDUAL RELATIONSHIP	11
Domanchuk T., Chornenka Z. ANALYSIS OF INCIDENCE AND MORTALITY FROM GASTRIC CANCER AMONG THE MALE AND FEMALE POPULATION IN CHERNIVTSI REGION AND UKRAINE FOR 2010-2019	17
Hromovchuk Myroslava, Holonich Ján PRINCIPLE OF HUMANISM IN MEDICINE: CERTAIN ASPECTS.....	25
Kaskova L., Drozda I. DEPENDENCE OF VALUES OF HYDROGEN INDICATOR AND MINERALIZING POTENTIAL OF ORAL FLUID ON THE DEGREE OF CARIES ACTIVITY, AGE IN ADOLESCENTS IN ADOLESCENTS	29
Khanyk Nataliia, Hromovyk Bohdan, Chykhay Iryna, Horodetska Iryna ANALYSIS OF THE ASSORTMENT OF NASAL PREPARATIONS FOR TOPICAL USE IN THE STATE REGISTER OF MEDICINES OF UKRAINE.....	35
Klitynska Oksana, Zorivchak Tetiana, Shetelya Volodymyr, Stishkovskyy Andriy ASSESSMENT OF THE CONDITION OF TEETH ENAMEL	41
Konoplitskyi V., Korobko Y. ANAL MANOMETRY AND TOTAL INDEX OF ENDOGENOUS INTOXICATION IN THE DIAGNOSIS OF ACUTE APPENDICITIS	48
Konoplitskyi V., Pasichnyk O. RADICALISM OF THE OPERATING FIELD IN THE REMOVAL OF PIGMENTED NEVI IN CHILDREN.....	55
Malysh N., Melekhovets O., Loboda A., Chemych O., Svikolnik A., Denysenko A. COGNITIVE IMPAIRMENT FEATURES AND LIFE QUALITY ASSESSMENT OF PATIENTS WITH CHRONIC VIRAL HEPATITIS C.....	62
Miklášová Petra, Stančíak Jaroslav DUŠEVNÉ OCHORENIE „SCHIZOFRÉNIA“ A JEJ DOPAD NA KVALITU ŽIVOTA NOSITEĽA OCHORENIA.....	69
Oliyunk A. METHODS OF TREATMENT OF LOCALIZED PERIODONTITIS	74

Pavlenko Oleksiy, Mochalov Iurii, Sluchevska Olena, Hasiuk Natalia, Keian David, Yurzhenko Anastasiya	
THE MAIN CYTOKINES OF INFLAMMATORY RESPONSE IN PERIODONTAL TISSUES, THERAPEUTICAL TARGETS: A REVIEW	87
Potapchuk A., Kostenko Y., Almashi V., Onipko Y.L., Moshak Y., Melnyk Y., Pirchak I.	
CLINICAL EVALUATION OF THE EFFECTIVENESS OF APPLICATION OF PHOTOACTIVE DISINFECTION IN THE TREATMENT OF LOCALIZED PERIODONTITIS IN CHILDRE	100
Prolom N., Shevchenko B., Zeleniuk O.	
DIAGNOSIS AND SURGICAL TREATMENT OF HIATAL HERNIAS.....	108
Ratushnyi Ruslan	
JUSTIFICATION OF THE PREVALENCE OF MAIN MISTAKES AND COMPLICATIONS IN ENDODONTIC TREATMENT OF MANDIBULAR TEETH.....	114
Romanyuk L., Kravets N.	
ANALYSIS OF THE RESULTS OF THE QUESTIONNAIRE OF MEDICAL STUDENTS ABOUT THE CORONAVIRUS INFECTION.....	119
Stepanov Yu., Titova M.	
SOMATOMETRIC AND BIOCHEMICAL STUDIES IN COMPLEX ASSESSMENT OF NUTRITIONAL SATUS IN CHRONIC INFLAMMATORY BOWEL DISEASE	124
Medyanik V.A.	
HISTORY OF ESTABLISHMENT AND DEVELOPMENT OF ADMINISTRATIVE AND LEGAL SUPPORT OF STATE SOCIAL POLICY.....	132
Hretsa S.M.,	
OF CONSTITUTIONAL DUTIES (ACCORDING TO THE DECISIONS OF THE CONSTITUTIONAL COURT OF UKRAINE).....	138
Kumanska-Nor O. P.	
MODERN APPROACHES TO THE DEFINITION OF ADMINISTRATIVE SERVICES AND THEIR FEATURES IN UKRAINE	144
Ivaniv Ivanna	
THE SPECIFICS OF THE FORMATION OF THE JUDICIARY OF CONSTITUTIONAL JURISDICTION ABROAD AND IN UKRAINE: FEATURES OF TAKING INTO ACCOUNT FOREIGN EXPERIENCE	151
Kovtuniak Viktoria	
THEORETICAL AND PRACTICAL ISSUES OF CONSTITUTIONAL CONTROL IN THE PROCESS OF AMENDING THE CONSTITUTION: FEATURES OF IMPLEMENTATION.....	158

RADICALISM OF THE OPERATING FIELD IN THE REMOVAL OF PIGMENTED NEVI IN CHILDREN

Konoplitskyi V.,

head of the Department of children surgery National Pirogov Memorial Medical University, Vinnytsia, Ukraine; doctor of Medical Science, Full professor; orcid.org/0000-0001-9525-1547; vkonoplytsky@gmail.com.

Pasichnyk O.,

assistant lecturer of the of the department of children surgery National Pirogov Memorial Medical University, Vinnytsia, Ukraine; orcid.org/0000-0001-8302-3520; lundqist747@gmail.com.

Annotation. The purpose of the study - to increase the efficiency of determining the degree of radicalism in the removal of pigmented skin nevi in children, taking into account the thickness of the hypodermis in different anatomical parts of the body.

Materials and methods of research.

The work was performed on the basis of the Department of Oncohematology of Vinnytsia Regional Children's Clinical Hospital in the period from 2018 to 2020. The clinical distribution of features of surgical interventions for skin pigmented nevi included analysis of medical records of outpatients and inpatients (120 documents). The age of patients of both sexes ranged from 3 to 16 years. Patients with localization of pigmented neoplasms in different areas were analyzed.

Results. The model for calculating the planar parameters of the surgical wound is based on the ratio of the size of the removed tissues in the form of ellipses at the level of the skin and at the level of the deep fascia, taking into account the thickness of the hypodermis. For a more simplified perception of the logic of the calculation, the shape of the operating space is proposed to be considered as a cone.

Geometrically, the computational model is in the form of a triangle, the vertex of which unfolds at an angle of 25° , and which is an inverted by 180° analogue of classical angle of operational action.

Conclusions. The proposed method of determining the radicalism of removal of pigmented skin nevi by mathematical calculation of the ratio of areas of removed tissues at the skin level and at the level of the aponeurosis taking into account the thickness of the hypodermis in different parts of the body allows to calculate individual surgical wound parameters. Due to the large number of pigmented nevi of different localization in childhood and a careful approach to determining the indications for surgical treatment in the last decade there has been an extensional annual increase in the number of operated children.

Key words: operating field, benign neoplasms, incision.

Introduction.

The term "nevus" (latin – birthmark, scar) was first used by R. Virchow (1863) to designate birthmarks of the skin. A broader interpretation was provided by J. Jadasson (1914), including malformations and some benign skin tumors in this group. The true meaning of the term "nevus" implies the presence of melanocytes or nevus cells in neoplasms. All variants of natural nevi are derivatives of melanocytes, melanin-producing cells, which explains the color of the neoplasms, which, according to the WHO classification, belong to hamartomas, which confirms their dysembryonic origin [7].

In general, the pigmented nevus combines a number of hamartomas of the skin with general clinical and histological signs; these are malformations that are formed by mature or almost mature components of the epidermis, sebaceous glands, hair follicles, apocrine and exocrine sweat glands and their combinations. Pigmented nevi in 80% of cases are observed in the first year of life and are sporadic. Melanocyte neoplasms of the skin attract the attention of specialists primarily due to their high prevalence, but also because this group of diseases includes melanoma of the skin, which often develops from a benign pigmented neoplasm – nevus [3,17]. Congenital melanocyte nevi are found in 1% of newborns [12]. Particular attention is paid to dysplastic nevi, which include epidermal and mixed nevi, the diameter of which exceeds 5 mm with an uneven distribution of pigment on the surface and fuzzy contour [7]. According to some authors, melanoma of the skin in children occurs in 20% of nevi of small and medium size [2,3,11,16].

Often, due to the apparent simplicity of surgical treatment of pigmented skin nevi, simplified medical manipulations are used, which negatively affects the course of the disease and long-term results, one of which is the recurrence of the disease [13]. The world literature provides various data on the frequency of recurrences after treatment of pigmented nevi, the rate of which ranges from 6% to 41% [8,9]. In the domestic literature, the recurrence rate is given within 20% [10].

In addition, in the practice of surgeons and oncologists there are cases when in the area of removal of pigmented nevi there are foci of pigmentation [15,16]. In the WHO classification, such nevi are classified as "persistent melanocytic nevus", ie "prolonged nevus growth", which is a complicated course of the disease, which by its histogenesis is a separate form of pathology that does not correspond to a pure recurrence of the tumor [1,6,14]. In order to improve the results of surgical treatment of skin neoplasms using techniques of surgical excision of skin with tumor, adipose tissue and adjacent fascia in a single block at an obtuse angle to the wound base, which increases the volume of excised fat and lymphatic capillaries compared to traditional approach [5].

But when determining the ratio of the area of the excised skin flap to the area of tissues at the level of the fascia, their correlation with the thickness of the hypodermis is not taken into account, the size of which varies in different parts of the body, which in turn reduces the radicalism of the intervention.

Therefore, given the significant percentage of negative consequences of treatment of pigmented nevi in due to the large number of recurrences, lack of a single view on surgical tactics of radical removal of tumors, an attempt was made to determine the feasibility of radical treatment of pigmented tumors.

The purpose of the study – to increase the efficiency of determining the degree of radicalism in the removal of pigmented skin nevi in children, taking into account the thickness of the hypodermis in different anatomical parts of the body.

Materials and methods of research.

The work was performed on the basis of the Department of Oncohematology of Vinnytsia Regional Children's Clinical Hospital in the period from 2018 to 2020. The clinical distribution of features of surgical interventions for skin pigmented nevi included analysis of medical records of outpatients and inpatients (120 documents). The age of patients of both sexes ranged from 3 to 16 years. Patients with localization of pigmented neoplasms in different areas were analyzed.

Research results and their discussion.

The hypothesis of the study was to calculate the ratio of skin area, together with the pigmented tumor, in children to the area of the removed hypodermis at the level of the aponeurosis. In implementing this hypothesis, the data obtained in recent years on the features of anatomical structures, which are located between the dermis, deep fascia and aponeurosis, were taken into account. This approach is due to the fact that the architecture of the vascular component of the hypodermis is very interesting for oncologists due to the persistent course of pathology, the possibility of metastasis of tumors and subsequent prognosis of the disease.

Thus, in ultrasonic lipodestruction, without damage to ultrastructures, after evacuation of destroyed tissues to the level of the aponeurosis, it was determined that only up to 2/3 of connective tissue strands and vessels of the skin with a pronounced network of collaterals have a vertical direction, and the rest are located diagonally or horizontally most of which have a flat structure. Most vessels in the hypodermis are located in the connective tissue membranes, but are connected by collaterals. Thus, the presence in the hypodermis of a pronounced vascular-depositing structure, can ensure its direct participation in pathological processes associated with recurrence and generalization of pigmented skin tumors [4].

Usually, the retreat from the visible borders of the tumor range from 1.0 to 2.0 cm. Відповідно до According to the International Standard ESMO (European Society of Medical Oncology, 2004), treatment of local stages of melanoma of the skin should be performed with extensive excision of the primary tumor within healthy tissues with excision of the edges of the tumor base: 0.5 cm – for melanoma in situ; 1.0 cm – with a tumor thickness of 1 – 2 mm according to Breslow; 2.0 cm – with a tumor thickness > 2 mm, but <4 mm; in primary tumors with severe invasion > 4 mm thick, an indentation greater than 2.0 cm may be recommended [18]. Along with a sufficient retreating from the edges of the pigment formation, the depth of excision of the tumor from the underlying tissues is important. The standard of oncological radicalism is considered to be surgery in which a sufficient block of tissues is excised, consisting of skin, subcutaneous tissue and fascia. This volume guarantees the success of the operation in most cases. Given the above effect of the principle of divergent segmental blood flow and lymphatic outflow in the form of a triangle with a vertex in the center of the tumor, removal of equal volumes of tissue at the levels of superficial and deep fascia should not be considered as radical intervention. Therefore, it is logical to make incisions in the skin and underlying soft tissues not at right angles, but at a certain obtuse angle, which provides a smaller volume of excised skin than the volume of removed fascia and adipose tissue with vessels passing through them.

Another component of the research hypothesis was the determination and evaluation of the values of certain components of the adequacy of surgical access.

In miniinvasive operations, the depth prevails over the length, which accordingly creates limited conditions when performing the operation.

The observation axis is an image transmission line that connects the surgeon's eye and the object of surgery, which in miniinvasive procedures is not necessarily a straight line, but may consist of several segments of straight lines, be curved, have a complex shape or even have virtual areas. An important condition is that the axis of direct observation of the object under any conditions must remain free and not overlap with tools.

The axis of the operation, which has the form of a line of transmission of physical actions from the hands of the surgeon to the object of operation, can also have the form of a complex trajectory. The longer and more complex the trajectory, the more difficult it is to perform surgery. Given the small size of operational access, the axes of observation and operational action do not coincide, and in some areas may be located in parallel, not overlapping each other.

Minimally invasive surgical interventions are characterized by limited surgical access, as a result of which only certain parts of anatomical formations remain accessible, which largely determines the success of the intervention.

Miniinvasive interventions are characterized by the shape of the operating space in the form of a «cone», «tube» or «retort flask», which is characterized by a wide base. Such forms of operating space are not accidental, but the most appropriate, as their volume is several times greater than its cylindrical counterpart, which provides greater freedom in surgical manipulations, allowing to maximize the space located directly above the area of access (the more the free space, the easier it is to operate). Expanding this part of the access 2 times increases the area of the accessibility zone in 4 times, and the volume of the adjacent part of the free operating space increases 8 times. Thus, the form of access with increasing its area at the level of the aponeurosis provides maximum freedom of operation in the area of accessibility with a minimum amount of operating space, and accordingly the minimum area of contact of instruments with tissues. Angles of surgical action are important criteria for assessing the adequacy of surgical access and freedom of operation. Sufficient access width is determined by the classical angle of operational action (CAOOA), which is formed by lines connecting the outer edges of the operative section and a specific point of the object of operation. Adequate conditions for surgical intervention are provided by the value of $CAOOA \geq 25^\circ$ [13], (Fig. 1).

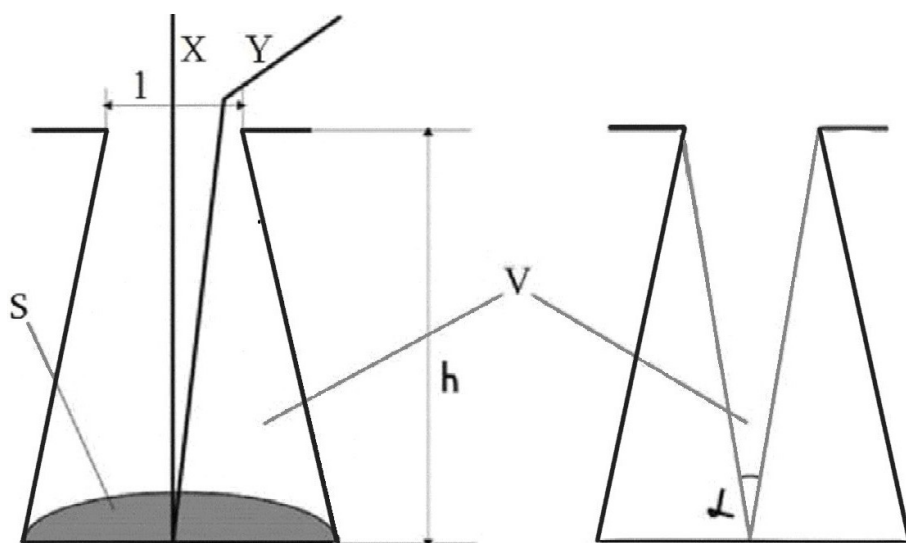


Fig. 1. Criteria for assessing the availability of minimally invasive procedures: 1 – the length of the wound; X – axis of observation; h – depth of the wound; S – accessibility area; V – volume and shape of the surgical wound; Y – the axis of operational action; α – the angle of operational action.

In determining the factors of the mathematical model for calculating the parameters of the surgical wound, radical removal of pigmented nevi took into account the fact that in most clinical cases the contour of the pathological formation approaches the oval, so the contour of the skin incision, taking into account the corresponding retreat from the tumor.

The area of the ellipse is equal to the product of the lengths of the major and minor half-axes by the π and is calculated by the formula

$$S = \pi \times a \times b \quad (1),$$

a – the length of the greater half-axis of the ellipse; b – the length of the smaller half-axis of the ellipse; π is equal to the value of 3.1415.

Based on this, the model for calculating the planar parameters of the surgical wound is based on the ratio of the size of the removed tissues in the form of ellipses at the level of the skin and at the level of the deep fascia, taking into account the thickness of the hypodermis. For a more simplified perception of the logic of the calculation, the shape of the operating space is proposed to be considered as a cone.

Geometrically, the computational model is in the form of a triangle, the vertex of which unfolds at an angle of 25° , and which is an inverted by 180° analogue of CAOAA (Fig. 2).

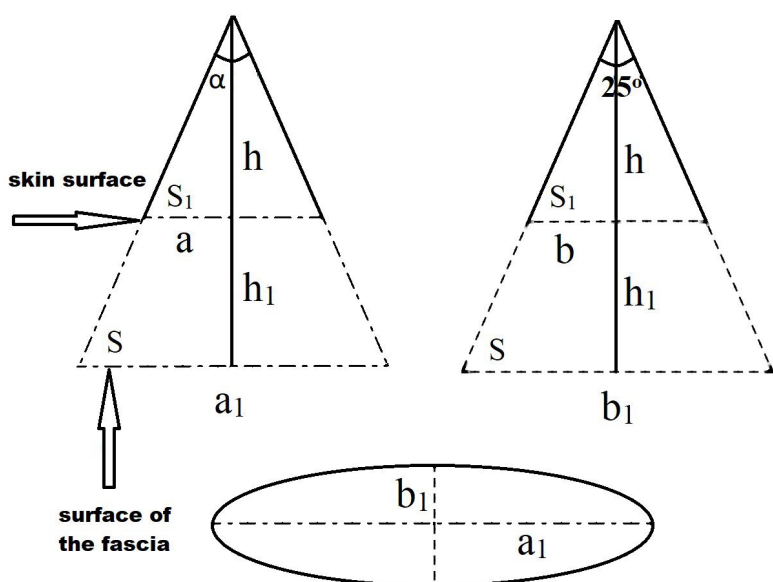


Fig. 2. Image of the calculation model for calculating the parameters of the surgical wound in two perpendicular directions, where: a – larger diameter of the ellipse at the level of the skin; b – the smaller diameter of the ellipse at the level of the skin; h_1 – depth of the wound; α – viewing angle (25° , this is the angle of the triangle, the base of which is a smaller diameter of the fascia; in a triangle with a larger base of the fascia, the angle will be greater than 25°); S_1 – area of the wound at the level of the skin; S is the area of the wound at the level of the fascia.

Taking into account the parameters of the factors of the surgical wound, we determine the larger diameter of the ellipse at the level of the fascia by the formula

$$a_1 = a \frac{h_1 + h}{h} - \text{greater length of the semi-axis of the ellipse at the level of the fascia; (2)}$$

the smaller diameter of the ellipse at the level of the fascia is determined by the formula

$$b_1 = b \frac{h_1 + h}{h} - \text{shorter half-length of the ellipse at the level of the fascia (3)}$$

The review height of the surgical wound was determined by the formula

$$h = \frac{b}{g \frac{\alpha}{2}}$$

(4) Adapting formulas (2) and (3) to formula (1) taking into account the indicator of the height of the review (formula 4) we obtain the calculated formula of the area (S) of the wound at the level of the fascia in the form of the following calculation

$$S = \pi \times \frac{a_1 \times b_1}{4},$$

(5) By entering individual linear indicators of a specific tumor into formula 5, which was integrated into a universal program for working with Microsoft Excel spreadsheets, we quickly and accurately obtain the necessary calculations during radical surgery to remove pigmented skin nevi due to their different localization.

The use of the proposed calculation model in the treatment of 120 patients with pigmented nevi for the period 2018 – 2020 allowed to avoid recurrence of the pathology in all cases.

Conclusions.

1. Increasing the radicalism of surgical operations during the removing pigmented tumors is not only a sufficient retreat from the visible boundaries of the tumor, but also an adequate amount of removed subcutaneous fat, blood vessels and fascia, which have their own anatomical and topographic features.

2. The proposed method of determining the radicalism of removal of pigmented skin nevi by mathematical calculation of the ratio of areas of removed tissues at the skin level and at the level of the aponeurosis taking into account the thickness of the hypodermis in different parts of the body allows to calculate individual surgical wound parameters.

The research was carried out in accordance with the principles of the Declaration of Helsinki. The study protocol was approved by the Local Ethics Committee of all institutions mentioned in the work. Informed consent of parents and children was obtained for the research. The authors declare no conflict of interest.

3. Due to the large number of pigmented nevi of different localization in childhood and a careful approach to determining the indications for surgical treatment in the last decade there has been an extensional annual increase in the number of operated children. Indications for surgical removal of pigmented nevi in childhood should be based on clear clinical dynamic signs, primarily taking into account the localization in functionally active areas. In order to prevent the persistent growth of pigmented nevi of any size, it is advisable to excise them within healthy skin in a circle to the fascial layer with simultaneous irradiation with a laser coagulator.

References:

1. Castagna R. D., Stramari J. M., Chemello R. M. L. The recurrent nevus phenomenon. *Anais Brasileiros de Dermatologia*. 2017. Vol. 92. No 4. P. 531–533.
2. Damsky W. E., Bosenberg M. Melanocytic nevi and melanoma: unraveling a complex relationship. *Oncogene*. 2017. Vol. 36. No 42. P. 5771–5792.
3. Fahradyan, A., Wolfswinkel, E. M., Tsuha, M., Reinisch, J. F., Magee III, W., Hammoudeh, J. A., Urata M. M., Howell L. K.. 2019. Cosmetically Challenging Congenital Melanocytic Nevi. *Annals of plastic surgery*. 2019. Vol. 82. No. 5S. P. S306–S309.

4. Gantsev Sh. Kh., Gantsev, Sh. Kh., Lipatov, O. N., Gantsev, K. Sh., Kzyrgalin, Sh. R., Tursumetov D. S.. Ploskokletochnyi rak kozhi: vozmozhnosti khirurgicheskogo lecheniia. Effektivnaia farmakoterapiia. 2017. No. 36. P. 50–53.
5. Gantsev Sh. Kh., Iusupov A. S. Ploskokletochnyi rak kozhi. Prakticheskaia onkologiya. 2012. Vol. 13. No. 2. P. 80–91.
6. Ghosh A. Ghosh, A., Ghartimagar, D., Thapa, S., Sathian, B., Shrestha, B., Talwar O. P. Benign melanocytic lesions with emphasis on melanocytic nevi – A histomorphological analysis. Journal of Pathology of Nepal. 2018. T. 8. No 2. C. 1384–1388.
7. Degtiarev, O. V., Dumchenko, V. V., Shashkova, A. A., Alieva, E. R., Khairulin, Iu. Kh. Vrozhdennye nevusy u detei. Rossiiskii zhurnal kozhnykh i venericheskikh boleznei. 2013. No. 4. P. 8–10.
8. Guégan, S., Kadlub, N., Picard, A., Rouillé, T., Charbel, C., Coulomb-L’Hermine, A. K., How-Kit A., Fraitag S, Aractingi S., Fontaine R. H. Varying proliferative and clonogenic potential in NRAS-mutated congenital melanocytic nevi according to size. Experimental Dermatology. 2016. T. 25. No 10. P. 789–796.
9. Jen M., Murphy M., Grant-Kels J. M. Childhood melanoma. Clinics in dermatology. 2009. T. 27. No. 6. P. 529–536.
10. Lamotkin I. A., Kapustina O. G., Korzhikov A. V. Melanotsitarnye opukholi v strukture obrashchenii k dermatologu polikliniki po povodu novoobrazovaniia kozhi. Voennomeditsinskii zhurnal. 2007; Vol. 71: P. 70–71.
11. King, R., Hayzen, B. A., Page, R. N., Googe, P. B., Zeagler, D., & Mihm, M. C. Recurrent nevus phenomenon: a clinicopathologic study of 357 cases and histologic comparison with melanoma with regression. Modern Pathology. 2009. T. 22. №. 5. P. 611–617.
12. Ponomarev I. V., Topchii, S. B., Pushkareva, A. E., Andrusenko, Iu. N., Shakina L. D. Lechenie vrozhdennykh melanotsitarnykh nevusov u detei. Vestnik Dermatologii i Venerologii. 2020. Vol. 96. No. 3. P. 43–52.
13. Regazzetti, C., De Donatis, G. M., Ghorbel, H. H., Cardot-Leccia, N., Ambrosetti, D., Bahadoran, P., Chignon-Sicard B., Lacour J. P., Ballotti R., Mahn A., Passeron T. Endothelial cells promote pigmentation through endothelin receptor B activation. Journal of Investigative Dermatology. 2015. Vol. 135. No 12. P. 3096–3104.
14. Sardana K., Chakravarty P., Goel K. Optimal management of common acquired melanocytic nevi (moles): current perspectives. Clinical, cosmetic and investigational dermatology. 2014. Vol. 7. P. 89–103.
15. Sommer L. L. Barcia, S. M., Clarke, L. E., Helm K. F. Persistent melanocytic nevi: a review and analysis of 205 cases. Journal of cutaneous pathology. 2011. Vol. 38. No. 6. P. 503–507.
16. Vissarionov V. A., Chervonnaia L. V., Ilina E. E. Prodolzhenyi rost nevusov” posle ikh udaleniia. Eksperimentalnaia i klinicheskaia dermatokosmetologiya. 2012. No. 4. P. 27–30.
17. Volgareva G. M., Lebedeva A. V. Melanotsitarnye novoobrazovaniia kozhi u detei/ Rossiiskii bioterapevticheskii zhurnal. 2016. Vol. 15. No. 2. P.82–89.
18. Urzhumova N. G., Makarchuk A. I., Makarchuk A. A. Sovremennye tendentsii v diagnostike patologii kozhi na etape planirovaniia lecheniia i monitoringe ego effektivnosti. Dermatovenerologiya. Kosmetologiya. Seksopatologiya. 2011. Vol. 1. P. 193–197.